

PATIENT

Ruby Whiteman

SPECIES

Canine

BREED

Labrador

SEX

Intact female

AGE

10 months

WEIGHT

43 lbs

PRESENTING CLINICAL SIGNS

History: Pregnancy vs pseudopregnancy

ULTRASONOGRAPHIC EXAMINATION OF THE ABDOMEN

The **urinary bladder**, trigone, and pelvic urethra presented normal thicknesses and normal tone. The ureters were not visible which is normal. No uroliths or sediment were visualized and anechoic urine was present. No evidence of inflammatory or neoplastic changes was noted. Ureteral papillae were normal.

The left ovary was uniform and measured 2.12 x 0.99 cm. The right ovary was uniform and measured 2.13 x 1.14 cm. The uterus was mildly thick and empty. The uterus measured approximately 0.9 cm. No evidence of viable pregnancy.

ULTRASONOGRAPHIC FINDINGS

Empty uterus.

Normal ovaries and reproductive structure.

INTERPRETATION OF THE FINDINGS & FURTHER RECOMMENDATIONS

There was no evidence of viable pregnancy.

INTERPRETED BY

Eric Lindquist, DMV,
DABVP, Cert. IVUSS

IMAGING PERFORMED BY

Jenna Walsh, CVT

HOSPITAL NAME

Hello Vet for Pets LLC

REFERRING VET

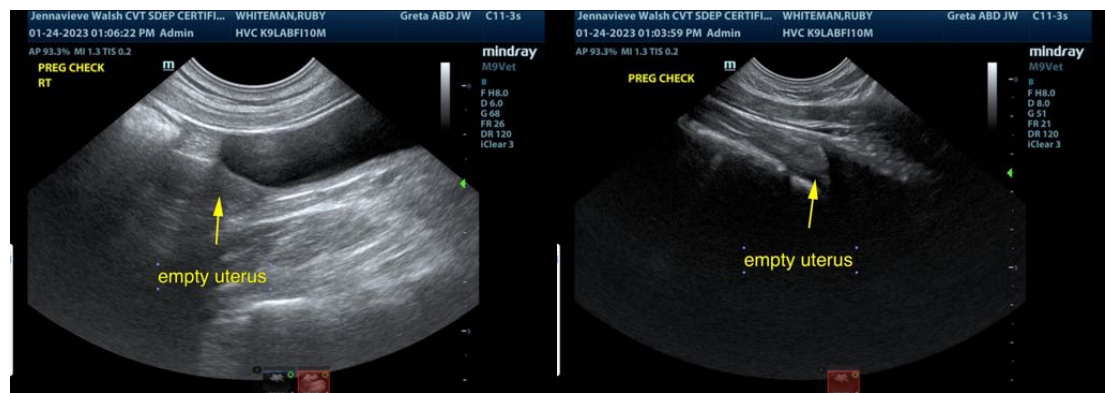
Dr. Kastella

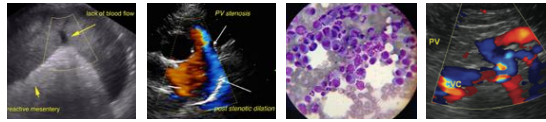
DATE

1/24/23

Invoice

42295





PATIENT

Ruby Whiteman

SPECIES

Canine

BREED

Labrador

SEX

Intact female

AGE

10 months

WEIGHT

43 lbs

INTERPRETED BY

Eric Lindquist, DMV,
DABVP, Cert. IVUSS

IMAGING PERFORMED BY

Jenna Walsh, CVT

HOSPITAL NAME

Hello Vet for Pets LLC

REFERRING VET

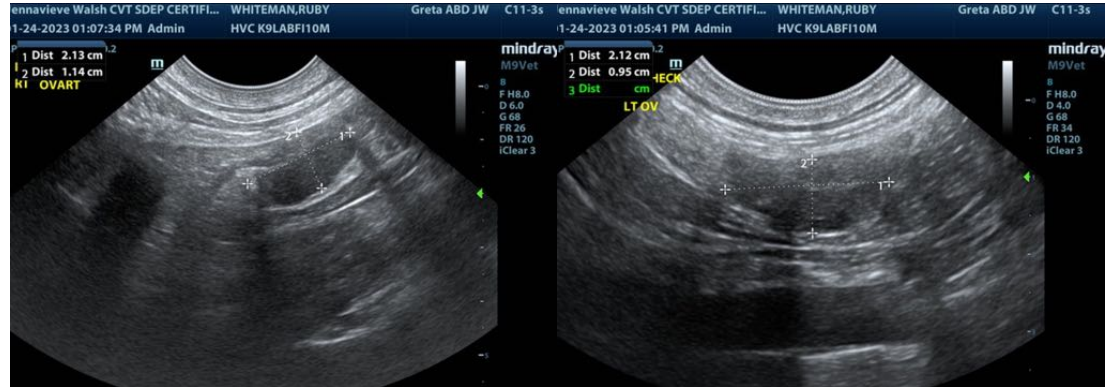
Dr. Kastella

DATE

1/24/23

Invoice

42295



The information and recommendations provided are based on the images presented by the referring veterinarian/sonographer. No evaluation can be communicated regarding pathology that was not visible in the image/video clips provided.

Thank you for this referral. If the clinical or image interpretation does not parallel your findings or if I can be of any further assistance please contact me.

Eric Lindquist, DMV, DABVP, Cert. IVUSS

CEO of Sonopath.com

Eric.Lindquist@SonoPath.com