



PATIENT

Dodge Wiebke

SPECIES

Feline

BREED

Domestic Shorthair

SEX

Neutered male

AGE

14 years

WEIGHT

13.54 lbs

INTERPRETED BY

Eric Lindquist, DMV,
DABVP, Cert. IVUSS

IMAGING PERFORMED BY

Jenna Walsh, CVT

HOSPITAL NAME

Cottage Grove VC

REFERRING VET

Dr. Damewood

PRESENTING CLINICAL SIGNS

Tachycardia, significant weight loss. Blood pressure measurements- 145/98/114, 153/102/119, 147/109/122, 143/114/124
Abnormal PE/Chem/CBC/UA Results: Renal disease IRIS stage 2. Normal CBC and T4.

ULTRASONOGRAPHIC EXAMINATION OF THE HEART

The echocardiogram in this patient demonstrated normal **left atrial** size based on 3 separate LA measurements. The cranial and caudal **mitral** valve leaflets presented normal linear structure and kinetics. The **left ventricle** appeared slightly volume contracted with minor increased hypertrophy of the septum and free wall. Minor **myocardial** remodeling was noted. **Contractility** of the ventricular walls was adequate and in normal range for this patient evidenced by the fractional shortening measurement and subjective evaluation of the different regions and angles of the myocardium. The **left ventricular outflow** tract demonstrated normal laminar flow and subjective structural integrity. The **right atrium** and auricle revealed normal size, structure and content. No evidence of masses was noted or chamber overload. Minor **tricuspid** insufficiency was noted at 2.2 m/sec. The **right ventricle** was of normal size (1/3 diameter of LV), chordae structure, myocardial echogenicity and thickness. **Pulmonic** tract assessment revealed normal valve structure, laminar flow, and diameter (approx.1:1 pa/ao ratio). No visible **pericardial** or free pleura fluid was noted or extra cardiac pathology in the visible planes. The cranial **mediastinum and pericardial regions** were free of masses in the visible window.

FELINE CARDIAC PARAMETERS	BODY WEIGHT lbs	HR (BPM)	IVSd (cm)	LVIDd (cm)	LVWd (cm)	FS (%)	EF (%)
NORMAL PARAMETER	-----	150-240	0.3-0.6	1.0-2.1	0.25-0.6	35-67	80-100
PATIENT	13.54	232	0.71	0.98	0.71	50	
FELINE CARDIAC PARAMETERS	LA/AO (Boon)	LA/AO HEART BASE (Sisson)	LA 2D 4-chamber long axis AS to FW (Sisson) (cm)	LVOT VEL. (m/s)	RVOT VEL. (m/s)	IVRT (m/)	
NORMAL PARAMETER	<1.5	0.88-1.79	0.7-1.7	<1.6	<1.3	40-60	
PATIENT		1.2		1.1	0.81	NM	
Adapted from June Boon, Veterinary Echocardiography, 1998 Sisson D et al. JVIM 1991; 5: 232, Jacobs et al. Am J Vet Res 1985; 46:1705							

DATE

1/19/22

Invoice
95404



PATIENT

Dodge Wiebke

SPECIES

Feline

BREED

Domestic Shorthair

SEX

Neutered male

AGE

14 years

WEIGHT

13.54 lbs

INTERPRETED BY

Eric Lindquist, DMV,
DABVP, Cert. IVUSS

IMAGING PERFORMED BY

Jenna Walsh, CVT

HOSPITAL NAME

Cottage Grove VC

REFERRING VET

Dr. Damewood

DATE

1/19/22

Invoice
95404

ULTRASONOGRAPHIC FINDINGS

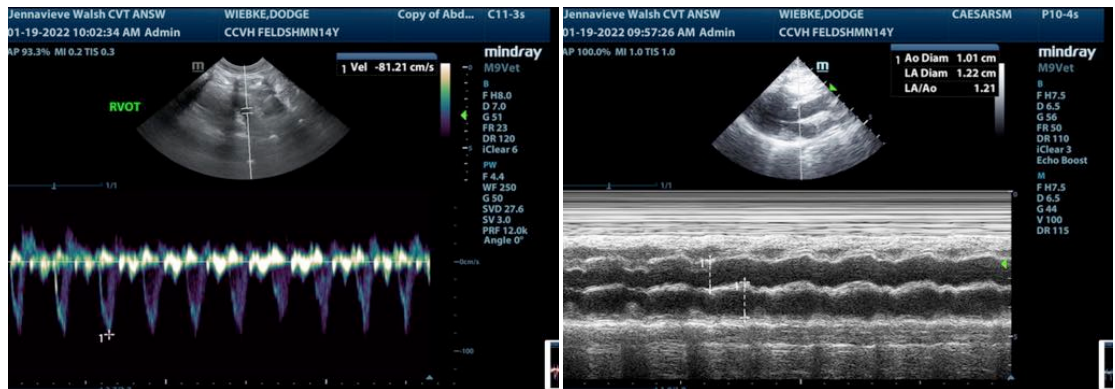
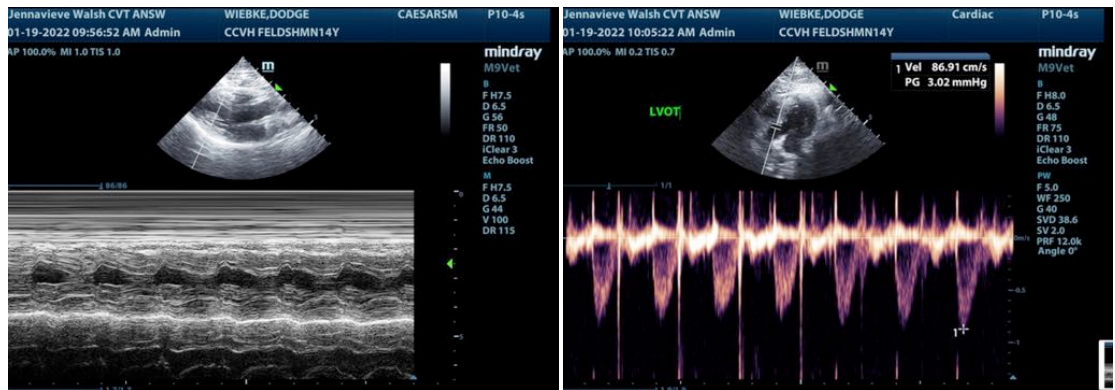
Normal echocardiogram with minor pseudo hypertrophy of the left ventricle.

No evidence of cardiac disease.

Minor tricuspid insufficiency, not clinically significant.

INTERPRETATION OF THE FINDINGS & FURTHER RECOMMENDATIONS

The left ventricular presentation may be pseudo hypertrophy owing to volume contraction. Systemic hydration should be evaluated if not already performed.





PATIENT

Dodge Wiebke

SPECIES

Feline

BREED

Domestic Shorthair

SEX

Neutered male

AGE

14 years

WEIGHT

13.54 lbs

INTERPRETED BY

Eric Lindquist, DMV,
DABVP, Cert. IVUSS

IMAGING PERFORMED BY

Jenna Walsh, CVT

HOSPITAL NAME

Cottage Grove VC

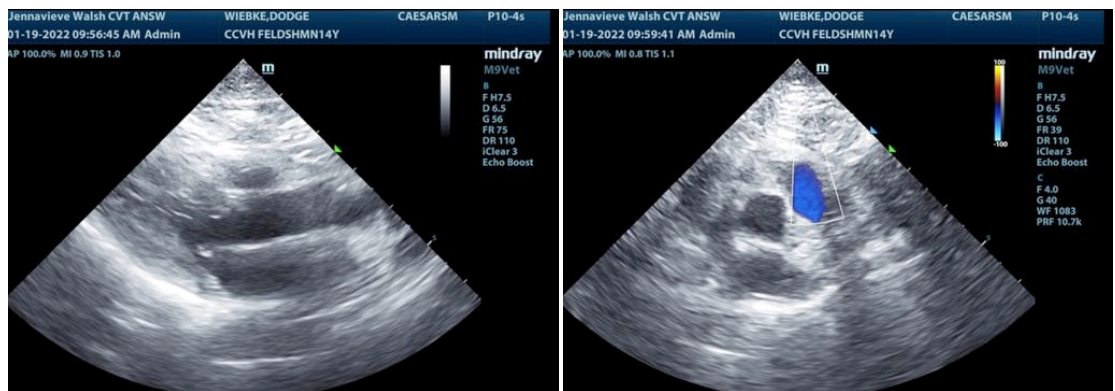
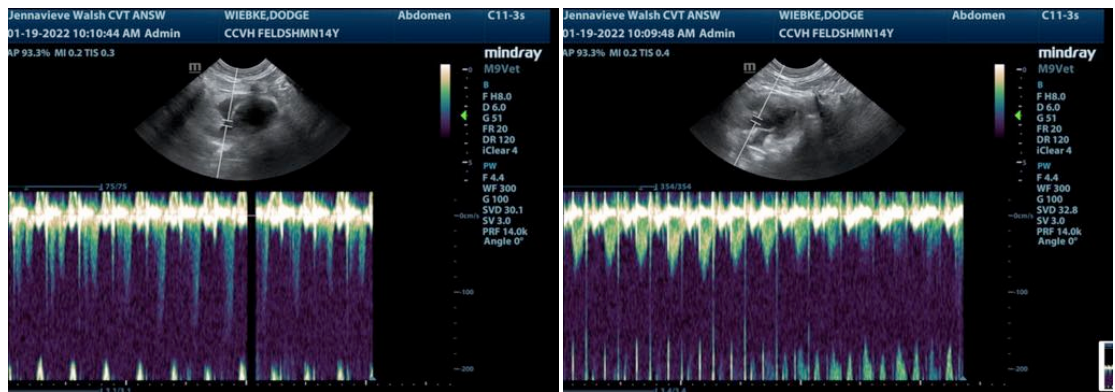
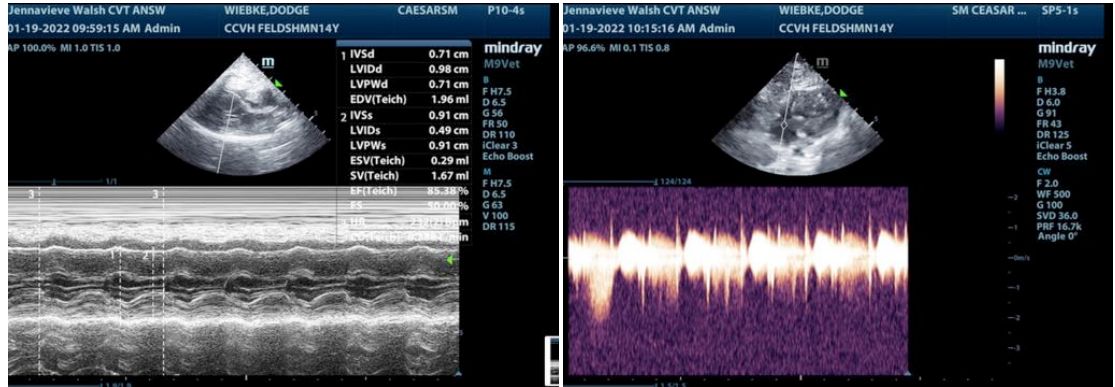
REFERRING VET

Dr. Damewood

DATE

1/19/22

Invoice
95404



The information and recommendations provided are based on the images presented by the referring veterinarian. No evaluation can be communicated regarding pathology that was not visible in the image/video clips provided.

Thank you for this referral. If the clinical or image interpretation does not parallel your findings or if I can be of any further assistance please contact me.

Eric Lindquist, DMV, DABVP, Cert. IVUSS



PATIENT

CEO of Sonopath.com

Dodge Wiebke

Eric.Lindquist@SonoPath.com

SPECIES

Feline

BREED

Domestic Shorthair

SEX

Neutered male

AGE

14 years

WEIGHT

13.54 lbs

INTERPRETED BY

Eric Lindquist, DMV,
DABVP, Cert. IVUSS

**IMAGING
PERFORMED BY**

Jenna Walsh, CVT

HOSPITAL NAME

Cottage Grove VC

REFERRING VET

Dr. Damewood

DATE

1/19/22

Invoice
95404