

PATIENT

Gabbery Overmeyer

PRESENTING CLINICAL SIGNS

Occasional vomiting.

SPECIES

Feline

ULTRASONOGRAPHIC EXAMINATION OF THE ABDOMEN

Urinary System

The **urinary bladder**, trigone, and pelvic urethra presented normal thicknesses and normal tone. The ureters were not visible which is normal. No uroliths or sediment were visualized and anechoic urine was present. No evidence of inflammatory or neoplastic changes was noted. Ureteral papillae were normal.

BREED

Domestic Medium Hair

SEX

Neutered male

The **kidneys** presented a relatively uniform cortical hyperechogenicity when compared to the renal medulla, spleen and liver. No overt masses were noted. Corticomedullary definition was nebulous and the ratio favored the cortex slightly. The ureters were not visible and assumed to be normal. These changes are most consistent with chronic interstitial nephritis yet infiltrative disease could not be entirely ruled out without biopsy though neoplasia is not suspected. The left kidney measured 3.8 cm. The right kidney measured 3.48 cm.

AGE

7/1/08

WEIGHT

7.8 lbs

Adrenal Glands

Both **adrenal glands** were visualized and recognized as having normal shape, size, position and echogenicity for this breed. The phrenic vasculature, glandular echogenicity and detail were unremarkable. Capsule, cortex, and medullary definition were normal for this age patient. The right adrenal gland measured 0.58 cm. The left adrenal gland measured 0.31 cm.

INTERPRETED BY

Eric Lindquist, DMV,
DABVP, Cert. IVUSS

Spleen

The **spleen** presented a smooth homogeneous parenchyma hyperechoic to liver and renal cortical parenchyma. The capsule was smooth without noticeable expansion or deviation from within the spleen or adjacent pathology. The splenic vasculature demonstrated normal volume without signs of congestion or thrombosis. No sonographic evidence of acute or chronic inflammatory, neoplastic, or infarctual changes was noted.

IMAGING PERFORMED BY

Sara Hansen

HOSPITAL NAME

Reid VH

Liver

The **liver** images submitted revealed subjectively normal liver size, contour, and structure. Parenchymal echogenicity was naturally coarse and hypoechoic to the spleen. Vascular and biliary tracts were of normal volume with no evidence of congestion. The gallbladder presented acceptably thin walls with primarily anechoic content. The cystic and common bile ducts were normal. No pathological hepatic lymphadenopathy was evident. No overt structural evidence of inflammatory, infiltrative or regenerative pathology was evident.

REFERRING VET

Dr. Heider

DATE

1/18/23

Invoice

42229



PATIENT

Gabbery Overmeyer

SPECIES

Feline

BREED

Domestic Medium Hair

SEX

Neutered male

AGE

7/1/08

WEIGHT

7.8 lbs

INTERPRETED BY

Eric Lindquist, DMV,
DABVP, Cert. IVUSS

IMAGING PERFORMED BY

Sara Hansen

HOSPITAL NAME

Reid VH

REFERRING VET

Dr. Heider

DATE

1/18/23

Invoice

42229

Gastrointestinal

The **stomach** was filled with progressively shadowing ingesta, possible hair accumulation. The small intestine and colon were unremarkable. The mesenteric lymph nodes were reactive and measured up to 1.5 x 0.5 cm.

Pancreas

The **pancreas** was enlarged and irregular with a 1.5 cm cyst. Enhanced surrounding mesentery was noted. This is suggestive for history of inflammation around the pancreas.

ULTRASONOGRAPHIC FINDINGS

Chronic pancreatitis and concurrent cyst.

Diffuse intestinal thickening with reactive mesenteric lymphadenopathy.

Chronic interstitial nephrosis pattern.

INTERPRETATION OF THE FINDINGS & FURTHER RECOMMENDATIONS

There was no overt evidence of neoplasia; however, this cannot be completely ruled out without lymph node, intestinal and pancreatic biopsies. Surgical approach with full thickness intestinal lymph node and pancreatic biopsies with pancreatic cyst drainage can be considered. Otherwise, supportive care for pancreatitis and inflammatory bowel can be considered such as the following from an empirical perspective.

Part or all of this protocol may be considered based on your clinical impression of the patient:

Recommend pain management when anorexic with **Buprenorphine** (0.01-0.02 mg/kg IM or SC), clinical trial of **Zithromax** (50 mg sid/cat x 10 days, 3 weeks if bartonella +), **Prednisolone** (0.5-2 mg/kg tapering over 1 week to minimal effective dose), and **B12 injections** if weight loss (Cyanobalamine 250 mcg sub-q once-weekly x six weeks, then every other week for six weeks and then once-monthly, long-term if necessary), **novel-protein or hydrolyzed diet** (*Hydrolyzed diets have been shown to be more effective in dietary intolerance case management compared to hypoallergenic diets*) or the **magical Purina DM** (changing protein source is crucial and may need rotation every 6 months if clinical signs recur) Diet trials is a whatever works phenomenon. If vomiting becomes a persistent issue then endoscopy would be warranted and/or recheck sonogram to assess more emerging disease. One diet does not work for all patients so different trials may be necessary or protein source rotation every 6 months as new sensitivities develop.

Maldigestion panel, three view chest radiographs and full CNS examination is recommended to examine for occult disease that could be responsible for the weight loss. Evaluation for competitive eating environments should also be considered.



PATIENT

Gabbery Overmeyer

SPECIES

Feline

BREED

Domestic Medium Hair

SEX

Neutered male

AGE

7/1/08

WEIGHT

7.8 lbs

INTERPRETED BY

Eric Lindquist, DMV,
DABVP, Cert. IVUSS

IMAGING PERFORMED BY

Sara Hansen

HOSPITAL NAME

Reid VH

REFERRING VET

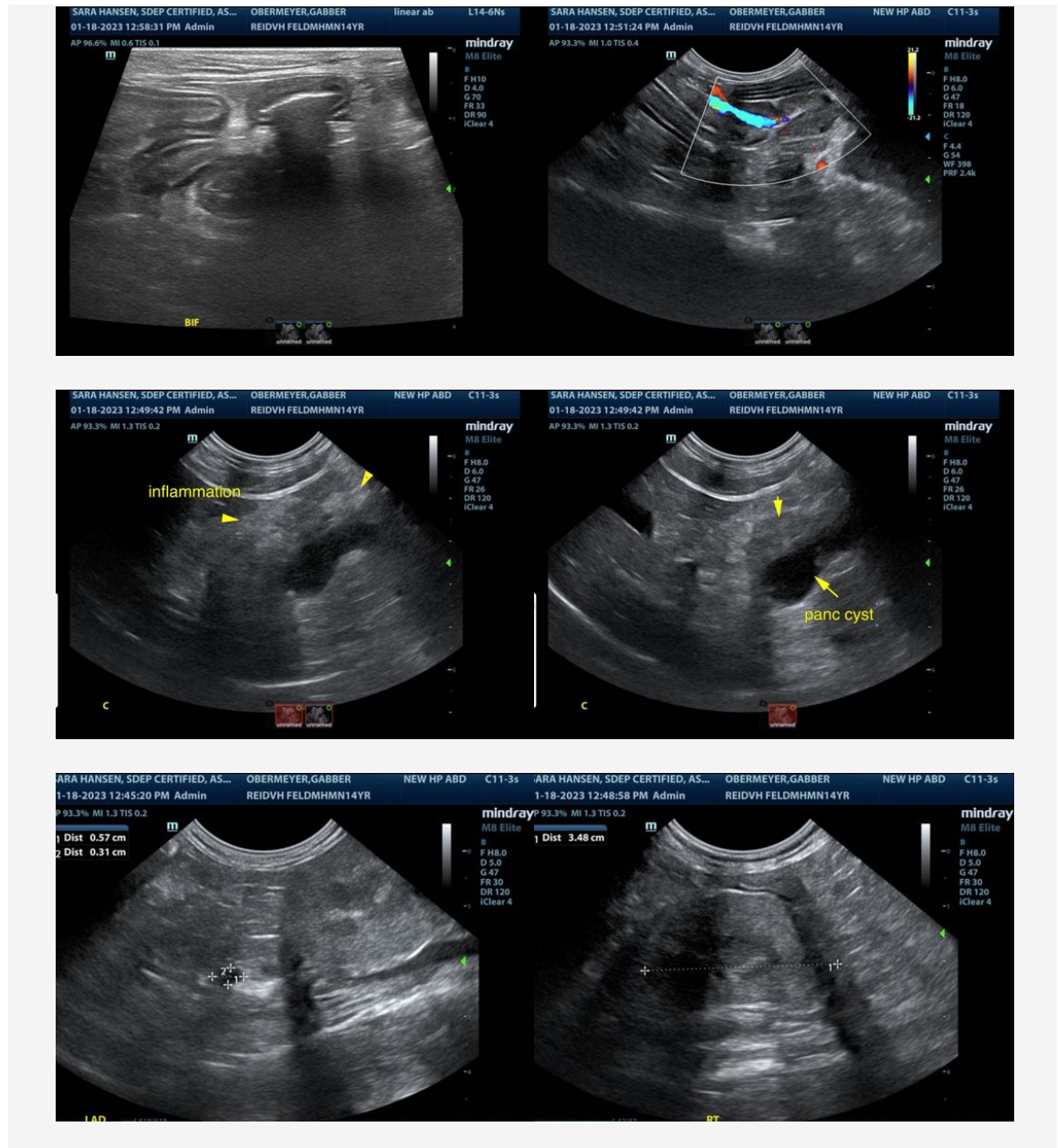
Dr. Heider

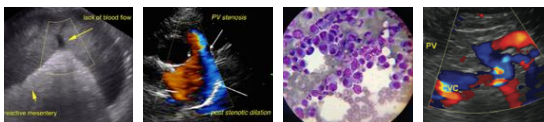
DATE

1/18/23

Invoice

42229





PATIENT

Gabbery Overmeyer

SPECIES

Feline

BREED

Domestic Medium Hair

SEX

Neutered male

AGE

7/1/08

WEIGHT

7.8 lbs

INTERPRETED BY

Eric Lindquist, DMV,
DABVP, Cert. IVUSS

IMAGING PERFORMED BY

Sara Hansen

HOSPITAL NAME

Reid VH

REFERRING VET

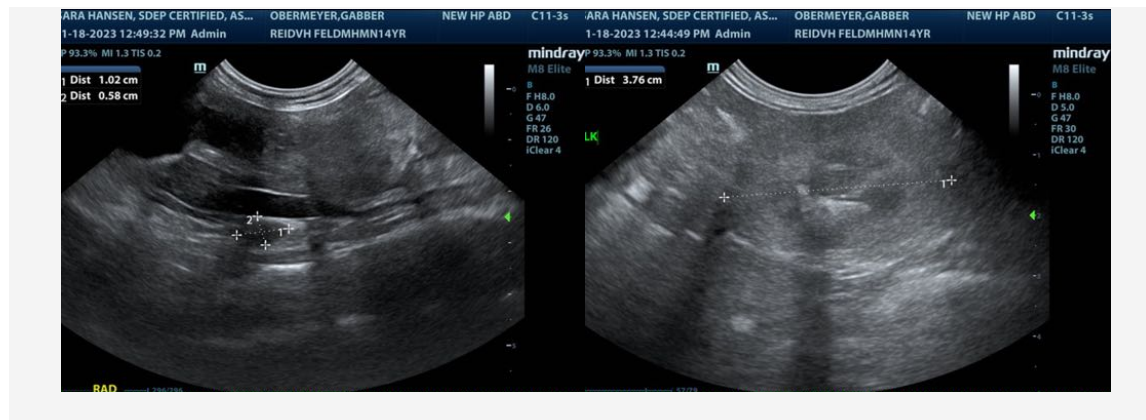
Dr. Heider

DATE

1/18/23

Invoice

42229



The information and recommendations provided are based on the images presented by the referring veterinarian/sonographer. No evaluation can be communicated regarding pathology that was not visible in the image/video clips provided.

Thank you for this referral. If the clinical or image interpretation does not parallel your findings or if I can be of any further assistance please contact me.

Eric Lindquist, DMV, DABVP, Cert. IVUSS

CEO of Sonopath.com

Eric.Lindquist@SonoPath.com