



PATIENT

Tuna Hansen

SPECIES

Avian

BREED

American Buff Goose

SEX

Intact male

AGE

20 months

WEIGHT

6.81 kg

INTERPRETED BY

Eric Lindquist, DMV,
DABVP, Cert. IVUSS

IMAGING PERFORMED BY

Jenna Walsh, CVT

HOSPITAL NAME

West Hills AH

REFERRING VET

Dr. Vickstrom

DATE

1/12/23

Invoice

42081

.PRESENTING CLINICAL SIGNS

History: anorexia, depressed attitude both geese Current Medications TMPS and Sucralfate Primary Question/Differential to Be Answered in This Exam enteritis, reproductive, character of liver.

ULTRASONOGRAPHIC EXAMINATION OF THE ABDOMEN

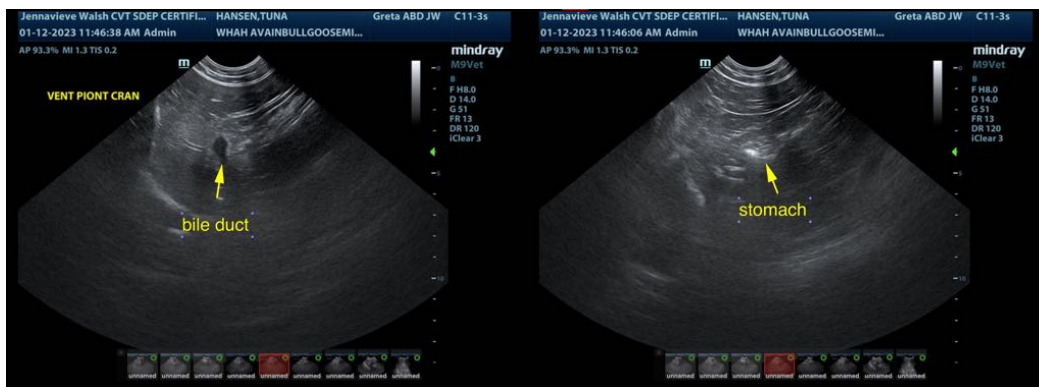
The abdominal organs in this patient were unremarkable. The liver revealed uniform parenchyma isoechoic to regional fat. The biliary duct was normal at 0.2 cm. The pancreas was uniform with curvilinear patterns and no evidence of pathology. The gizzard revealed normal, echogenic contents. The stomach was empty at the time of the sonogram. The regions of the kidneys were imaged with no evidence of pathology. The small intestine and cloaca appeared normal. The abdomen revealed a large amount of abdominal fat with no evidence of pathology.

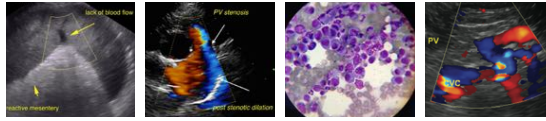
ULTRASONOGRAPHIC FINDINGS

Essentially normal abdomen.

INTERPRETATION OF THE FINDINGS & FURTHER RECOMMENDATIONS

There was no evidence of pathology. Consideration for clinical signs caused by other organ systems such as respiratory or systemic infection is recommended, yet there was no evidence of visceral disease noted. The patient appears to have an adequate amount of abdominal fat that would suggest a decent body score.





PATIENT

Tuna Hansen

SPECIES

Avian

BREED

American Buff Goose

SEX

Intact male

AGE

20 months

WEIGHT

6.81 kg

INTERPRETED BY

Eric Lindquist, DMV,
DABVP, Cert. IVUSS

IMAGING PERFORMED BY

Jenna Walsh, CVT

HOSPITAL NAME

West Hills AH

REFERRING VET

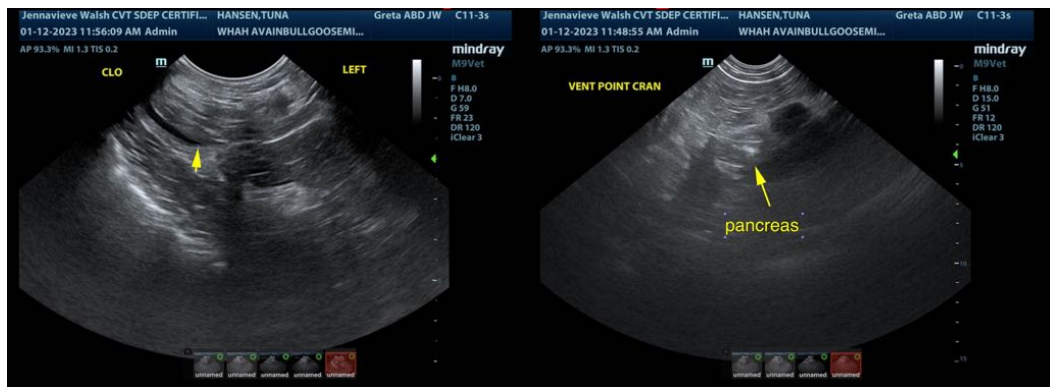
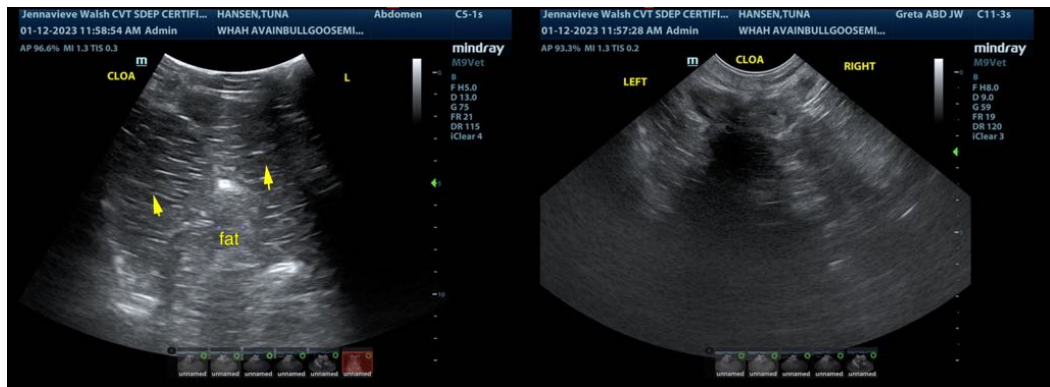
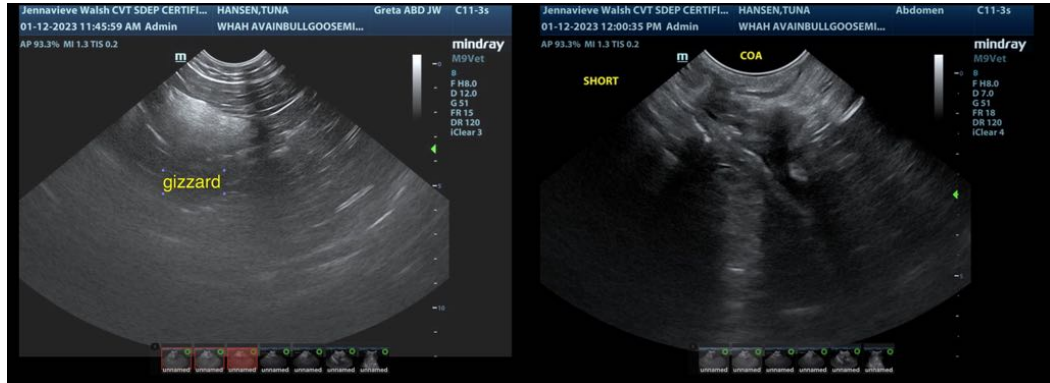
Dr. Vickstrom

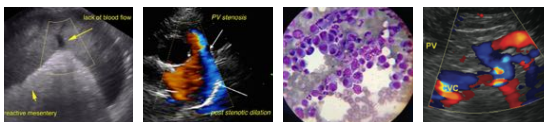
DATE

1/12/23

Invoice

42081





PATIENT

Tuna Hansen

SPECIES

Avian

BREED

American Buff Goose

SEX

Intact male

AGE

20 months

WEIGHT

6.81 kg

INTERPRETED BY

Eric Lindquist, DMV,
DABVP, Cert. IVUSS

IMAGING PERFORMED BY

Jenna Walsh, CVT

HOSPITAL NAME

West Hills AH

REFERRING VET

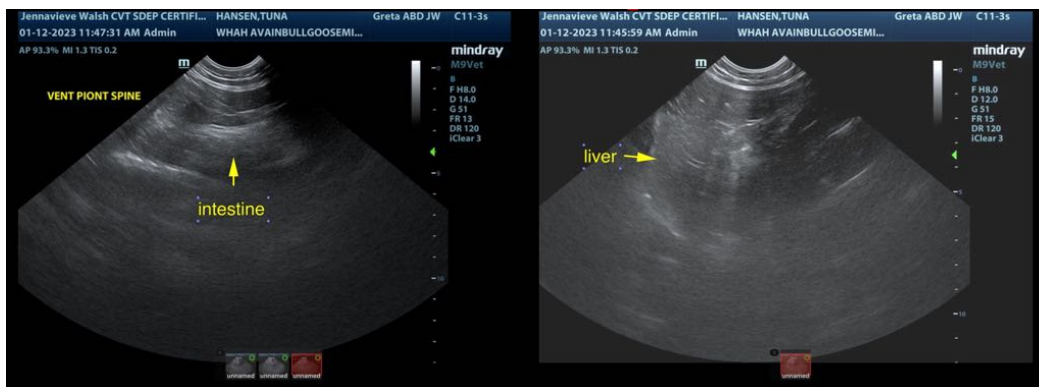Dr. Vickstrom

DATE

1/12/23

Invoice

42081



The information and recommendations provided are based on the images presented by the referring veterinarian/sonographer. No evaluation can be communicated regarding pathology that was not visible in the image/video clips provided.

Thank you for this referral. If the clinical or image interpretation does not parallel your findings or if I can be of any further assistance please contact me.

Eric Lindquist, DMV, DABVP, Cert. IVUSS

CEO of SonoPath.com

Eric.Lindquist@SonoPath.com