



**PATIENT**

Button Nesberg

**PRESENTING CLINICAL SIGNS**

Pregnancy Check

**SPECIES**

Canine

**ULTRASONOGRAPHIC EXAMINATION OF THE ABDOMEN**

Positive pregnancy was noted in this patient. The fetal length was approximately 2.2 cm. The fetal sac measured 4.0 cm. Viable heartbeats and fetal movements were normal. Amniotic fluid was anechoic. There were three separate live fetuses were noted.

**BREED**

Jack Russell Terrier

**ULTRASONOGRAPHIC FINDINGS**

**SEX**

Intact Female

Viable pregnancy.  
3 viable fetuses.

**AGE**

4 years

**INTERPRETATION OF THE FINDINGS & FURTHER RECOMMENDATIONS**

There was no evidence of pathology. The patient is approximately 30 days of gestation +/- 5 days.

**WEIGHT**

14.9 lbs

**INTERPRETED BY**

Eric Lindquist, DMV,  
DABVP, Cert. IVUSS

**IMAGING PERFORMED BY**

Jenna Walsh, CVT

**HOSPITAL NAME**

Pawsitive Wellness VC

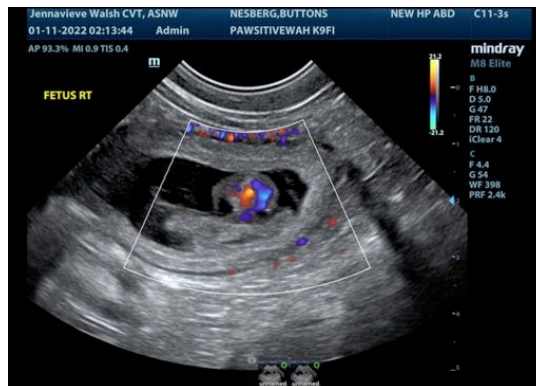
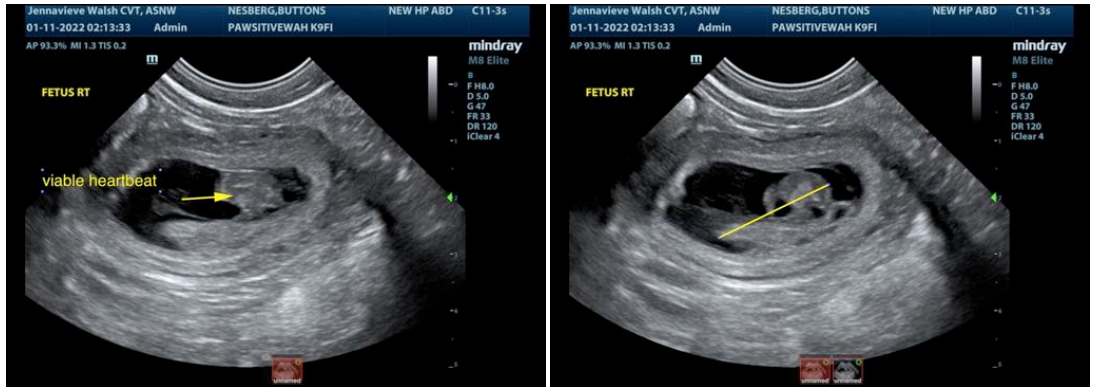
**REFERRING VET**

Dr. Hardy

**DATE**

1/10/22

**Invoice**  
95069





**PATIENT**

Button Nesberg

The information and recommendations provided are based on the images presented by the referring veterinarian. No evaluation can be communicated regarding pathology that was not visible in the image/video clips provided.

**SPECIES**

Canine

Thank you for this referral. If the clinical or image interpretation does not parallel your findings or if I can be of any further assistance please contact me.

**BREED**

Jack Russell Terrier

**Eric Lindquist**, DMV, DABVP, Cert. IVUSS

CEO of Sonopath.com

Eric.Lindquist@SonoPath.com

**SEX**

Intact Female

**AGE**

4 years

**WEIGHT**

14.9 lbs

**INTERPRETED BY**

**Eric Lindquist**, DMV,  
DABVP, Cert. IVUSS

**IMAGING PERFORMED BY**

Jenna Walsh, CVT

**HOSPITAL NAME**

Pawsitive Wellness VC

**REFERRING VET**

Dr. Hardy

**DATE**

1/10/22

**Invoice**  
95069