



PATIENT

Sunny Jeski

SPECIES

Canine

BREED

Fox Terrier Mix

SEX

Neutered male

AGE

18 years

WEIGHT

13.9 lbs

INTERPRETED BY

Eric Lindquist, DMV
DABVP, Cert. IVUSS

IMAGING PERFORMED BY

Marco Lichfield

HOSPITAL NAME

Sova AH

REFERRING VET

Dr. Sova

INVOICE

32784

DATE

9/8/22

PRESENTING CLINICAL SIGNS

History: P has a history of a bladder tumor, Holding urine for 4 hours and urinates fine, end of urination P tries again and urinates a blood clot stating the owner.

Abnormal PE/Chem/CBC/UA Results: U/A results from 09/07/2022 blood 3+, RBC 21-50, protein 2+, protein/creatinine ratio 2.0

ULTRASONOGRAPHIC EXAMINATION OF THE ABDOMEN

Urinary System

The **urinary bladder** revealed a large, mineralizing mass with concurrent thickened urethra. The mass encompassed the majority of the bladder to the level of the cystourethral junction and impinged upon the ureteral papillae.

The **right kidney** revealed moderate dystrophic changes and measured 2.93 cm with pyelectasia and corticomedullary mineralization and moderately increased cortical echogenicity. The left kidney presented degenerative cortical cystic changes. The left kidney also measured 2.93 cm.

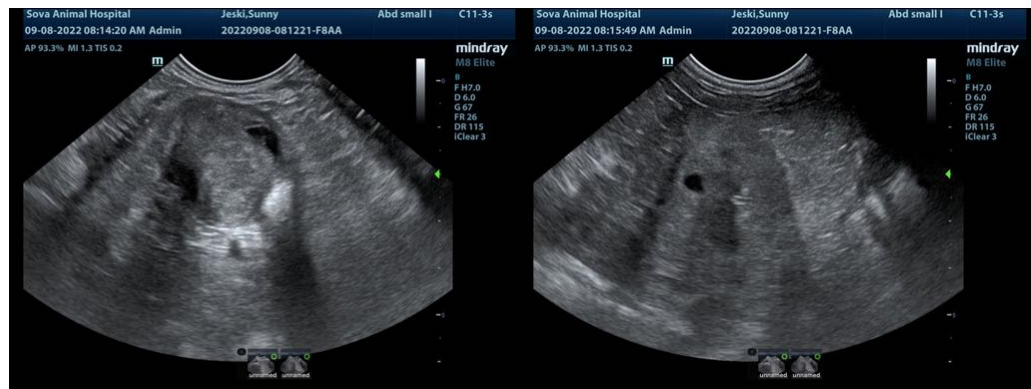ULTRASONOGRAPHIC FINDINGS

Mineralizing bladder mass with possible urethra involvement.

Moderate degenerative renal changes.

INTERPRETATION OF THE FINDINGS & FURTHER RECOMMENDATIONS

I am concerned for early ureteral obstruction. Chemotherapeutic intervention is recommended. The mass does not appear resectable. Traumatic catheterization can be considered with ultrasound guidance to confirm suspicion of transitional cell carcinoma.





PATIENT

Sunny Jeski

SPECIES

Canine

BREED

Fox Terrier Mix

SEX

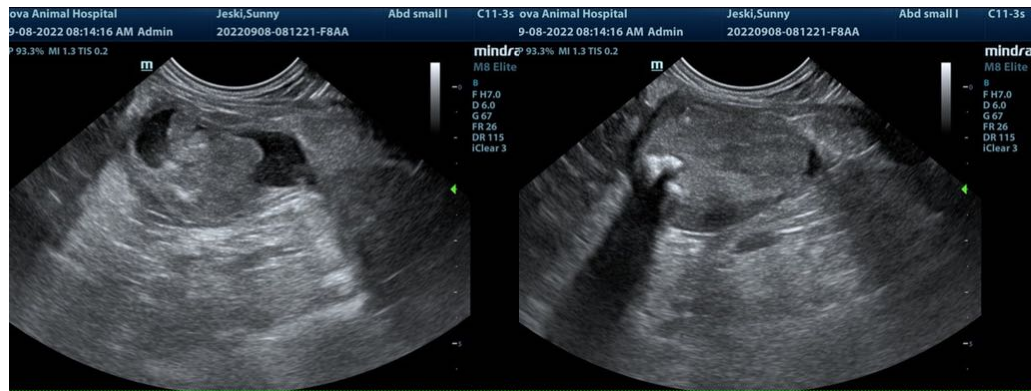
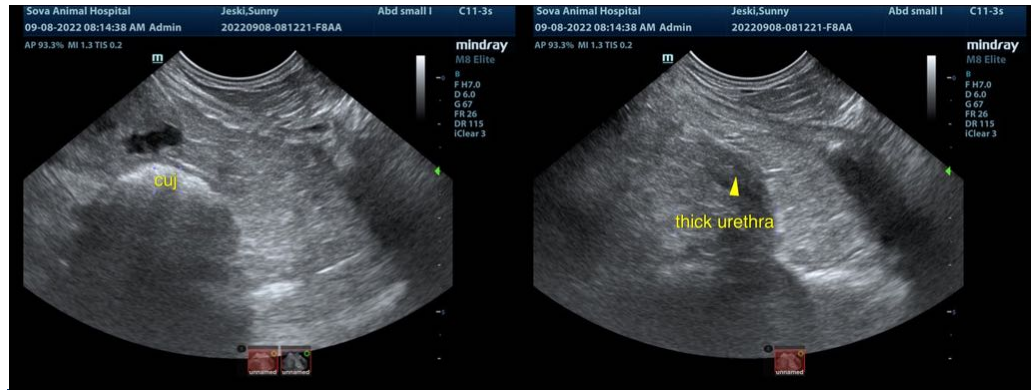
Neutered male

AGE

18 years

WEIGHT

13.9 lbs



INTERPRETED BY

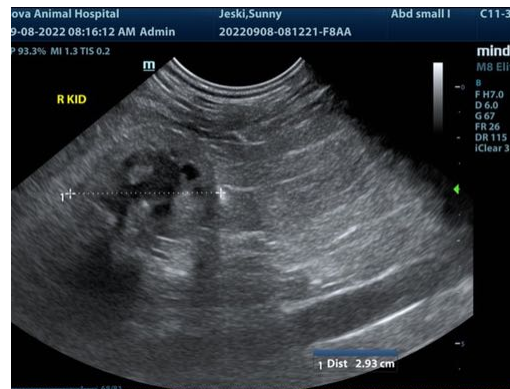Eric Lindquist, DMV
DABVP, Cert. IVUSS

IMAGING PERFORMED BY

Marco Lichfield

HOSPITAL NAME

Sova AH



REFERRING VET

Dr. Sova

INVOICE

32784

DATE

9/8/22

The information and recommendations provided are based on the images presented by the referring veterinarian/sonographer. No evaluation can be communicated regarding pathology that was not visible in the image/video clips provided.

Thank you for this referral. If the clinical or image interpretation does not parallel your findings or if I can be of any further assistance please contact me.

Eric Lindquist, DMV, DABVP, Cert. IVUSS, CEO of SonoPath.com
info@SonoPath.com