



PATIENT

Lilly Furry Friends Network

SPECIES

Canine

BREED

Hound Mix

SEX

Spayed female

AGE

6 years

WEIGHT

59 lbs

INTERPRETED BY

Eric Lindquist, DMV
DABVP, Cert. IVUSS

IMAGING PERFORMED BY

Dr. Todd

HOSPITAL NAME

Lambs Gap AH

REFERRING VET

Dr. Todd

INVOICE

32825

DATE

9/8/22

PRESENTING CLINICAL SIGNS

History: Lilly is a six year old, FS, Hound mix who was rescued by Furry Friends Network from a shelter in WV. She was presented to us on 8/18/22 by her foster. On exam, Lilly received her DAP, leptospirosis and Lyme vaccinations and wellness bloodwork was submitted. Mild non-regenerative anemia, hypoalbuminemia (1.5), hyperglobulinemia(10.0), increased ALT/AST, Lyme positive (quant C6=287), Ehrlichia positive, Anaplasma positive. UPC=2.0 Lab results attached as pdf for your interest

ULTRASONOGRAPHIC EXAMINATION OF THE ABDOMEN

Urinary System

The **urinary bladder** was mildly thickened with anechoic urine and no loss of mural detail.

The **kidneys** revealed normal size and structure, corticomedullary definition and ratio for this age. The cortices presented largely uniform texture with normal echogenic relationship to liver and spleen. Medullary structure differed distinctly from the cortex and no evidence of pelvic dilation was present. The capsules were acceptably uniform without significant irregularities. The left kidney measured 7.0 cm.

Adrenal Glands

The region of the left adrenal gland was imaged with no evidence of pathology. The right adrenal gland was subjectively flattened.

Spleen

The **spleen** was enlarged and folded upon itself cranially. Subtle micronodular changes were noted. Splenic lymph node was enlarged. Enhanced mesentery was noted around the spleen.

Liver

The **liver** images submitted revealed subjectively normal liver size, contour, and structure. Parenchymal echogenicity was naturally coarse and hypoechoic to the spleen. Vascular and biliary tracts were of normal volume with no evidence of congestion. The gallbladder presented acceptably thin walls with primarily anechoic content. The cystic and common bile ducts were normal. No pathological hepatic lymphadenopathy was evident. No overt structural evidence of inflammatory, infiltrative or regenerative pathology was evident.

Gastrointestinal

Examination of the **gastrointestinal tract** revealed a stomach and intestine free of stasis, of normal wall thickness, acceptable curvilinear mural detail, and peristaltic activity. Small and large intestine demonstrated normal luminal chyme and stool consistency respectively. No obstructive or overt infiltrative disease was noted.



PATIENT

Pancreas

Lilly Furry Friends Network

The base and limbs of the **pancreas** were observed to be largely isoechoic to surrounding omental fat. Pancreatic duct and capsular contour were acceptably normal and parenchyma respected normal curvilinear patterns. No overt evidence of active inflammatory or neoplastic disease was noted.

SPECIES

Canine

Free Abdomen

BREED

Hound Mix

The iliac lymph nodes were enlarged and measured up to 3.0 x 2.0 cm. The mesenteric lymph nodes were also enlarged.

SEX

Spayed female

ULTRASONOGRAPHIC FINDINGS

Enlarged spleen.

Slight iliac lymphadenopathy.

AGE

6 years

Enlarged mesenteric lymph nodes.

INTERPRETATION OF THE FINDINGS & FURTHER RECOMMENDATIONS

Given the patient's history, splenic and lymph node presentation I recommend splenic, liver and accessible lymph node FNA to assess for multiple myeloma. Urinalysis to assess Bence Jones proteins is recommended. Chronic infectious agents may be playing a primary role. Doxycycline, Clindamycin trial can also be considered.

WEIGHT

59 lbs

INTERPRETED BY

Eric Lindquist, DMV DABVP, Cert. IVUSS

IMAGING PERFORMED BY

Dr. Todd

HOSPITAL NAME

Lambs Gap AH

REFERRING VET

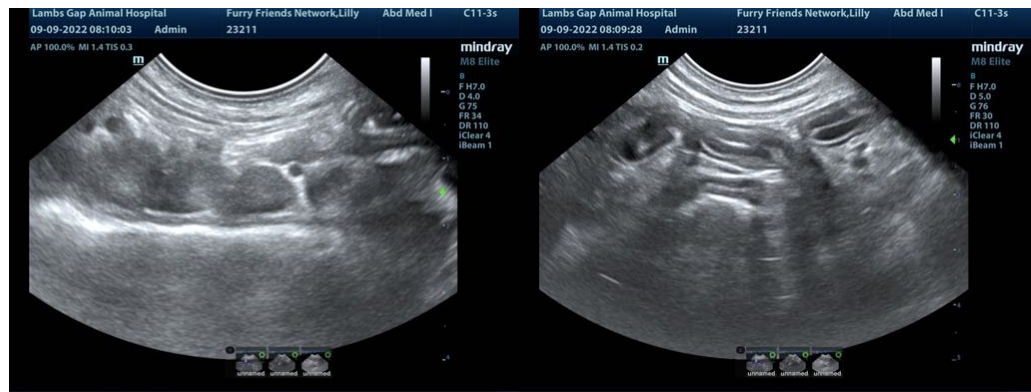
Dr. Todd

INVOICE

32825

DATE

9/8/22





PATIENT

Lilly Furry Friends Network

SPECIES

Canine

BREED

Hound Mix

SEX

Spayed female

AGE

6 years

WEIGHT

59 lbs

INTERPRETED BY

Eric Lindquist, DMV DABVP, Cert. IVUSS

IMAGING PERFORMED BY

Dr. Todd

HOSPITAL NAME

Lambs Gap AH

REFERRING VET

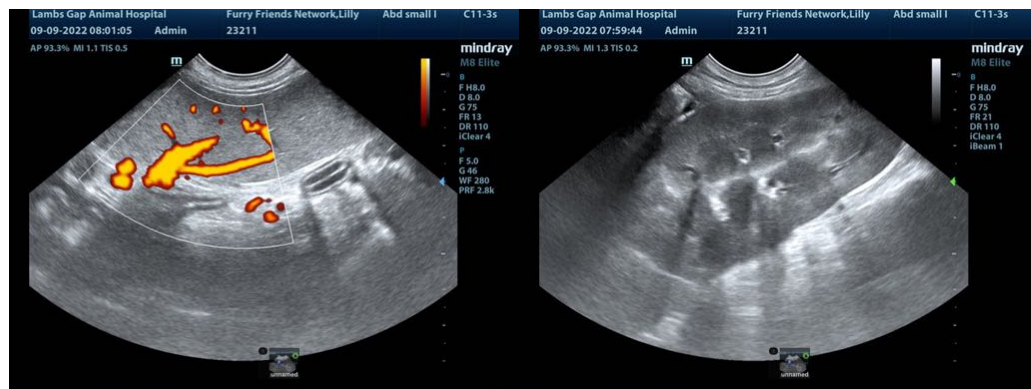
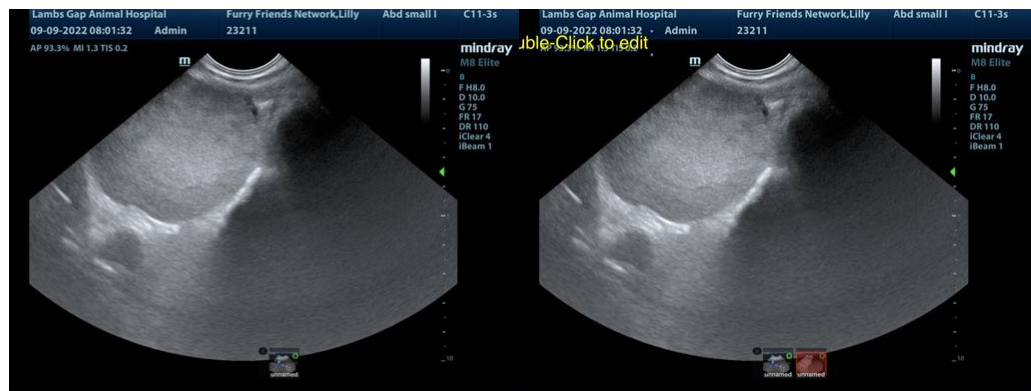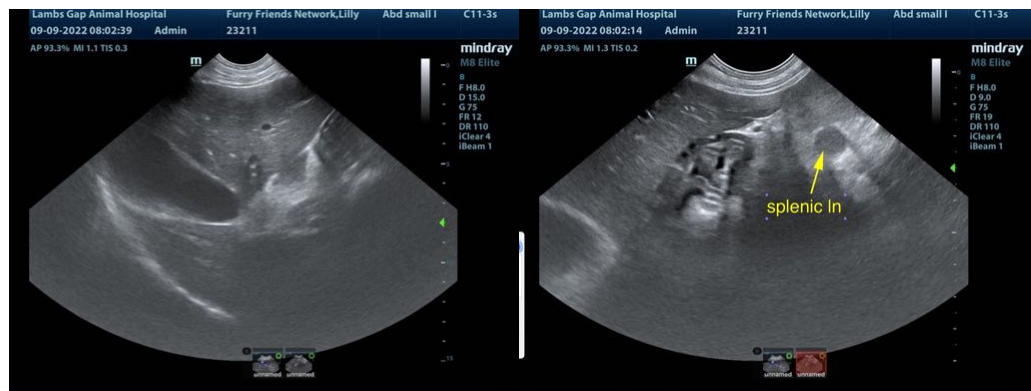
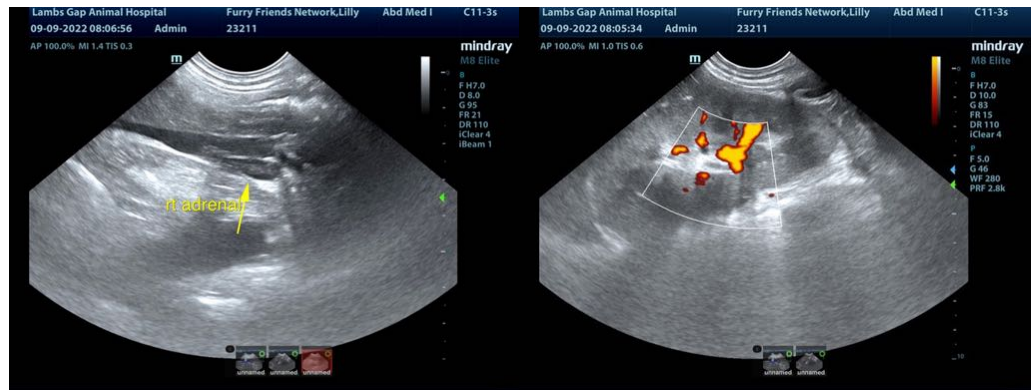
Dr. Todd

INVOICE

32825

DATE

9/8/22





PATIENT

Lilly Furry Friends Network

SPECIES

Canine

BREED

Hound Mix

SEX

Spayed female

AGE

6 years

WEIGHT

59 lbs

INTERPRETED BY

Eric Lindquist, DMV
DABVP, Cert. IVUSS

IMAGING PERFORMED BY

Dr. Todd

HOSPITAL NAME

Lambs Gap AH

REFERRING VET

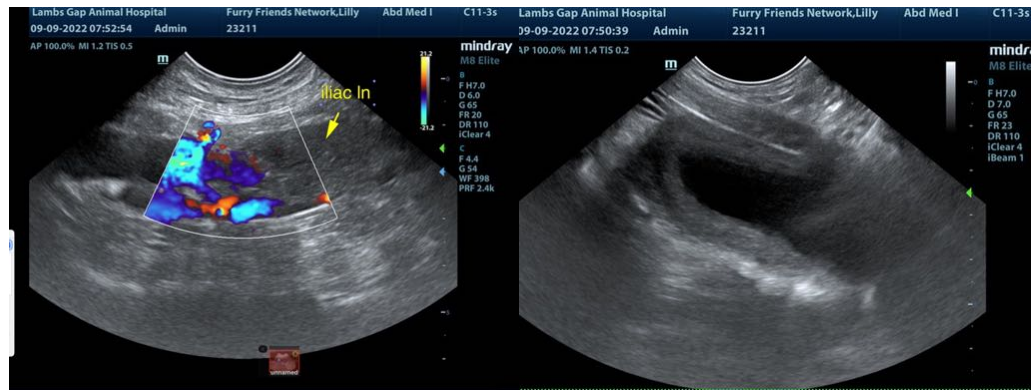
Dr. Todd

INVOICE

32825

DATE

9/8/22



The information and recommendations provided are based on the images presented by the referring veterinarian/sonographer. No evaluation can be communicated regarding pathology that was not visible in the image/video clips provided.

Thank you for this referral. If the clinical or image interpretation does not parallel your findings or if I can be of any further assistance please contact me.

Eric Lindquist, DMV, DABVP, Cert. IVUSS, CEO of SonoPath.com
info@SonoPath.com