



PATIENT

Daisy Mae Dough Face
Urlacher

SPECIES

Canine

BREED

English Bulldog

SEX

Spayed Female

AGE

4 Years

WEIGHT

50 Pounds

INTERPRETED BY

Eric Lindquist, DMV
DABVP, Cert. IVUSS

IMAGING PERFORMED BY

Dr. Kimberly Barron

HOSPITAL NAME

Northshore VH

REFERRING VET

Dr. Kimberly Barron

INVOICE

41216

DATE

9/9/22

PRESENTING CLINICAL SIGNS

Proteinuria with UPC ratio of 7.5, thoracic and abdominal radiographs submitted as well. cbc chem wnl.

Abnormal PE/Chem/CBC/UA Results: UPC ratio is 7.5, hypoalbuminemia 1.6 (2.7-3.9)

ULTRASONOGRAPHIC EXAMINATION OF THE ABDOMEN

Urinary System

The **urinary bladder**, trigone, and pelvic urethra presented normal thicknesses and normal tone. The ureters were not visible which is normal. No uroliths or sediment were visualized and anechoic urine was present. No evidence of inflammatory or neoplastic changes were noted. Ureteral papillae were normal. The pelvic urethra was imaged 2.0 cm beyond the cystourethral junction.

The **kidneys** revealed normal size and structure, corticomedullary definition and ratio for this age. The cortices presented largely uniform texture with normal echogenic relationship to liver and spleen. Medullary structure differed distinctly from the cortex and no evidence of pelvic dilation was present. The capsules were acceptably uniform without significant irregularities. The right kidney measured 5.56 cm. The left kidney measured 5.86 cm.

Adrenal Glands

Both **adrenal glands** were visualized and recognized as having normal shape, size, position and echogenicity for this breed. The phrenic vasculature, glandular echogenicity and detail were unremarkable. Capsule, cortex, and medullary definition were normal for this age patient. The left adrenal gland measured 0.53 cm.

Spleen

The **spleen** presented a smooth homogeneous parenchyma hyperechoic to liver and renal cortical parenchyma. The capsule was smooth without noticeable expansion or deviation from within the spleen or adjacent pathology. The splenic vasculature demonstrated normal volume without signs of congestion or thrombosis. No sonographic evidence of acute or chronic inflammatory, neoplastic, or infarctual changes were noted.

Liver

The **liver** images submitted revealed subjectively normal liver size, contour, and structure. Parenchymal echogenicity was naturally coarse and hypoechoic to the spleen. Vascular and biliary tracts were of normal volume with no evidence of congestion. The gallbladder presented acceptably thin walls with primarily anechoic content. The cystic and common bile ducts were normal. No pathological hepatic lymphadenopathy was evident. No overt structural evidence of inflammatory, infiltrative or regenerative pathology was evident.

Gastrointestinal

Examination of the **gastrointestinal tract** revealed a stomach and intestine free of stasis, of normal wall thickness, acceptable curvilinear mural detail, and peristaltic activity. Small and large intestine demonstrated normal luminal chyme and stool consistency respectively. No obstructive or overt infiltrative disease was noted. No associated abnormal lymphatic activity was noted.



PATIENT

Daisy Mae Dough Face
Urlacher

SPECIES

Canine

BREED

English Bulldog

SEX

Spayed Female

AGE

4 Years

WEIGHT

50 Pounds

INTERPRETED BY

Eric Lindquist, DMV

DABVP, Cert. IVUSS

IMAGING PERFORMED BY

Dr. Kimberly Barron

HOSPITAL NAME

Northshore VH

REFERRING VET

Dr. Kimberly Barron

INVOICE

41216

DATE

9/9/22

Pancreas

The base and limbs of the **pancreas** were observed to be largely isoechoic to surrounding omental fat. Pancreatic duct and capsular contour were acceptably normal and parenchyma respected normal curvilinear patterns. No overt evidence of active inflammatory or neoplastic disease was noted.

Free Abdomen

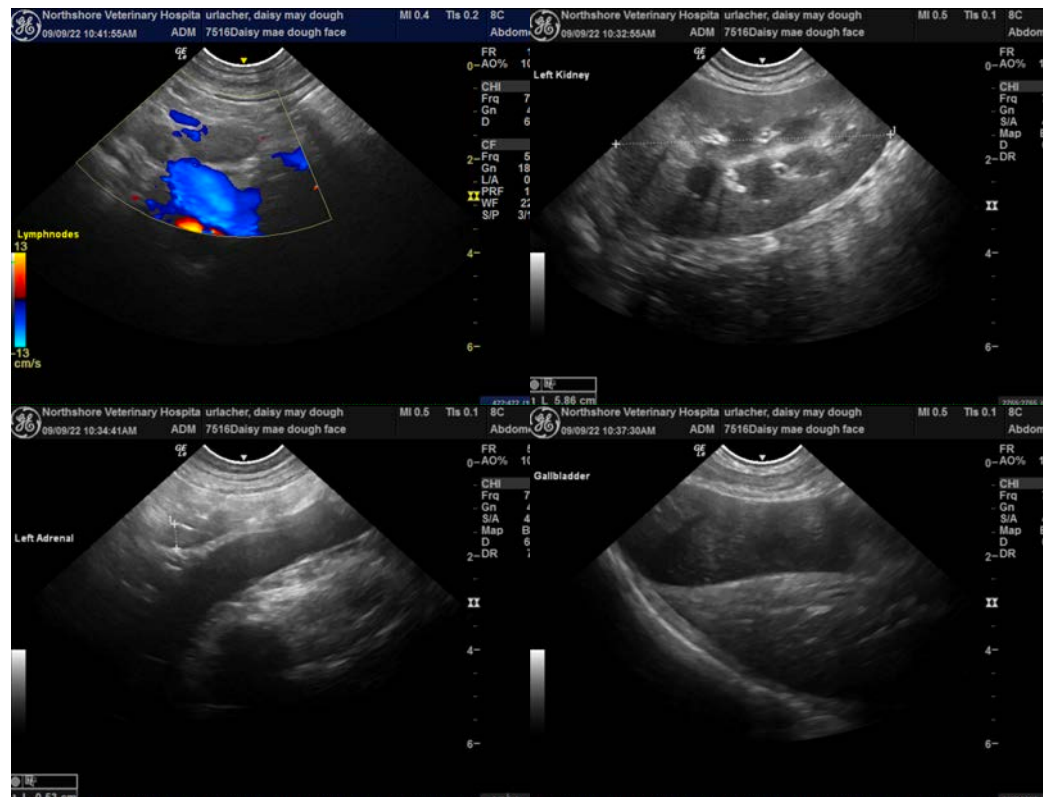
Reactive mesenteric lymph nodes noted up to 1.0 cm.

ULTRASONOGRAPHIC FINDINGS

- Structurally unremarkable abdomen, no evidence of pathology

INTERPRETATION OF THE FINDINGS & FURTHER RECOMMENDATIONS

Tick borne disease panel warranted. Doxycycline trial could be considered, given the proteinuria. Non-specific protein losing nephropathy. Renal biopsy would be necessary for further definition. Blood pressure measurements warranted. However, structurally the abdomen appears unremarkable.





PATIENT

Daisy Mae Dough Face
Urlacher

SPECIES

Canine

BREED

English Bulldog

SEX

Spayed Female

AGE

4 Years

WEIGHT

50 Pounds

INTERPRETED BY

Eric Lindquist, DMV

DABVP, Cert. IVUSS

IMAGING PERFORMED BY

Dr. Kimberly Barron

HOSPITAL NAME

Northshore VH

REFERRING VET

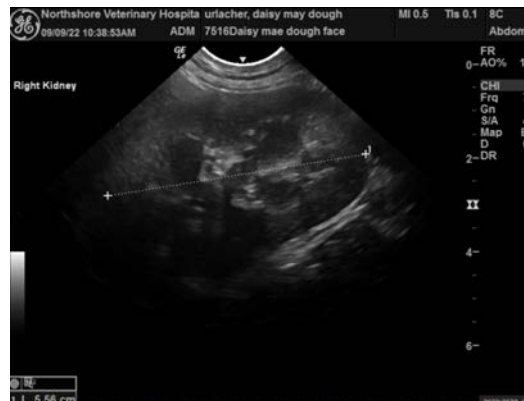Dr. Kimberly Barron

INVOICE

41216

DATE

9/9/22



The information and recommendations provided are based on the images presented by the referring veterinarian/sonographer. No evaluation can be communicated regarding pathology that was not visible in the image/video clips provided.

Thank you for this referral. If the clinical or image interpretation does not parallel your findings or if I can be of any further assistance please contact me.

Eric Lindquist, DMV, DABVP, Cert. IVUSS, CEO of SonoPath.com

info@SonoPath.com

Protein-Losing Nephropathy (PLN)

<http://www.sonopath.com/PLN>

Description: Protein-losing nephropathy (PLN) is a common form of renal disease that typically affects dogs in middle age; it occurs less commonly in cats. Glomerular causes of renal protein loss encompass two broad categories: glomerulonephritis (GN) and amyloidosis. (The causes of GN in human medicine are more specifically differentiated based on a combination of histopathology, immunofluorescence, and electron microscopy findings.) Membranoproliferative glomerulonephritis is the most common cause of GN in dogs and is associated with infectious disease with secondary immune complex deposition as well as Lyme disease. Membranous nephropathy is the second most common cause of GN in dogs and the most common cause in cats. It occurs due to primary immune complex deposition on the urinary side of the basement membrane of the glomerulus, resulting in the leakage of albumin. Amyloidosis is caused by the deposition of amyloid A proteins in a β -pleated sheet configuration in the glomeruli. It is a familial disease in the Shar Pei, but occurs as a reactive disease in other canine breeds. It is also inheritable in the Abyssinian cat, but the amyloidosis occurs in the medulla and is therefore not a protein-losing condition in this breed.

Glomerular lesions can be associated with:

- Infectious diseases:
 - Protozoan: *Babesia*, *Hepatozoon*, and *Leishmania*.



PATIENT	
Daisy Mae Dough Face Urlacher	<ul style="list-style-type: none"> ○ Bacterial: <i>Borrelia</i>, <i>Bartonella</i>, <i>Brucella</i>, <i>Ehrlichia</i>, <i>Mycoplasma</i>, pyometra, pyoderma, endocarditis, and pyelonephritis. ○ Viral: FeLV, FIV, and FIP. ○ Fungal ○ Helminthic: <i>Dirofilaria</i>.
SPECIES	
Canine	<ul style="list-style-type: none"> ● Non-infectious inflammatory diseases: pancreatitis, chronic dermatitis, inflammatory bowel disease, periodontal disease, polyarthritis, and systemic lupus erythematosus (SLE). ● Neoplasia: lymphoma, leukemia, and mast cell disease. ● Familial conditions in the soft-coated Wheaten Terrier, Shar Pei, Beagle, Cocker Spaniel, and Bernese mountain dog. ● Idiopathic conditions.
BREED	
English Bulldog	
SEX	
Spayed Female	Post-glomerular causes, such as hemorrhage and inflammation, also contribute to urine protein quantification.
AGE	
4 Years	<i>Proteinuria Classifications:</i> Patients can be divided into three tiers, depending on their clinical characteristics:
WEIGHT	
50 Pounds	<p>Tier 1A: persistent subclinical proteinuria</p> <p>Tier 1B: persistent proteinuria with hypertension</p>
INTERPRETED BY	
Eric Lindquist, DMV DABVP, Cert. IVUSS	<p>Tier 2A: proteinuria and hypoalbuminemia</p> <p>Tier 2B: proteinuria, hypoalbuminemia, and hypertension</p>
IMAGING PERFORMED BY	
Dr. Kimberly Barron	<p>Tier 3A: proteinuria and azotemia</p> <p>Tier 3B: proteinuria, azotemia, and hypertension</p>
HOSPITAL NAME	
Northshore VH	Tier 3C: proteinuria, azotemia, hypertension, and hypoalbuminemia
REFERRING VET	
Dr. Kimberly Barron	
INVOICE	
41216	
DATE	
9/9/22	

Diagnostics: Traditionally, urine protein loss has been detected either through a qualitative test, such as a urine dipstick, or with a semi-quantitative test, such as a urine protein-creatinine (UPC) ratio. When the latter is greater than 0.5, it is considered abnormal. False positive results can occur due to contamination of urine with red blood cells, white blood cells, and bacterial protein. Thus, one must use a urine sample with inactive sediment and a negative culture for measurement purposes. A 24-hour urine protein quantification is more accurate but technically more difficult to obtain, as it requires hospitalization and 24-hour urinary catheterization with a closed collection system. Pooling urine samples can be considered in cases where urine protein loss is stable. One must obtain three different urine samples, combine 1 ml from each sample to submit for a UPC test, and ensure that inactive sediments are present in all the samples. There should be a high degree of correlation between the UPC on the pooled sample and the mean of the three samples measured



PATIENT

Daisy Mae Dough Face
Urlacher

independently. Research has not yet demonstrated the accuracy of pooled samples for urine samples with high protein loss (i.e., in cases where the UPC is > 8).

SPECIES

Canine

Further diagnostic tests will depend on the tier classification. Once proteinuria is documented repeatedly, additional tests can be considered to assess for potential underlying causes, and, further to that, possible sources of antigen stimulation. Depending on presentation, tests may include:

BREED

English Bulldog

SEX

Spayed Female

AGE

4 Years

WEIGHT

50 Pounds

- CBC and biochemical profile
- Urine culture and sensitivity
- 4DX
- Blood pressure measurement
- Thoracic and abdominal radiographs
- Spinal radiographs to assess for discospondylitis
- Abdominal ultrasound to assess for evidence of underlying infection or neoplasia
- Echocardiogram to assess for vegetative endocarditis and possible effects of hypertension
- Screen for Cushing's disease, especially if hypertensive (LDDST or ACTH stimulation)
- ANA
- Expanded tick or infectious disease screen
- Renal biopsy to differentiate among specific causes of PLN

INTERPRETED BY

Eric Lindquist, DMV

DABVP, Cert. IVUSS

Renal biopsy should be considered if proteinuria is severe (UPC > 3.5) and hypoalbuminemia and/or hypertension have been documented. Renal biopsy is an invasive procedure and should be considered only to determine if there is an underlying disease process that would benefit from specific therapy. If the patient is debilitated, severely azotemic, or has uncontrolled hypertension or coagulation abnormalities, then the risk of the procedure and anesthesia may be too great and should not be pursued.

IMAGING PERFORMED BY

Dr. Kimberly Barron

HOSPITAL NAME

Northshore VH

Tissue samples should be submitted for a combination of light microscopy (in formalin; use with special stains), immunofluorescence (in Michel's solution or frozen), and electron microscopy (in formalin with glutaraldehyde). It is imperative to request special media before obtaining the biopsy. Samples can be obtained via ultrasound guidance, laparotomy, or laparoscopy, but cortical samples must be divided so that they can be placed in the three different media. One must ensure that the pre-surgical clotting profile and platelet count are both normal. Patients should undergo pre-biopsy and post-biopsy diuresis.

REFERRING VET

Dr. Kimberly Barron

INVOICE

41216

DATE

9/9/22

Treatment: The main goals of therapy are to i) reduce proteinuria (i.e., UPC < 1.0); ii) prevent a thrombotic event; iii) manage hypertension; and iv) replace fluid deficits. Fluid therapy should be approached cautiously, especially in patients with nephrotic syndrome. Standard therapy for PLN includes a low-protein diet, which in itself will reduce proteinuria, and the administration of an



PATIENT

Daisy Mae Dough Face
Urlacher

angiotensin-converting enzyme (ACE) inhibitor, such as enalapril (0.5 mg/kg PO BID) or benazepril (0.5 mg/kg PO Q24hr). Newer proposed therapeutic protocols include increasing the ACE inhibitor dose slowly while monitoring BUN and creatinine carefully. The dose can be raised to 1 mg/kg PO BID if needed, provided creatinine has not increased more than 30% from the baseline level.

SPECIES

Canine

Another class of drugs currently being used is angiotensin receptor blockers, such as Losartan (the dose in azotemic dogs is 0.125-0.25 mg/kg/day PO Q12-24hr and 0.5-1.0 mg/kg/day in non-azotemic patients). This can be combined with an ACE inhibitor, but it is important to monitor BUN, creatinine, and potassium levels. Spironolactone has been used in people in combination with the other two classes of drugs to further modify the renin-angiotensin-aldosterone system (RAAS) (1-2 mg/kg PO BID); however, the effect of using all three drug classes in dogs has not yet been fully investigated. All of these medications are potassium sparing; thus, monitoring for hyperkalemia is important.

BREED

English Bulldog

SEX

Spayed Female

AGE

4 Years

Hypertension is managed with amlodipine (0.1-0.2 mg/kg PO Q12-24hr) when an ACE inhibitor is insufficient to control blood pressure. Supplementing with an anti-thrombotic agent, such as aspirin (1 mg/kg PO Q24hr), may be considered in advanced cases, especially once the patient is hypoalbuminemic. Omega-3 fatty acids can be given (0.25-0.5 g/day), but are typically increased in standard kidney diets.

WEIGHT

50 Pounds

INTERPRETED BY

Eric Lindquist, DMV
DABVP, Cert. IVUSS

The most recent controversy in the management of glomerular diseases is the use of immunosuppressive medications. Because it is possible to arrive at a more definitive diagnosis in human patients, the use of immunosuppressive agents can be useful in the management of the disease, specifically when the disease is immune-mediated in its pathogenesis, such as SLE, membranous nephropathy, and minimal change disease glomerulonephritis. The procurement of a renal biopsy is being advocated in dogs so that practitioners can identify the population of patients that may benefit most from immunosuppressive therapy. Presently, there is no evidence-based medicine to suggest that immunosuppressive therapy should definitely be incorporated into a daily protocol for canine patients; however, it could be beneficial in some cases and may even result in remission. Further investigation is warranted. Trials are currently being conducted in patients with Lyme nephritis that are treated with immunosuppressive agents in addition to standard antibiotic therapy. The IRIS Treatment of Canine Glomerular Disease Study Group has suggested the trial use of immunosuppressive therapy in severe, persistent, or progressive PLN, even without a biopsy diagnosis in specific cases that are unresponsive to standard therapy (i.e., nephrotic syndrome, progressively azotemic, hypoalbuminemic patients). One can also consider administering the following drugs: pulse steroid therapy, mycophenolate, cyclophosphamide, azathioprine, and chlorambucil. One should monitor blood work, UPC ratio, and blood pressure weekly for 2 weeks, then biweekly for 6 weeks, then monthly. If there is further deterioration, immunosuppressive therapy should be discontinued.

IMAGING PERFORMED BY

Dr. Kimberly Barron

HOSPITAL NAME

Northshore VH

REFERRING VET

Dr. Kimberly Barron

INVOICE

41216

DATE

9/9/22



PATIENT

Daisy Mae Dough Face
Urlacher

SPECIES

Canine

BREED

English Bulldog

SEX

Spayed Female

AGE

4 Years

WEIGHT

50 Pounds

INTERPRETED BY

Eric Lindquist, DMV

DABVP, Cert. IVUSS

IMAGING PERFORMED BY

Dr. Kimberly Barron

HOSPITAL NAME

Northshore VH

REFERRING VET

Dr. Kimberly Barron

INVOICE

41216

DATE

9/9/22

References:

Goldstein R and Polzin D. Treatment of canine glomerular disease: report of the IRIS treatment of canine glomerular disease study group. Proceedings from the American College of Veterinary Internal Medicine, Denver, CO, June 15-18, 2011.

Grauer GF, Greco DS, Getzy DM, et al. Effects of enalapril versus placebo as a treatment for canine idiopathic glomerulonephritis. *J Vet Intern Med* 2000;14:526-33.

Less GE, Cianciolo RE, and Clubb FJ. Renal biopsy and pathologic evaluation of glomerular disease. *Top Companion Anim Med* 2011;26(3):143-53.

LeVine DA, Zhang D, Vaden SL. The use of pooled vs. serial urine samples to measure urine protein:creatinine ratios. *Vet Clin Pathol* 2010;39(1):53-56.

Nabity MB, Boggess MM, Kashtan CE, et al. Day-to-day variability in the urine protein:creatinine ratio in female dogs with stable glomerular proteinuria caused by x-linked hereditary nephropathy. *J Vet Intern Med* 2007;21:425-30.

Vaden SL. Glomerular Disease. *Top Companion Anim Med* 2011;26(3):128-34.

Vaden SL. Glomerular Diseases. In: Ettinger SJ and Feldman EC, eds. *Textbook of Veterinary Internal Medicine, 7th Ed.* St Louis, MI: Saunders Elsevier; 2010;2021-36.

Vaden SL. Microalbuminuria: What is it and how do I interpret it. Proceedings from the American College of Veterinary Internal Medicine, Charlotte, NC, June 4-7, 2003.

Vaden SL et al. Urinary tract inflammation has a variable effect in urine albumin concentration. *J Vet Intern Med* 2002;16:378 (abstract).