



PATIENT

Daisy Martineau

SPECIES

Canine

BREED

Great Pyrenees

SEX

Spayed Female

AGE

8 years

WEIGHT

104 lbs

INTERPRETED BY

Eric Lindquist, DMV
DABVP, Cert. IVUSS

IMAGING PERFORMED BY

Mack

HOSPITAL NAME

Northside VC

REFERRING VET

Dr. Mack

INVOICE

91758

DATE

9/9/21

PRESENTING CLINICAL SIGNS

History: Mast Cell Tumor removed 1yr ago. Owners do not currently have any concerns for patient, ultrasound is being performed and sent out as a precautionary measure due to previous Mast Cell diagnosis.
Recent bloodwork and radiographs were unremarkable.

ULTRASONOGRAPHIC EXAMINATION OF THE ABDOMEN

Urinary System

The **urinary bladder**, trigone, and pelvic urethra presented normal thicknesses and normal tone. The pelvic urethra was imaged 2.0 cm beyond the cystourethral junction. The ureters were not visible which is normal. No uroliths or sediment were visualized and anechoic urine was present. No evidence of inflammatory or neoplastic changes was noted. Ureteral papillae were normal.

The **kidneys** revealed normal size and structure, corticomedullary definition and ratio for this age. The cortices presented largely uniform texture with normal echogenic relationship to liver and spleen. Medullary structure differed distinctly from the cortex and no evidence of pelvic dilation was present. The capsules were acceptably uniform without significant irregularities. The kidneys each measured 4.0 cm.

Adrenal Glands

The regions of the **adrenal glands** were unremarkable.

Spleen

The **spleen** presented a smooth homogeneous parenchyma hyperechoic to liver and renal cortical parenchyma. The capsule was smooth without noticeable expansion or deviation from within the spleen or adjacent pathology. The splenic vasculature demonstrated normal volume without signs of congestion or thrombosis. No sonographic evidence of acute or chronic inflammatory, neoplastic, or infarctual changes was noted.

Liver

The **liver** is largely unremarkable; however, two separate 1.0 cm nodules were noted in the left medial liver. The gallbladder presented acceptably thin walls with primarily anechoic content. The cystic and common bile ducts were normal. No pathological hepatic lymphadenopathy was evident.

Gastrointestinal

Examination of the **gastrointestinal tract** revealed a stomach and intestine free of stasis, of normal wall thickness, acceptable curvilinear mural detail, and peristaltic activity. Small and large intestine demonstrated normal luminal chyme and stool consistency respectively. No obstructive or overt infiltrative disease was noted. No associated abnormal lymphatic activity was noted.

Pancreas



PATIENT

Daisy Martineau

The base and limbs of the **pancreas** were observed to be largely isoechoic to surrounding omental fat. Pancreatic duct and capsular contour were acceptably normal and parenchyma respected normal curvilinear patterns. No overt evidence of active inflammatory or neoplastic disease was noted.

SPECIES

Canine

ULTRASONOGRAPHIC FINDINGS

Structurally unremarkable abdomen.

BREED

Great Pyrenees

Undefined liver nodules, possible hyperplasia versus metastatic disease.

SEX

Spayed Female

INTERPRETATION OF THE FINDINGS & FURTHER RECOMMENDATIONS

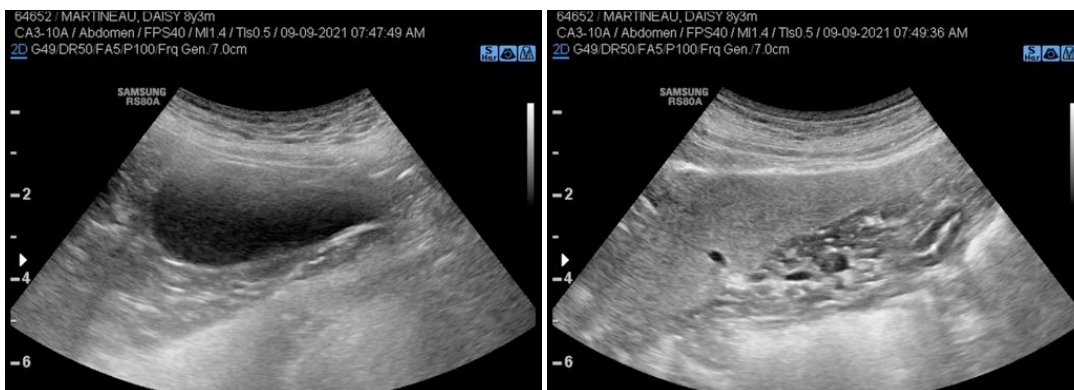
I recommend assessment of the cytology and ultrasound-guided monitoring of these nodules over the next 3-4 weeks.

AGE

8 years

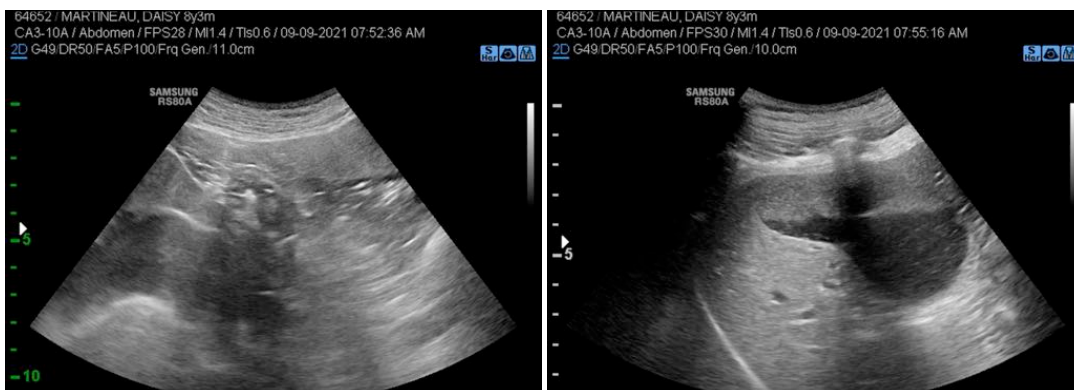
WEIGHT

104 lbs



INTERPRETED BY

Eric Lindquist, DMV
DABVP, Cert. IVUSS



IMAGING PERFORMED BY

Mack

HOSPITAL NAME

Northside VC

REFERRING VET

Dr. Mack

INVOICE

91758

DATE

9/9/21



PATIENT

Daisy Martineau

SPECIES

Canine

BREED

Great Pyrenees

SEX

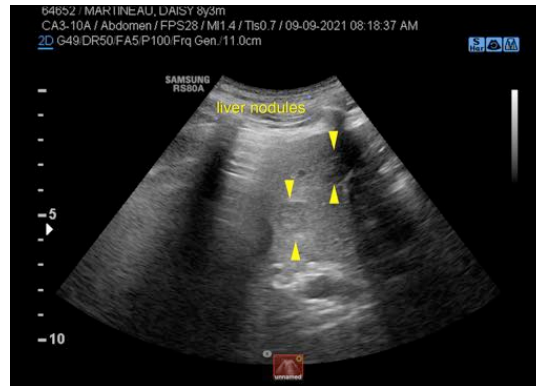
Spayed Female

AGE

8 years

WEIGHT

104 lbs



The information and recommendations provided are based on the images presented by the referring veterinarian. No evaluation can be communicated regarding pathology that was not visible in the image/video clips provided.

Thank you for this referral. If the clinical or image interpretation does not parallel your findings or if I can be of any further assistance please contact me.

Eric Lindquist, DMV, DABVP, Cert. IVUSS, CEO of SonoPath.com
info@SonoPath.com

INTERPRETED BY

Eric Lindquist, DMV
DABVP, Cert. IVUSS

IMAGING PERFORMED BY

Mack

HOSPITAL NAME

Northside VC

REFERRING VET

Dr. Mack

INVOICE

91758

DATE

9/9/21