



PATIENT	PRESENTING CLINICAL SIGNS
Red DeNicola	History: One plus year history of weight loss. Blood work revealed neutropenia and panhypoproteinemia. No known vomiting or diarrhea. Screening for GI disease.
SPECIES	ULTRASONOGRAPHIC EXAMINATION OF THE ABDOMEN
Feline	Urinary System
BREED	The urinary bladder , trigone, and pelvic urethra presented normal thicknesses and normal tone. The ureters were not visible which is normal. No uroliths or sediment were visualized and anechoic urine was present. No evidence of inflammatory or neoplastic changes was noted. Ureteral papillae were normal.
Domestic Shorthair	
SEX	The kidneys revealed normal size and structure, corticomedullary definition and ratio for this age. The cortices presented largely uniform texture with normal echogenic relationship to liver and spleen. Medullary structure differed distinctly from the cortex and no evidence of pelvic dilation was present. The capsules were acceptably uniform without significant irregularities. The left kidney measured 3.51 cm. The right kidney measured 3.9 cm.
Spayed female	
AGE	
11 years	
WEIGHT	Adrenal Glands
10.7 lbs	Both adrenal glands were visualized and recognized as having normal shape, size, position and echogenicity for this breed. The phrenic vasculature, glandular echogenicity and detail were unremarkable. Capsule, cortex, and medullary definition were normal for this age patient.
INTERPRETED BY	Spleen
Eric Lindquist, DMV DABVP, Cert. IVUSS	The spleen presented a smooth homogeneous parenchyma hyperechoic to liver and renal cortical parenchyma. The capsule was smooth without noticeable expansion or deviation from within the spleen or adjacent pathology. The splenic vasculature demonstrated normal volume without signs of congestion or thrombosis. No sonographic evidence of acute or chronic inflammatory, neoplastic, or infarctual changes was noted.
IMAGING PERFORMED BY	Liver
M Kermendy CVT	The liver was subnormal in size. There was no evidence of intrahepatic or extrahepatic shunting. However, short axis width of the liver was approximately 2.0 cm. The gallbladder was mildly echogenic with minor mineralization.
HOSPITAL NAME	
Wauwautosa VC	
REFERRING VET	Gastrointestinal
Dr. Haynes	Examination of the gastrointestinal tract revealed a stomach free of stasis, of normal wall thickness, acceptable curvilinear mural detail, and peristaltic activity. The intestinal walls measured up to 0.25 cm. No associated abnormal lymphatic activity was noted.
INVOICE	
32763	
DATE	
9/7/22	



PATIENT

Pancreas

Red DeNicola

The base and limbs of the **pancreas** were observed to be largely isoechoic to surrounding omental fat. Pancreatic duct and capsular contour were acceptably normal and parenchyma respected normal curvilinear patterns. No overt evidence of active inflammatory or neoplastic disease was noted.

SPECIES

Feline

ULTRASONOGRAPHIC FINDINGS

BREED

Stable lobar biliary mineralization, non-obstructive. Mild microhepatica.

Domestic Shorthair

Otherwise, unremarkable abdomen.

SEX

INTERPRETATION OF THE FINDINGS & FURTHER RECOMMENDATIONS

Spayed female

There was no evidence of visceral disease directly affecting the clinical presentation. Maldigestion panel, three view chest radiographs and full CNS examination is recommended to examine for occult disease that could be responsible for the weight loss. Evaluation for competitive eating environments should also be considered. Ursodiol therapy can be considered from a palliative approach, yet it is highly variable on patient to patient on the ability to dissolve biliary mineralization.

AGE

11 years

WEIGHT

10.7 lbs

INTERPRETED BY

Eric Lindquist, DMV
DABVP, Cert. IVUS

IMAGING PERFORMED BY

M Kermendy CVT

HOSPITAL NAME

Wauwautosa VC

REFERRING VET

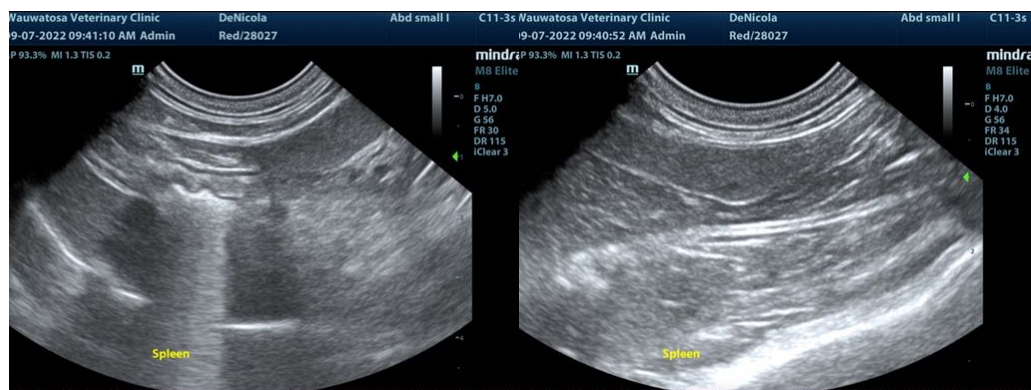
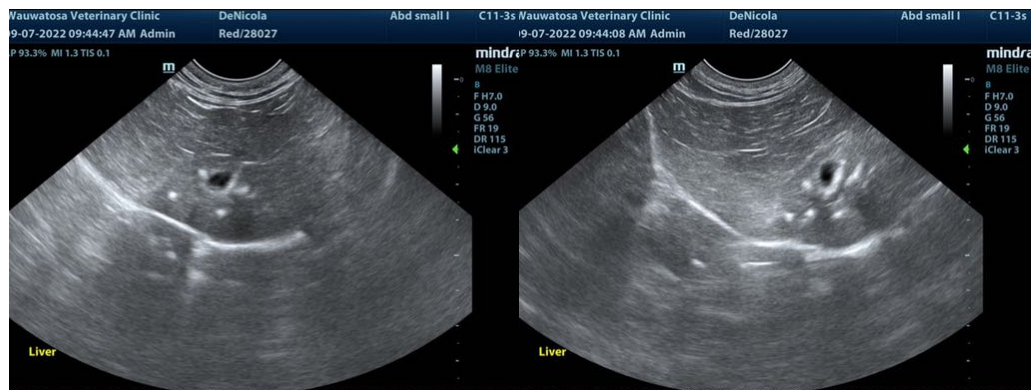
Dr. Haynes

INVOICE

32763

DATE

9/7/22





PATIENT

Red DeNicola

SPECIES

Feline

BREED

Domestic Shorthair

SEX

Spayed female

AGE

11 years

WEIGHT

10.7 lbs

INTERPRETED BY

Eric Lindquist, DMV
DABVP, Cert. IVUSS

IMAGING PERFORMED BY

M Kermendy CVT

HOSPITAL NAME

Wauwautosa VC

REFERRING VET

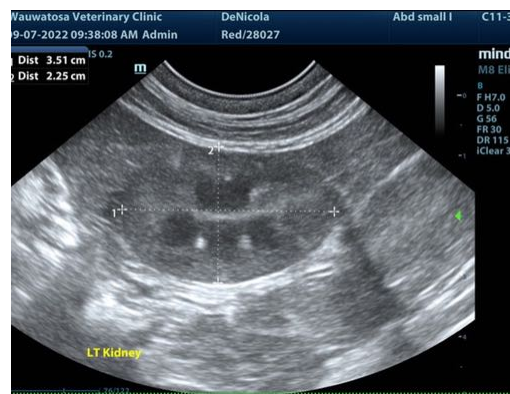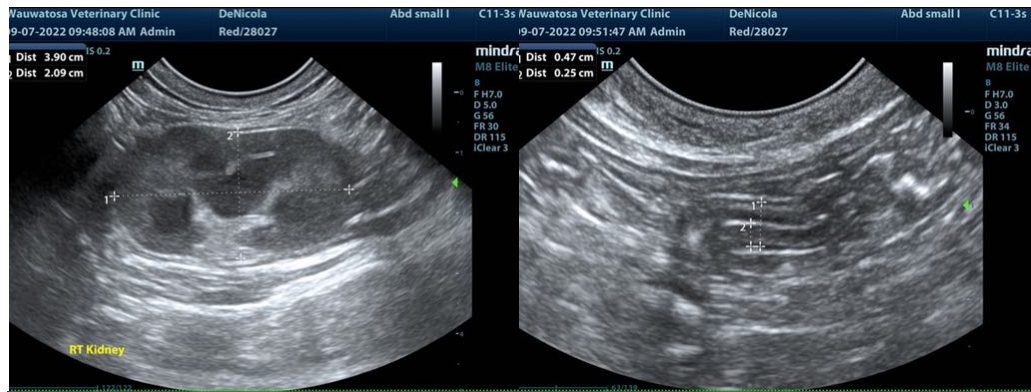
Dr. Haynes

INVOICE

32763

DATE

9/7/22



The information and recommendations provided are based on the images presented by the referring veterinarian/sonographer. No evaluation can be communicated regarding pathology that was not visible in the image/video clips provided.

Thank you for this referral. If the clinical or image interpretation does not parallel your findings or if I can be of any further assistance please contact me.

Eric Lindquist, DMV, DABVP, Cert. IVUSS, CEO of SonoPath.com
info@SonoPath.com