



PATIENT PRESENTING CLINICAL SIGNS

Owyn Clark

History: Increasing proBNP levels. Previous echo done, no report available. Showed mild cardiac changes. Sedated with Gabapentin and Trazodone.

SPECIES

Abnormal PE/Chem/CBC/UA Results: PE: Heart murmur Grade 2/6, longterm. CBC/Chem: WNL. HW4Dx: Neg x 4. ProBNP 2,015 Previous echo showed mild cardiac changes.

Canine

BREED

Hound Mix

SEX

Neutered male

AGE

8 years

WEIGHT

86 lbs

ULTRASONOGRAPHIC EXAMINATION OF THE HEART

The echocardiogram in this patient demonstrated normal **left atrial** size based on 3 different LA measurement methods. Chamber volumes and echogenicity were normal. The **mitral** valve was slightly vegetative, yet no evidence of any significant regurgitation was present. The **left ventricle** presented thicknesses with linear contour and was not dilated nor restricted. The **myocardium** presented normal echogenicity without subjective evidence of significant fibrotic or ischemic disease. **Contractility** of the ventricular walls was adequate and in normal range for this patient evidenced by the fractional shortening measurement and subjective evaluation of the different regions of the myocardium. The aortic outflow velocity was unremarkable. Mild aortic insufficiency was noted. This is not clinically significant. The **right atrium** and auricle revealed normal size, structure and content. No evidence of masses was noted or chamber overload. **Tricuspid** valvular assessment demonstrated adequate linear morphology. The **right ventricle** was of normal size (1/3 diameter of LV), chordae structure, myocardial echogenicity and thickness. **Pulmonic** tract assessment revealed normal valve structure, laminar flow, and diameter (approx. 1:1 pa/ao ratio). No visible **pericardial** or free pleura fluid was noted. No echographically detectable evidence of infiltrative disease was visible. The cranial **mediastinum and pericardial regions** were free of masses in the visible window. The hepatic veins were not dilated. There was no evidence of passive congestion.

INTERPRETED BY

Eric Lindquist, DMV
DABVP, Cert. IVUSS

IMAGING PERFORMED BY

Dr. Ebersole

HOSPITAL NAME

Scanvet

REFERRING VET

Dr. Cahdbourne

INVOICE

32778

DATE

9/7/22

CANINE CARDIAC PARAMETERS	MR VMAX (m/s)	TR VMAX (m/s)	LA/AO (Boon method)	LA/AO (Heart Base; Swe)	FS (%)	EF (%)	EPSS (cm)
NORMAL PARAMETER	4.5-5.5	<2.7	1.3	<1.6	28-40	40-100	<0.6
PATIENT			1.0	1.07			0.1
CANINE CARDIAC PARAMETERS	HR (BPM)	AV VMAX (m/s)	PV MAX (m/s)	BODY WEIGHT	LA 2D short axis Base view (cm)	LVIDd Avg; 2D and m- mode short axis (cm)	LVIDs Avg; 2D and m- mode short axis (cm)
NORMAL PARAMETER	50-100	0.7-1.7	0.7-1.6	BELOW	BELOW	BELOW	BELOW
PATIENT		1.28	0.68	86 lbs	3.9 max		



PATIENT

Owyn Clark

ULTRASONOGRAPHIC FINDINGS

Minor aortic insufficiency.
Structurally normal heart otherwise.

SPECIES

Canine

INTERPRETATION OF THE FINDINGS & FURTHER RECOMMENDATIONS

There was no evidence of clinical significant disease. Other trivial turbulence may be present in this patient or aortic insufficiency is the source of the murmur, yet regardless this is clinically significant outflow velocity. Contractility and volumes are all normal. There was no evidence of the cause of elevated BNP levels. False elevation, systemic disease, hypertension or other causes of cardiac insult or false elevations should be considered, yet the cardiac structure and function are essentially non clinical.

BREED

Hound Mix

SEX

Neutered male

AGE

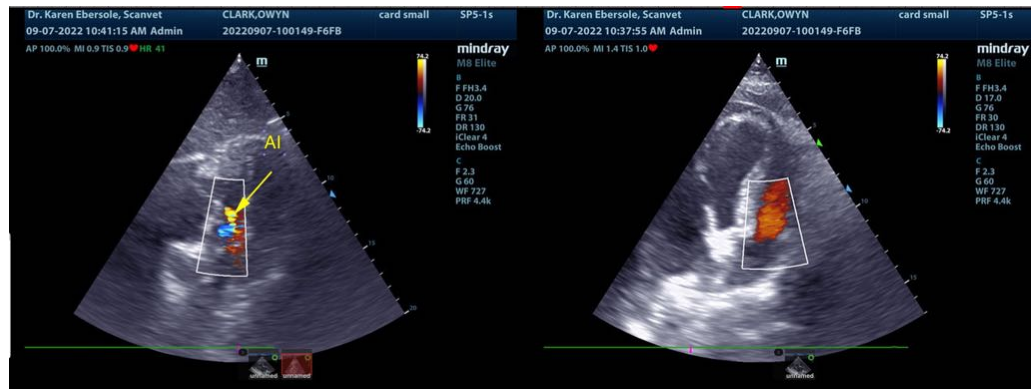
8 years

WEIGHT

86 lbs

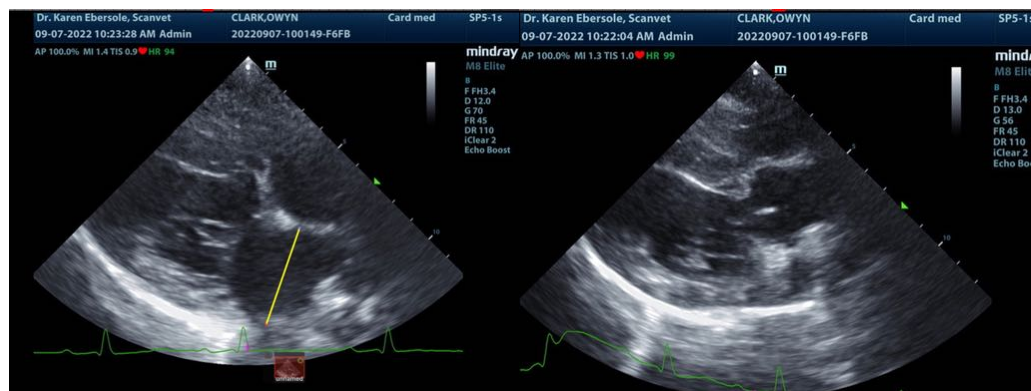
INTERPRETED BY

Eric Lindquist, DMV
DABVP, Cert. IVUS



IMAGING PERFORMED BY

Dr. Ebersole



HOSPITAL NAME

Scanvet

REFERRING VET

Dr. Cahdbourne

INVOICE

32778

DATE

9/7/22



PATIENT

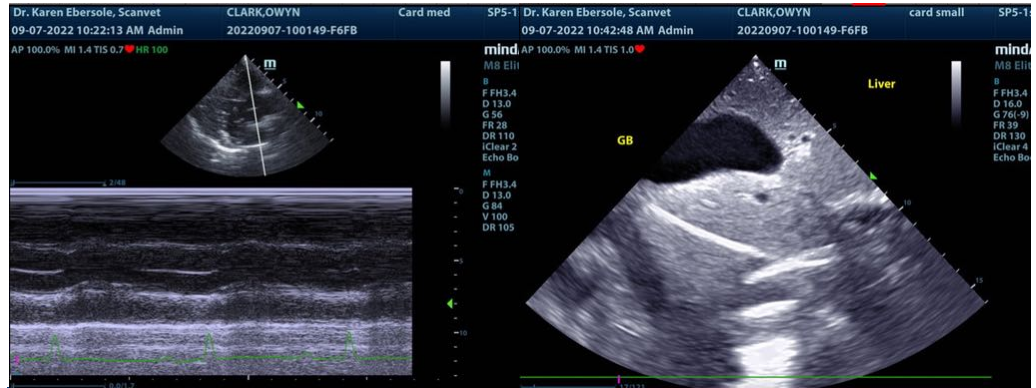
Owyn Clark

SPECIES

Canine

BREED

Hound Mix



SEX

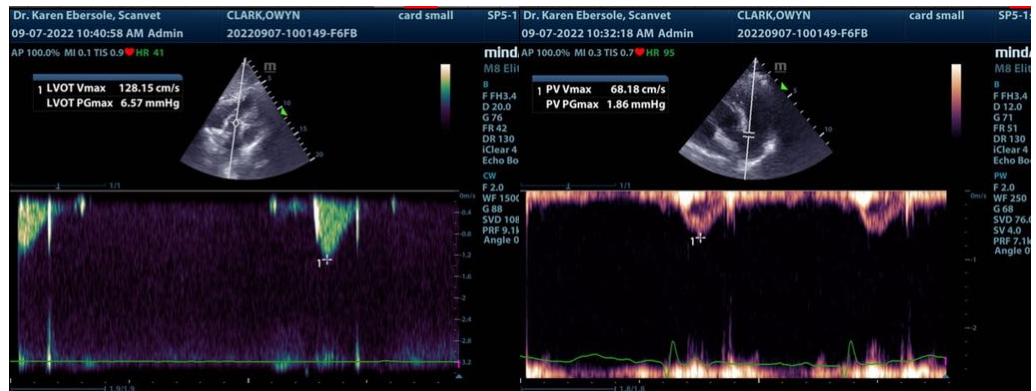
Neutered male

AGE

8 years

WEIGHT

86 lbs



INTERPRETED BY

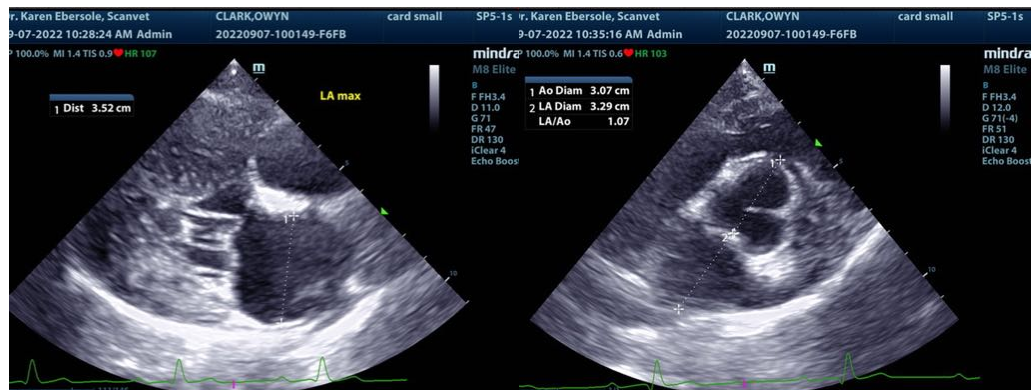
Eric Lindquist, DMV
DABVP, Cert. IVUSS

IMAGING PERFORMED BY

Dr. Ebersole

HOSPITAL NAME

Scanvet



REFERRING VET

Dr. Cahdbourne

INVOICE

32778

DATE

9/7/22

The information and recommendations provided are based on the images presented by the referring veterinarian/sonographer. No evaluation can be communicated regarding pathology that was not visible in the image/video clips provided.

Thank you for this referral. If the clinical or image interpretation does not parallel your findings or if I can be of any further assistance please contact me.

Eric Lindquist, DMV, DABVP, Cert. IVUSS, CEO of SonoPath.com
info@SonoPath.com