



**PATIENT**

Kiko Gershberg

**PRESENTING CLINICAL SIGNS**

Fluid in abd liver failure

**SPECIES**

Canine

**ULTRASONOGRAPHIC EXAMINATION OF THE ABDOMEN**

**Urinary System**

The **urinary bladder**, trigone, and pelvic urethra presented normal thicknesses and normal tone. The ureters were not visible which is normal. No uroliths or sediment were visualized and anechoic urine was present. No evidence of inflammatory or neoplastic changes were noted. Ureteral papillae were normal.

**BREED**

Terrier X

The **kidneys** were not visualized.

**SEX**

Neutered Male

**Adrenal Glands**

The **adrenal glands** were not visualized.

**AGE**

10 Years

**Spleen**

The **spleen** was not visualized and may be captured in the neoplastic process.

**Liver**

The **liver** presented diffuse coalescing nodular changes. Nodules coalesced into mass effects throughout the liver. The gallbladder was deviated.

**WEIGHT**

14.5 Pounds

**Gastrointestinal**

Examination of the **gastrointestinal tract** revealed a stomach and intestine free of stasis, of normal wall thickness, acceptable curvilinear mural detail, and peristaltic activity. Small and large intestine demonstrated normal luminal chyme and stool consistency respectively. No obstructive or overt infiltrative disease was noted.

**INTERPRETED BY**

Eric Lindquist, DMV

A mesenteric lymph node mass was noted, measuring 6.0 cm x 5.0 cm.

DABVP, Cert. IVUSS

**IMAGING PERFORMED BY**

Jenn

**Pancreas**

The **pancreas** was enveloped by the underlying pathology.

**HOSPITAL NAME**

Rockaway AH

**Free Abdomen**

Moderate amount of echogenic free fluid noted in the abdomen.

**ULTRASONOGRAPHIC FINDINGS**

**REFERRING VET**

Dr. Maniar

- Multicentric abdominal neoplasia primarily involving the lymph nodes and liver
- Secondary paraneoplastic effusion

**INTERPRETATION OF THE FINDINGS & FURTHER RECOMMENDATIONS**

**INVOICE**

41072

Prognosis is poor. FNA of the liver and lymph nodes could be considered for further definition.

**DATE**

9/7/22



**PATIENT**

Kiko Gershberg

**SPECIES**

Canine

**BREED**

Terrier X

**SEX**

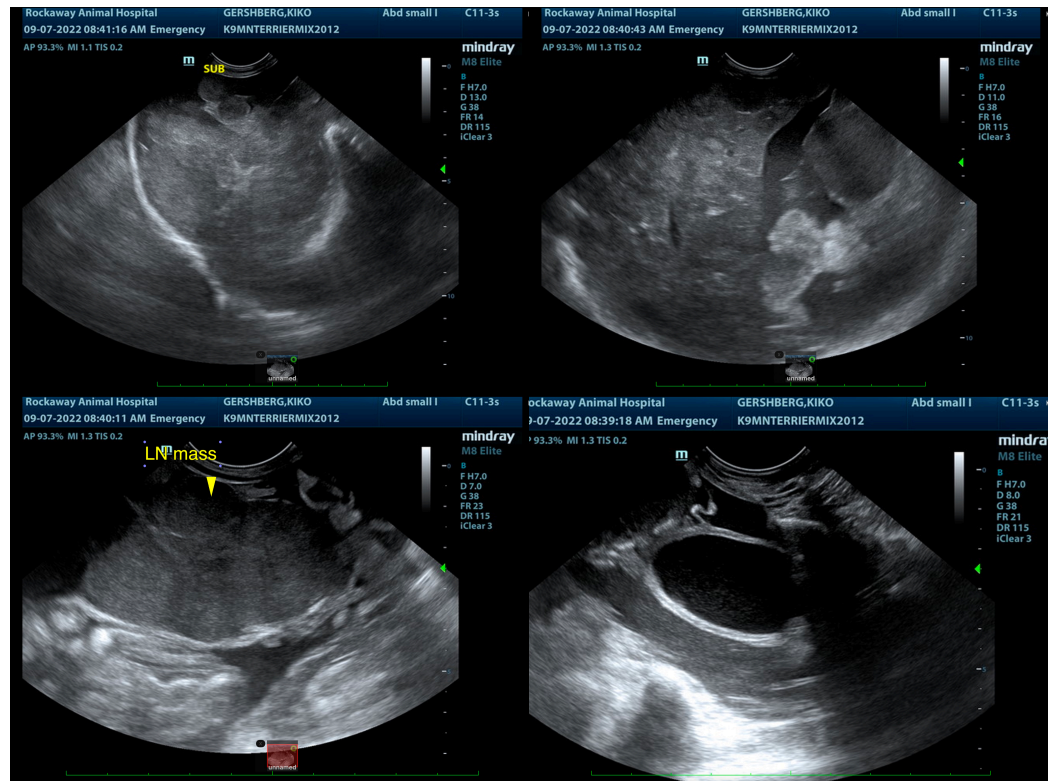
Neutered Male

**AGE**

10 Years

**WEIGHT**

14.5 Pounds



**INTERPRETED BY**

Eric Lindquist, DMV

DABVP, Cert. IVUSS

**IMAGING PERFORMED BY**

Jenn

**HOSPITAL NAME**

Rockaway AH

**REFERRING VET**

Dr. Maniar

**INVOICE**

41072

**DATE**

9/7/22

The information and recommendations provided are based on the images presented by the referring veterinarian/sonographer. No evaluation can be communicated regarding pathology that was not visible in the image/video clips provided.

Thank you for this referral. If the clinical or image interpretation does not parallel your findings or if I can be of any further assistance please contact me.

Eric Lindquist, DMV, DABVP, Cert. IVUSS, CEO of SonoPath.com

[info@SonoPath.com](mailto:info@SonoPath.com)