



PATIENT

Chester Bloomstein

SPECIES

Canine

BREED

Aussie-doodle

SEX

Neutered Male

AGE

14 Years

WEIGHT

62 Pounds

INTERPRETED BY

Eric Lindquist, DMV

DABVP, Cert. IVUSS

IMAGING PERFORMED BY

Kelly Vazquez

HOSPITAL NAME

Marsh Hospital for Animals

REFERRING VET

Dr. Milwicki

INVOICE

41070

DATE

9/7/22

PRESENTING CLINICAL SIGNS

Patient presented for diarrhea, abdominal mass seen on radiographs, and pancreatitis. One episode of malodorous vomiting yesterday. Patient is eating but small amounts. Current meds: Gabapentin, amlodipine, and Pred.

Abnormal PE/Chem/CBC/UA Results: Amylase 2,215, ALT 252, lipase 1318, CK 371, EOS. 0.039.

ULTRASONOGRAPHIC EXAMINATION OF THE HEART & ABDOMEN

CANINE CARDIAC PARAMETERS	MR VMAX (m/s)	TR VMAX (m/s)	LA/AO (Boon method)	LA/AO (Heart Base; Swe)	FS (%)	EF (%)	EPSS (cm)
NORMAL PARAMETER	4.5-5.5	<2.7	1.3	<1.6	28-40	40-100	<0.6
PATIENT			1.0	1.2	21	43	0.1
CANINE CARDIAC PARAMETERS	HR (BPM)	AV VMAX (m/s)	PV MAX (m/s)	BODY WEIGHT (kg)	LA 2D short axis Base view (cm)	LVIDd Avg; 2D and m-mode short axis (cm)	LVIDs Avg; 2D and m-mode short axis (cm)
NORMAL PARAMETER	50-100	0.7-1.7	0.7-1.6	BELOW	BELOW	BELOW	BELOW
PATIENT	160	1.37	0.73		3.66	8.09	

Cardiac Presentation

The echocardiogram in this patient demonstrated normal **left atrial** size based on 3 separate methods of LA evaluation. Trivial mitral insufficiency noted, not clinically significant. The **left ventricle** presented thicknesses with linear contour and was not dilated nor restricted. The **myocardium** presented normal echogenicity without subjective evidence of significant fibrotic or ischemic disease. **Contractility** of the ventricular walls was adequate and in normal range for this patient evidenced by the fractional shortening measurement and subjective evaluation of the different regions of the myocardium. The **left ventricular outflow** tract demonstrated normal laminar flow and subjective structural integrity. The **right atrium** and auricle revealed normal size, structure and content. No evidence of masses was noted. **Tricuspid** valvular assessment demonstrated adequate linear morphology and kinesis. The **right ventricle** was of normal size (1/3 diameter of LV), chordae structure, myocardial echogenicity and thickness. **Pulmonary outflow** tract assessment revealed normal valve structure, laminar flow, and diameter (approx. 1:1 pa/ao ratio). No visible **pericardial** or free pleura fluid was noted. The cranial **mediastinum** and **pericardial and extra-cardiac regions** were free of masses in the visible window.

Urinary System

The **urinary bladder** and trigone presented normal thicknesses and normal tone. The ureters were not visible which is normal. No uroliths or sediment were visualized and anechoic urine was present. No evidence of inflammatory or neoplastic changes were noted. Ureteral papillae were normal. The pelvic urethra was imaged 3.0 cm beyond the cystourethral junction. Slight urethral thickening noted, not likely to be neoplastic.



PATIENT

Chester Bloomstein

The **kidneys** revealed normal size and structure, corticomedullary definition and ratio for this age. The cortices presented largely uniform texture with normal echogenic relationship to liver and spleen. Medullary structure differed distinctly from the cortex and no evidence of pelvic dilation was present. The capsules were acceptably uniform without significant irregularities. The left kidney measured 6.2 cm.

SPECIES

Canine

Adrenal Glands

BREED

Aussie-doodle

The **left adrenal gland** was visualized and recognized as having largely normal shape, size, position and acceptable echogenicity for this age group and breed. Some heterogeneity was noted within the adrenal parenchyma without concerning capsular distortion. These changes are likely age related but should be monitored by sonogram should the patient be suspected of having adrenal disease. The left adrenal gland measured 2.03 cm x 0.93 cm at the caudal pole and 0.73 cm at the cranial pole.

SEX

Neutered Male

The **right adrenal gland** was visualized and recognized as having normal shape, size, position and echogenicity for this breed. The phrenic vasculature, glandular echogenicity and detail were unremarkable. Capsule, cortex, and medullary definition were normal for this age patient. The right adrenal gland measured 1.89 cm x 0.94 cm at the caudal pole and 0.73 cm at the cranial pole.

AGE

14 Years

Spleen

The **spleen** revealed an expansive parenchymal mass measuring approximately 7.0 cm in the caudal pole. The mass was pedunculated. No overt evidence of rupture.

WEIGHT

62 Pounds

Liver

The **liver** revealed increased portal markings and lobar biliary mineralization. The gallbladder was unremarkable.

INTERPRETED BY

Eric Lindquist, DMV

Gastrointestinal

A 3.4 cm **gastric** foreign body was noted with direct shadowing. The small intestine and colon were unremarkable.

DABVP, Cert. IVUSS

Pancreas

IMAGING PERFORMED BY

Kelly Vazquez

The base and limbs of the **pancreas** were observed to be largely isoechoic to surrounding omental fat. Some parenchymal remodeling, however, with mild deviation from curvilinear normalcy was observed. Pancreatic duct and capsular irregularities were present consistent with age related changes. If pain upon imaging (+ Murphy sign) was present or if the patient is focally painful in subxyphoid palpation then low-grade smoldering chronic pancreatitis should be suspected.

HOSPITAL NAME

Marsh Hospital for Animals

ULTRASONOGRAPHIC FINDINGS

REFERRING VET

Dr. Milwicki

- Trivial mitral insufficiency
- Splenic mass – differentials include benign yet precarious hyperplastic mass, hemangiosarcoma possible, yet this is a single lesion, suggestive for benign underlying histopathology.
- Gastric foreign body
- Hepatic remodeling with lobar biliary mineralization
- Slightly irregular left adrenal gland – likely hyperplasia, pheochromocytoma or adenocarcinoma less likely.

INVOICE

41070

INTERPRETATION OF THE FINDINGS & FURTHER RECOMMENDATIONS

DATE

9/7/22

No evidence of metastatic disease. Recommend 3-view chest radiographs to assess for metastatic disease, followed by splenectomy and gastrotomy. Left adrenalectomy may not be necessary but should



PATIENT

Chester Bloomstein

be inspected at surgery, given its irregular contour. No evident invasion noted. Blood pressure measurements warranted prior to surgery.

SPECIES

Canine

BREED

Aussie-doodle

SEX

Neutered Male

AGE

14 Years

WEIGHT

62 Pounds

INTERPRETED BY

Eric Lindquist, DMV

DABVP, Cert. IVUSS

IMAGING PERFORMED BY

Kelly Vazquez

HOSPITAL NAME

Marsh Hospital for Animals

REFERRING VET

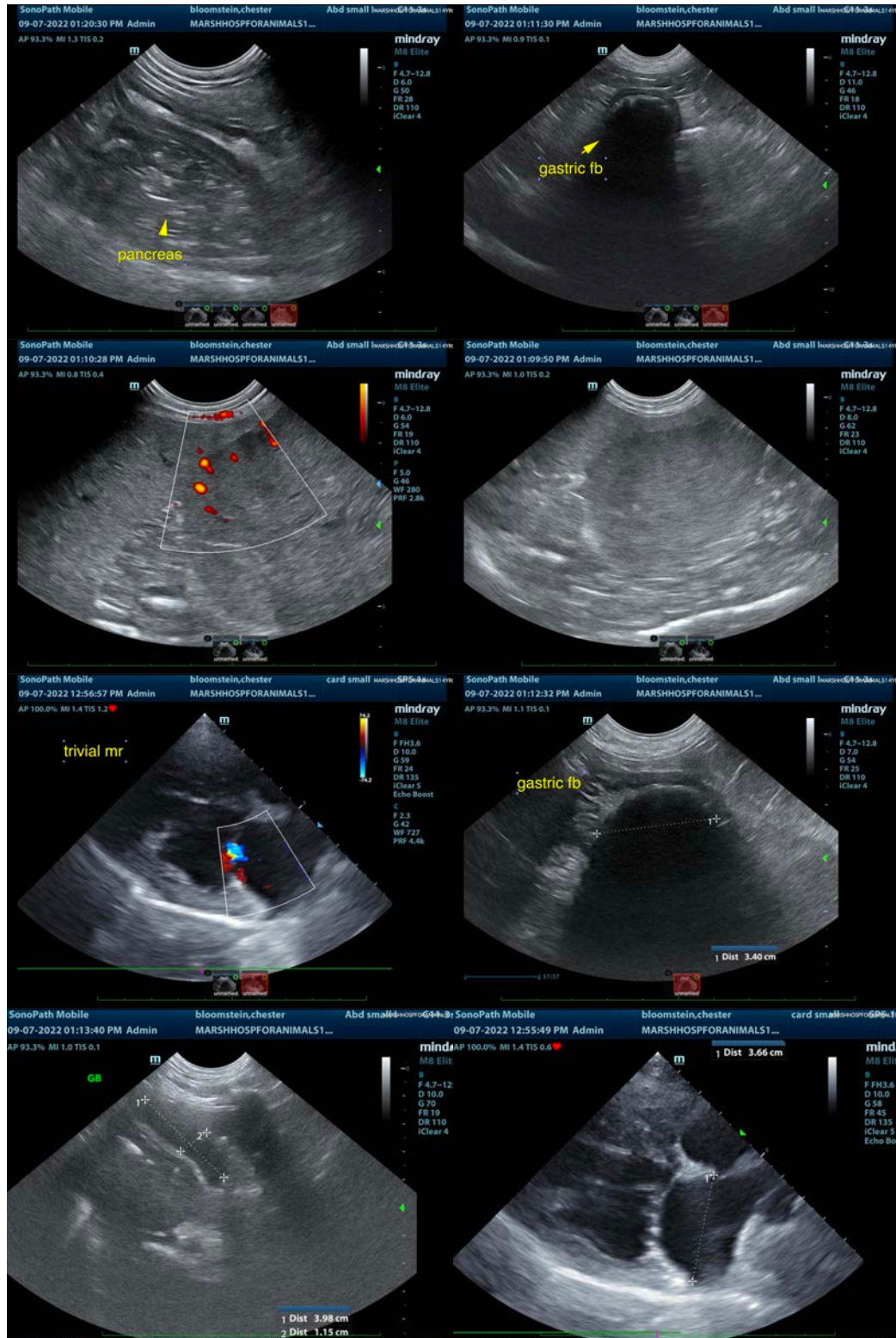
Dr. Milwicki

INVOICE

41070

DATE

9/7/22





PATIENT

Chester Bloomstein

SPECIES

Canine

BREED

Aussie-doodle

SEX

Neutered Male

AGE

14 Years

WEIGHT

62 Pounds

INTERPRETED BY

Eric Lindquist, DMV

DABVP, Cert. IVUSS

IMAGING PERFORMED BY

Kelly Vazquez

HOSPITAL NAME

Marsh Hospital for Animals

REFERRING VET

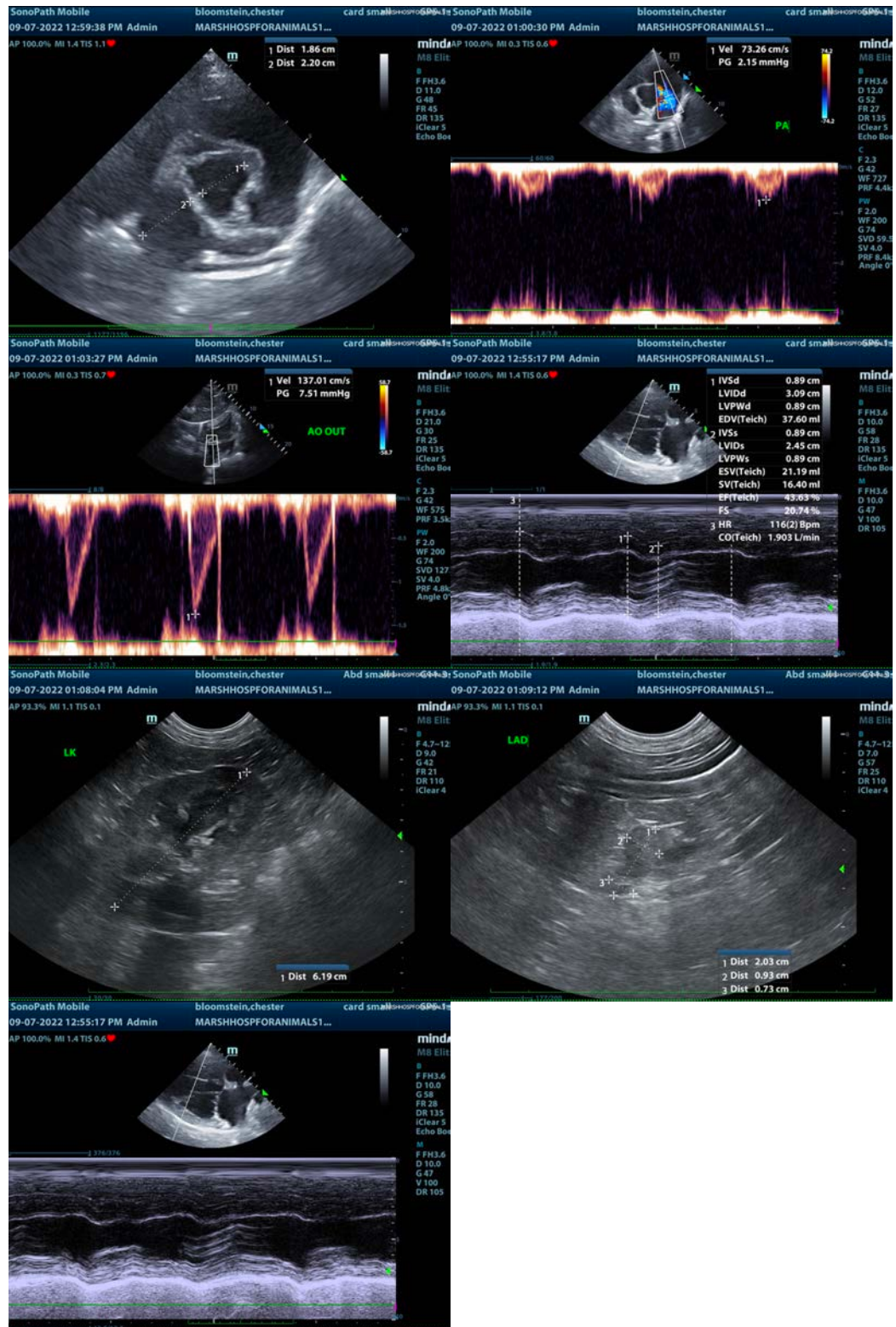
Dr. Milwicki

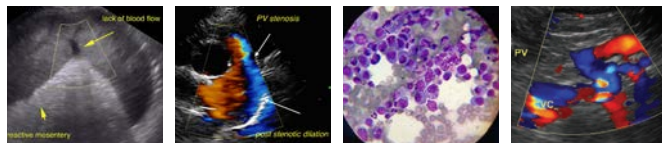
INVOICE

41070

DATE

9/7/22





PATIENT

Chester Bloomstein

The information and recommendations provided are based on the images presented by the referring veterinarian/sonographer. No evaluation can be communicated regarding pathology that was not visible in the image/video clips provided.

SPECIES

Canine

Thank you for this referral. If the clinical or image interpretation does not parallel your findings or if I can be of any further assistance please contact me.

Eric Lindquist, DMV, DABVP, Cert. IVUSS, CEO of SonoPath.com

info@SonoPath.com

BREED

Aussie-doodle

SEX

Neutered Male

AGE

14 Years

WEIGHT

62 Pounds

INTERPRETED BY

Eric Lindquist, DMV

DABVP, Cert. IVUSS

IMAGING PERFORMED BY

Kelly Vazquez

HOSPITAL NAME

Marsh Hospital for
Animals

REFERRING VET

Dr. Milwicki

INVOICE

41070

DATE

9/7/22