



PATIENT PRESENTING CLINICAL SIGNS

Zero Diggs History: On steroids elevated liver enzymes vomited hair fiber

SPECIES ULTRASONOGRAPHIC EXAMINATION OF THE ABDOMEN

Canine **Urinary System**

BREED The **urinary bladder**, trigone, and pelvic urethra presented normal thicknesses and normal tone. The ureters were not visible which is normal. No uroliths or sediment were visualized and anechoic urine was present. No evidence of inflammatory or neoplastic changes was noted. Ureteral papillae were normal.

Husky Mix

SEX

Spayed Female The **kidneys** revealed normal size and structure, corticomedullary definition and ratio for this age. The cortices presented largely uniform texture with normal echogenic relationship to liver and spleen. Medullary structure differed distinctly from the cortex and no evidence of pelvic dilation was present. The capsules were acceptably uniform without significant irregularities. The left kidney measured 7.55 cm.

AGE

4 years

WEIGHT

109 lbs

Adrenal Glands

The **adrenal glands** were not visualized.

INTERPRETED BY

Spleen

Eric Lindquist, DMV
DABVP, Cert. IVUSS

The **spleen** presented a smooth homogeneous parenchyma hyperechoic to liver and renal cortical parenchyma. The capsule was smooth without noticeable expansion or deviation from within the spleen or adjacent pathology. The splenic vasculature demonstrated normal volume without signs of congestion or thrombosis. No sonographic evidence of acute or chronic inflammatory, neoplastic, or infarctual changes was noted.

IMAGING PERFORMED BY

Jenn

HOSPITAL NAME

Liver

Rockaway AH

Exam of the cranial abdomen demonstrated excessive **liver** size and swollen contour. Mild, coarse architecture was noted with increased portal markings and minor parenchymal remodeling is suggestive of an inflammatory component. Mild lobar, biliary mineralization was noted in the liver. Small gallbladder calculi were noted and non-obstructive. Grouping of calculi measured 2.0 cm.

REFERRING VET

Dr. Maniar

Gastrointestinal

INVOICE

91687

Examination of the **gastrointestinal tract** revealed a stomach and intestine free of stasis, of normal wall thickness, acceptable curvilinear mural detail, and peristaltic activity. There was some minor retention of ingesta was noted in the stomach. Small and large intestine demonstrated normal luminal chyme and stool consistency respectively. No obstructive or overt infiltrative disease was noted. No associated abnormal lymphatic activity was noted.

DATE

9/7/21



PATIENT

Pancreas

Zero Diggs

The base and limbs of the **pancreas** were observed to be largely isoechoic to surrounding omental fat. Pancreatic duct and capsular contour were acceptably normal and parenchyma respected normal curvilinear patterns. No overt evidence of active inflammatory or neoplastic disease was noted.

SPECIES

Canine

ULTRASONOGRAPHIC FINDINGS

BREED

Husky Mix

Benign hepatopathy with biliary calculi, non-obstructive.

SEX

Spayed Female

INTERPRETATION OF THE FINDINGS & FURTHER RECOMMENDATIONS

Ursodiol therapy is recommended over the next 6-8 weeks. The liver presentation is likely owing to steroid use. A recheck sonogram is recommended at that time.

AGE

4 years

WEIGHT

109 lbs

INTERPRETED BY

Eric Lindquist, DMV
DABVP, Cert. IVUSS

IMAGING PERFORMED BY

Jenn

HOSPITAL NAME

Rockaway AH

REFERRING VET

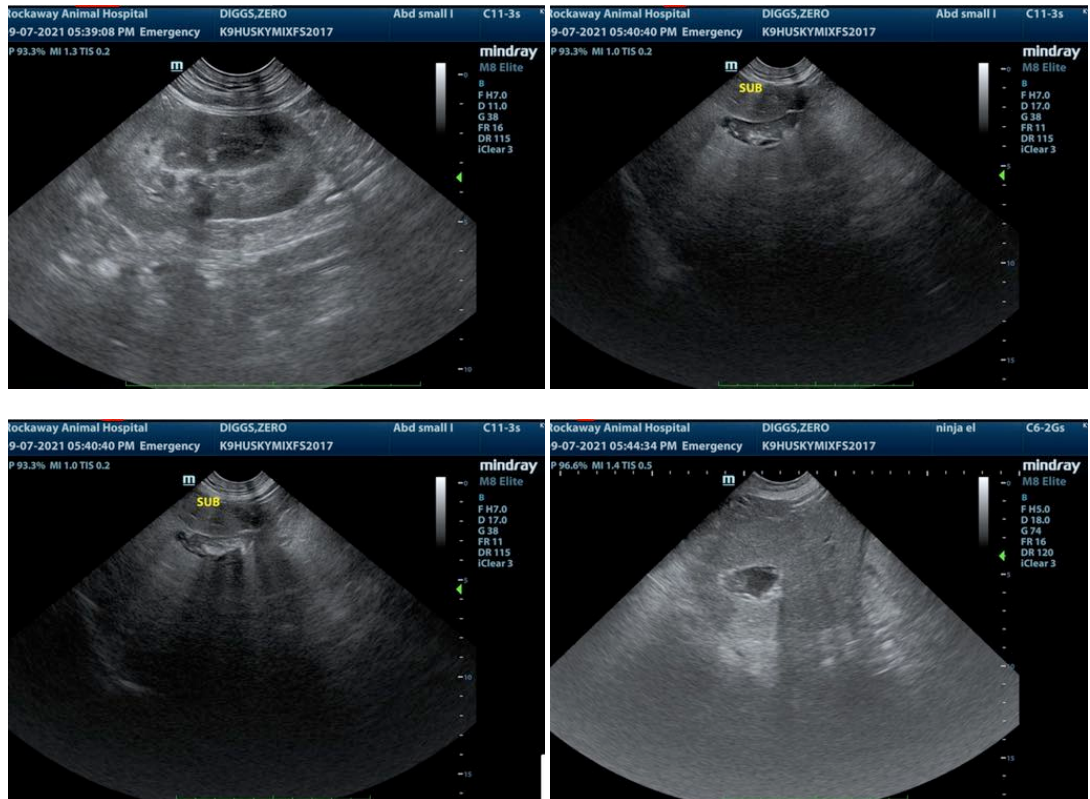
Dr. Maniar

INVOICE

91687

DATE

9/7/21



The information and recommendations provided are based on the images presented by the referring veterinarian. No evaluation can be communicated regarding pathology that was not visible in the image/video clips provided.

Thank you for this referral. If the clinical or image interpretation does not parallel your findings or if I can be of any further assistance please contact me.

Eric Lindquist, DMV, DABVP, Cert. IVUSS, CEO of SonoPath.com



PATIENT

info@SonoPath.com

Zero Diggs

SPECIES

Canine

BREED

Husky Mix

SEX

Spayed Female

AGE

4 years

WEIGHT

109 lbs

INTERPRETED BY

Eric Lindquist, DMV
DABVP, Cert. IVUSS

**IMAGING
PERFORMED BY**

Jenn

HOSPITAL NAME

Rockaway AH

REFERRING VET

Dr. Maniar

INVOICE

91687

DATE

9/7/21