



**PATIENT PRESENTING CLINICAL SIGNS**

Luna Didyk History: Echo- recommended after abd u/s last week

**SPECIES BREED SEX AGE WEIGHT INTERPRETED BY IMAGING PERFORMED BY HOSPITAL NAME REFERRING VET**

Feline

Domestic Shorthair

Spayed Female

10 years

9 lbs

Eric Lindquist, DMV  
DABVP, Cert. IVUSS

Jessica Miller, RDMS

Newton VH

Dr. Wyman Greenwald

**ULTRASONOGRAPHIC EXAMINATION OF THE HEART**

The echocardiogram in this patient demonstrated normal **left atrial** size based on 3 separate LA measurements. The cranial and caudal **mitral** valve leaflets presented normal linear structure and kinetics.. The **left ventricle** presented normal thicknesses with linear contour and was not dilated nor restricted. The **myocardium** presented normal echogenicity without subjective evidence of significant fibrotic or ischemic disease. **Contractility** of the ventricular walls was adequate and in normal range for this patient evidenced by the fractional shortening measurement and subjective evaluation of the different regions and angles of the myocardium. The **left ventricular outflow** tract demonstrated normal laminar flow and subjective structural integrity. The **right atrium** and auricle revealed normal size, structure and content. No evidence of masses was noted or chamber overload. Trivial **tricuspid** insufficiency was noted at 1.5 m/sec. The **right ventricle** was of normal size (1/3 diameter of LV), chordae structure, myocardial echogenicity and thickness. **Pulmonic** tract assessment revealed normal valve structure, laminar flow, and diameter (approx.1:1 pa/ao ratio). Trace **pericardial** effusion was noted with multi-focal, comet tail lung lesions.

FELINE CARDIAC PARAMETERS	BODY WEIGHT (kg)	HR (BPM)	IVSd (cm)	LVIDd (cm)	LVWd (cm)	FS (%)	EF (%)
NORMAL PARAMETER	-----	150-240	0.3-0.6	1.0-2.1	0.25-0.6	35-67	80-100
PATIENT		220	0.29	1.44	0.3	67	95
FELINE CARDIAC PARAMETERS	LA/AO (Boon)	LA/AO HEART BASE (Sisson)	LA 2D 4-chamber long axis AS to FW (Sisson) (cm)	LVOT VEL. (m/s)	RVOT VEL. (m/s)	IVRT (m/)	
NORMAL PARAMETER	<1.5	0.88-1.79	0.7-1.7	<1.6	<1.3	40-60	
PATIENT	1.07	1.1	1.2	1.0	0.8	NM	

Adapted from June Boon, Veterinary Echocardiography, 1998  
Sisson D et al. JVIM 1991; 5: 232, Jacobs et al. Am J Vet Res 1985; 46:1705

**ULTRASONOGRAPHIC FINDINGS**

Normal echocardiogram with slight, comet tail lung lesions and trace pericardial effusion.

91679

**INTERPRETATION OF THE FINDINGS & FURTHER RECOMMENDATIONS**

DATE

9/7/21

There is no evidence of significant pathology. Full thickness intestinal and lymph node biopsies would be ideal in this patient or FNA of the spleen and lymph nodes if accessible by the sonographer. However, if



**PATIENT**

no sampling is an option then a clinical trial of the following may prove effective from a palliative standpoint. However, this may be suppressing an underlying lymphoma.

Luna Didyk

**Triaditis/Pancreatitis protocol**

**SPECIES**

Part or all of this protocol may be considered based on your clinical impression of the patient:

Feline

Recommend pain management when anorexic with **Buprenorphine** (0.01-0.02 mg/kg IM or SC), clinical trial of **Zithromax** (50 mg sid/cat x 10 days, 3 weeks if bartonella +), **Prednisolone** (0.5-2 mg/kg tapering over 1 week to minimal effective dose), and **B12 injections** if weight loss (Cyanobalamine 250 mcg sub-q once-weekly x six weeks, then every other week for six weeks and then once-monthly, long-term if necessary), **novel-protein or hydrolyzed diet** (*Hydrolyzed diets have been shown to be more effective in dietary intolerance case management compared to hypoallergenic diets*) or the **magical Purina DM** (changing protein source is crucial and may need rotation every 6 months if clinical signs recur) Diet trials is a whatever works phenomenon. If vomiting becomes a persistent issue then endoscopy would be warranted and/or recheck sonogram to assess more emerging disease. One diet does not work for all patients so different trials may be necessary or protein source rotation every 6 months as new sensitivities develop.

**BREED**

Domestic Shorthair

**SEX**

Spayed Female

**AGE**

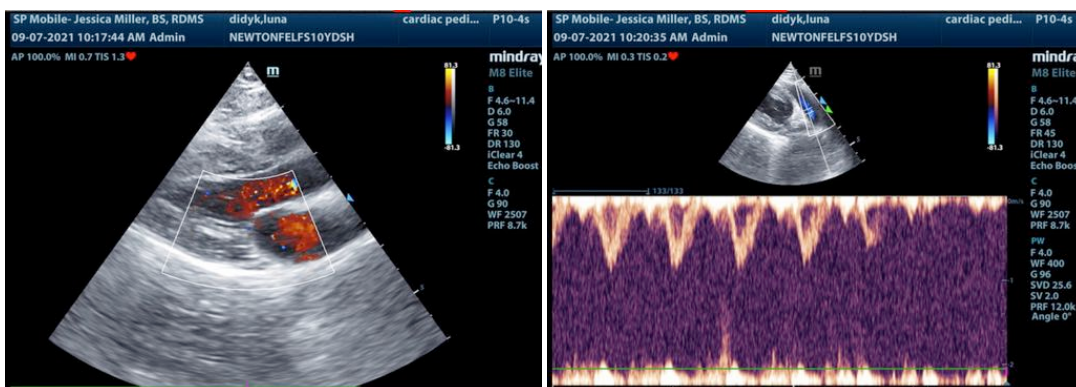
10 years

**WEIGHT**

9 lbs

**INTERPRETED BY**

Eric Lindquist, DMV  
DABVP, Cert. IVUSS



**IMAGING PERFORMED BY**

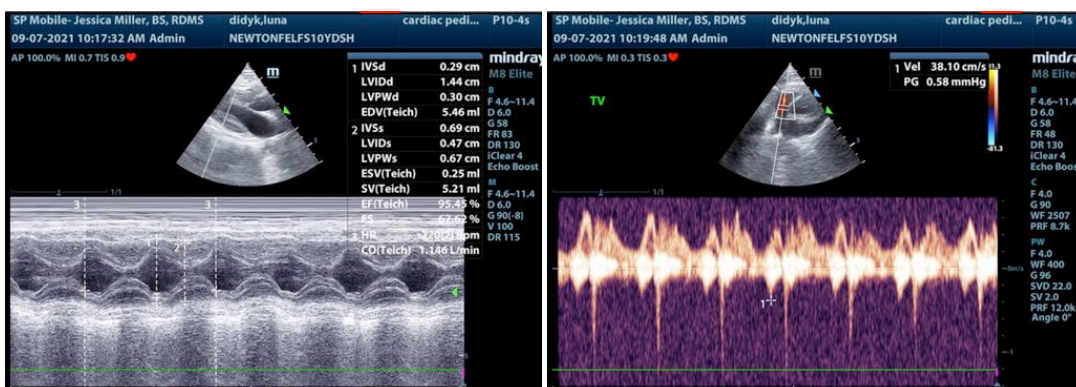
Jessica Miller, RDMS

**HOSPITAL NAME**

Newton VH

**REFERRING VET**

Dr. Wyman Greenwald



**INVOICE**

91679

**DATE**

9/7/21



**PATIENT**

Luna Didyk

**SPECIES**

Feline

**BREED**

Domestic Shorthair

**SEX**

Spayed Female

**AGE**

10 years

**WEIGHT**

9 lbs

**INTERPRETED BY**

Eric Lindquist, DMV  
DABVP, Cert. IVUSS

**IMAGING PERFORMED BY**

Jessica Miller, RDMS

**HOSPITAL NAME**

Newton VH

**REFERRING VET**

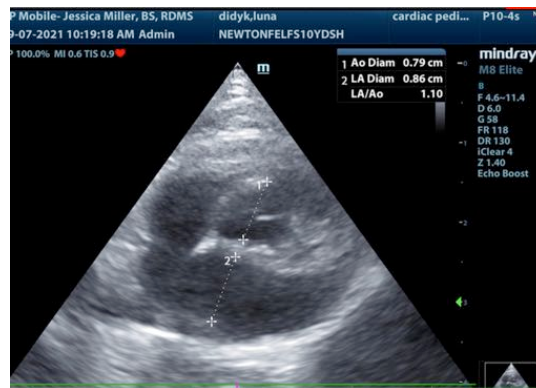
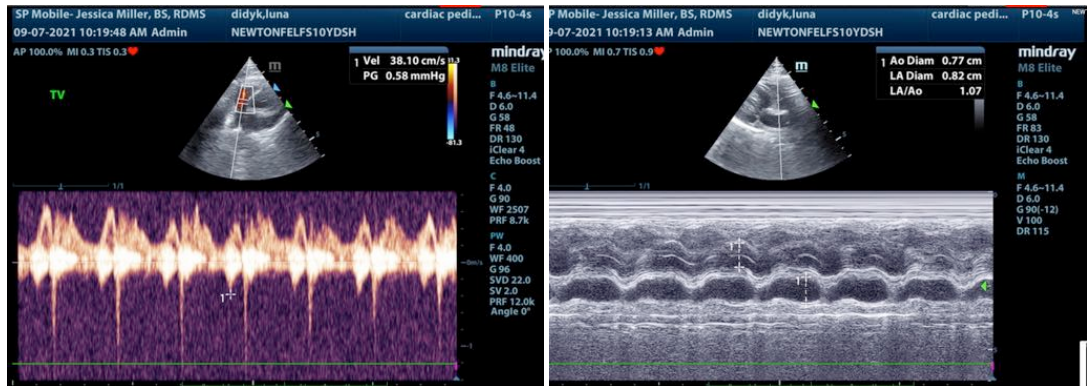
Dr. Wyman Greenwald

**INVOICE**

91679

**DATE**

9/7/21



The information and recommendations provided are based on the images presented by the referring veterinarian. No evaluation can be communicated regarding pathology that was not visible in the image/video clips provided.

Thank you for this referral. If the clinical or image interpretation does not parallel your findings or if I can be of any further assistance please contact me.

**Eric Lindquist**, DMV, DABVP, Cert. IVUSS, CEO of SonoPath.com  
info@SonoPath.com