

IMAGING PERFORMED BY

IntraPet.com



SonoPath

Clinical Sonography & Telectology

EDUCATIONAL TELECONSULTATION SERVICES™

1-800-838-4268 info@sonopath.com SonoPath.com

DATE PRESENTING CLINICAL SIGNS

9/7/21 History: Losing weight/ incontinence.
Date of Previous IntraPet Ultrasound: No previous.
PATIENT Sedation: Telazol IV.
Baron Cuddington Stat Report: Not requested.

ULTRASONOGRAPHIC EXAMINATION OF THE ABDOMEN

SPECIES Urinary System

Canine The **urinary bladder**, trigone, and pelvic urethra presented normal thicknesses and normal tone. The ureters were not visible which is normal. No uroliths or sediment were visualized and anechoic urine was present. No evidence of inflammatory or neoplastic changes were noted. Ureteral papillae were normal. The residual prostate was uniform at 0.84 cm.

BREED

Hound The **kidneys** revealed largely normal size and structure, corticomedullary definition and ratio (cortex 1/3 of medulla) were essentially maintained with some age-related loss of curvilinear patterns regarding the capsule and C/M junction. The cortices presented largely uniform texture with some increased echogenicity expected for his age patient. Medullary structure differed distinctly from that of the cortex and no evidence of pelvic dilation was present. The right kidney measured 6.17 cm. An anechoic cyst measuring 0.85 cm was present in the cranial pole of the left kidney.

SEX

Neutered Male

AGE

2007

WEIGHT

32.5 Pounds

Adrenal Glands

The **right adrenal gland** was visualized and recognized as having largely normal shape, size, position and acceptable echogenicity for this age group and breed. Some heterogeneity was noted within the adrenal parenchyma without concerning capsular distortion. These changes are likely age related but should be monitored by sonogram should the patient be suspected of having adrenal disease. The right adrenal gland measured 2.86 cm x 0.62 cm at the caudal pole and 0.67 cm at the cranial pole.

INTERPRETED BY

Eric Lindquist, DMV
DABVP, Cert. IVUSS

The **left adrenal gland** was mildly enlarged, measuring 3.21 cm x 1.1 cm at the cranial pole and 0.82 cm at the caudal pole. Capsular expansion noted without capsular escape or vascular invasion.

HOSPITAL NAME

Padonia Vet Hospital

Spleen

The **spleen** was folded upon itself caudally owing to the gastric overdistention. The spleen was largely smooth with subtle heterogeneous parenchymal changes while maintaining normal echogenic relationship to the liver and kidney. These changes are consistent with normal age-related alteration. The capsule was smooth without noticeable impingement from within the spleen or from pathology in the adjacent abdomen. The splenic vasculature demonstrated normal volume without signs of congestion or significant contraction. No evidence of active acute or chronic inflammatory, neoplastic, or infarctual changes were noted.

REFERRING VET

Dr. Youssef

Liver

INVOICE

25226

An anechoic microcystic nodule was noted, measuring 1.5 cm in the left **liver**. The remainder of the liver was unremarkable. The gallbladder was unremarkable.

Gastrointestinal

The **stomach** was filled with ingesta, obscuring complete visibility of the gastric wall. The small intestine and colon were unremarkable.

Pancreas

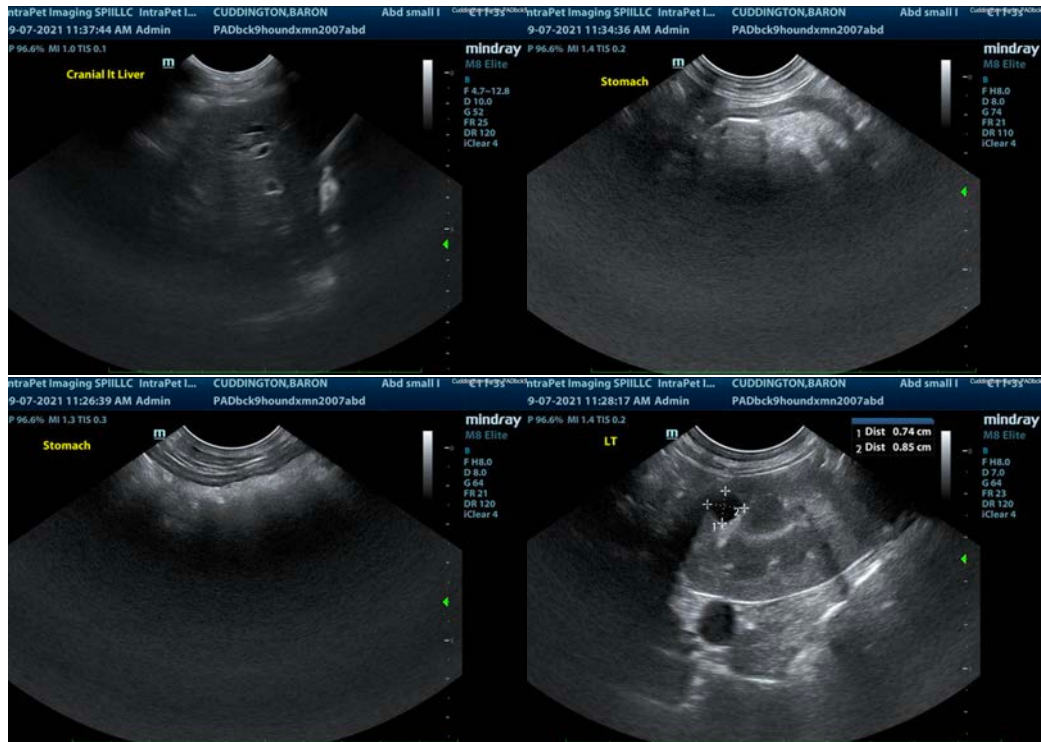
The base and limbs of the **pancreas** were observed to be largely isoechoic to surrounding omental fat. Pancreatic duct and capsular contour were acceptably normal and parenchyma respected normal curvilinear patterns. No overt evidence of active inflammatory or neoplastic disease was noted.

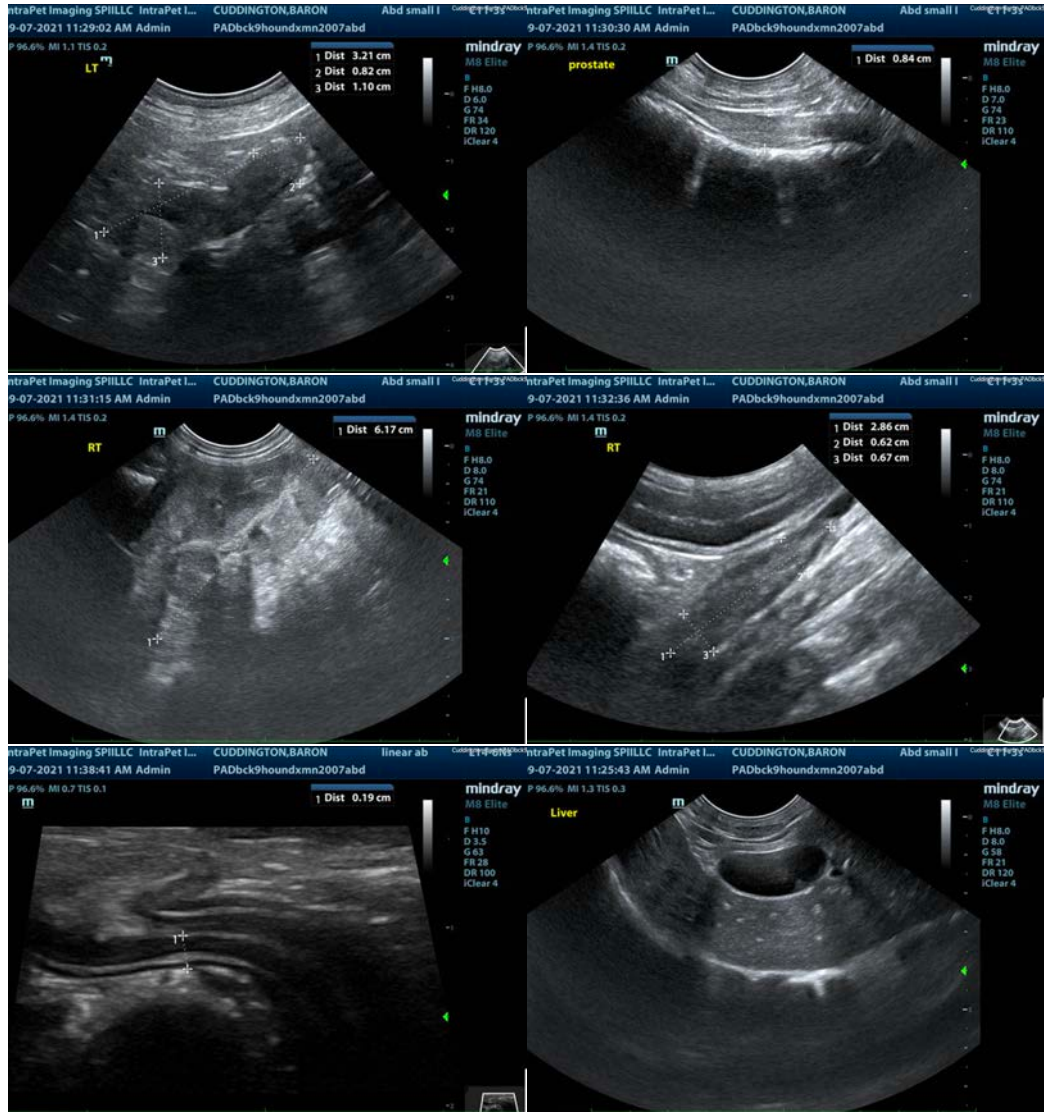
ULTRASONOGRAPHIC FINDINGS

- Hyperplastic left adrenal gland – likely benign hyperplasia, possibility of emerging carcinoma, pheochromocytoma less likely.
- Delayed outflow gastric pattern

INTERPRETATION OF THE FINDINGS & FURTHER RECOMMENDATIONS

Serial blood pressures warranted. If hypertension is present, urine catecholamine would be warranted to assess for pheochromocytoma of the left adrenal. However, this may be a benign change. Feeding history should be evaluated. Some of the material in the stomach could be consistent with foreign matter, yet was minor. The majority was ingesta related. 24-hour NPO and recheck sonogram would be ideal to allow for dissipation of the gastric artifact.





The information and recommendations provided are based on the images presented by the referring veterinarian. No evaluation can be communicated regarding pathology that was not visible in the image/video clips provided.

Thank you for this referral. If the clinical or image interpretation does not parallel your findings or if I can be of any further assistance please contact me.

Eric Lindquist, DMV, DABVP, Cert. IVUSS, CEO of SonoPath.com
info@SonoPath.com