

**DATE PRESENTING CLINICAL SIGNS**

9/5/21

Noisy/Loud Breathing. Diarrhea. Vomiting.

PATIENT

Annie Crisafulli

History: Date: 09-04-2021 Notes: poor appetite over the past couple of weeks - with episodes of abnormal panting took to RDVM on Monday- outpatient with SQ fluids, cerenia, convenia -sent home with metronidazole that the owner has not been able to get in still has poor appetite still vomiting getting worse this morning- abnormal breathing, lethargy treated for pancreatitis in 4/2021 presumed heart attack in 2/2021

SPECIES

Canine

Current Medications: ampicillin/sublactam, baytril, maropitant, protonix, buprenorphine

BREED

Beagle Mix

Lab Results: attached

Radiographs: Whole Body 2 view: increased soft tissue density in the cranial abdomen- intestines are deviated caudally possible sternal lymph node enlargement.

SEX

Spayed Female

Sedation: not needed

Stat Report: not requested

AGE

2007

ULTRASONOGRAPHIC EXAMINATION OF THE ABDOMEN**Urinary System**

The **urinary bladder**, trigone, and pelvic urethra presented normal thicknesses and normal tone. The ureters were not visible which is normal. No uroliths or sediment were visualized and anechoic urine was present. No evidence of inflammatory or neoplastic changes was noted. Ureteral papillae were normal.

INTERPRETED BYEric Lindquist, DMV
DABVP, Cert. IVUSS

The **kidneys** revealed largely normal size and structure, corticomedullary definition and ratio (cortex 1/3 of medulla) were essentially maintained with some age-related loss of curvilinear patterns regarding the capsule and C/M junction. The cortices presented largely uniform texture with some increased echogenicity expected for this age patient. Medullary structure differed distinctly from that of the cortex. The left kidney measured 5.74 cm with pyelectasia that measured 0.29 cm. The right kidney measured 5.1 cm.

HOSPITAL NAMEAnimal Emergency
Hospital**Adrenal Glands**

Both **adrenal glands** were visualized and recognized as having normal shape, size, position and echogenicity for this breed. The phrenic vasculature, glandular echogenicity and detail were unremarkable. Capsule, cortex, and medullary definition were normal for this age patient. The left adrenal gland measured 2.32 x 0.73 cm at the caudal pole and 0.64 cm at the cranial pole. The right adrenal gland measured 2.03 x 0.58 cm at the caudal pole and 0.53 cm at the cranial pole.

REFERRING VET

Dr. Willer

Spleen

The **spleen** was expansive with multi-focal, hypoechoic nodules and disruptive architecture. Regional inflammation was noted around the splenohepatic pathology.

INVOICE

91652

Liver

The **liver** was riddled with multiple, mixed echogenic, expansive masses. The largest liver mass measured 8.7 x 7.7 cm. The gallbladder presented acceptably thin walls with primarily anechoic content. The cystic and common bile ducts were normal.

Gastrointestinal

Examination of the gastric wall was thickened with loss of detail measuring 1.0 cm. The remainder of the **gastrointestinal tract** was free of stasis, of normal wall thickness, acceptable curvilinear mural detail, and peristaltic activity. Small and large intestine demonstrated normal luminal chyme and stool consistency respectively.

Pancreas

The base and limbs of the **pancreas** were observed to be largely isoechoic to surrounding omental fat. Pancreatic duct and capsular contour were acceptably normal and parenchyma respected normal curvilinear patterns. No overt evidence of active inflammatory or neoplastic disease was noted.

Free Abdomen

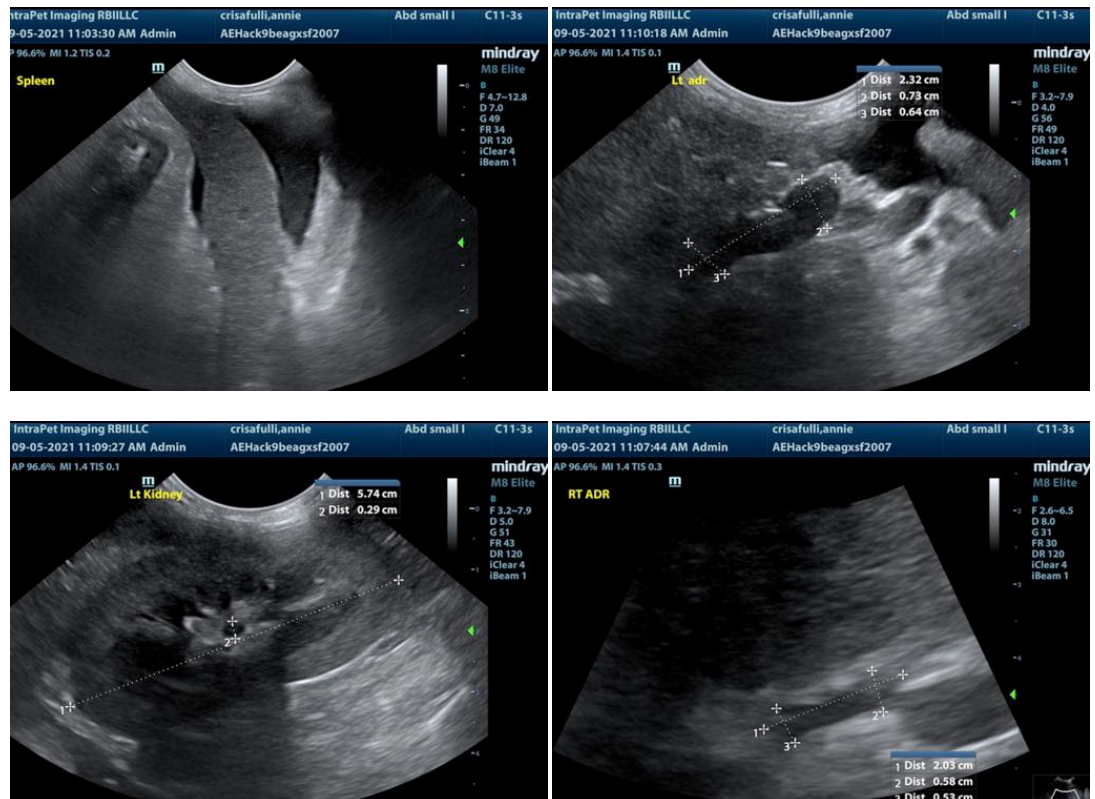
Free fluid was noted in the caudal abdomen adjacent to the spleen.

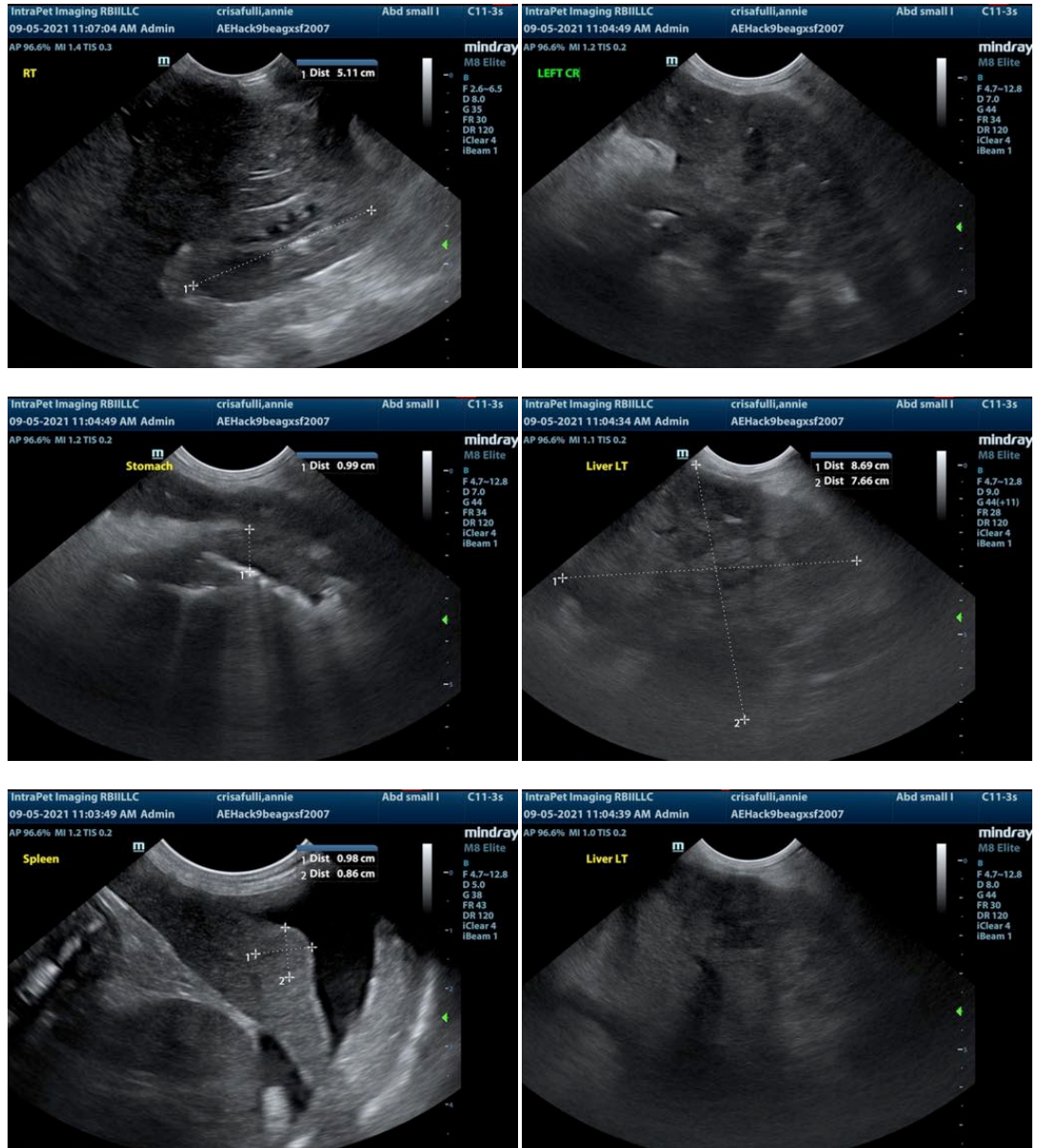
ULTRASONOGRAPHIC FINDINGS

Splenohepatic neoplasia with secondary free fluid. Round cell neoplasia and hemangiosarcoma is suspected. Unremarkable gallbladder.

INTERPRETATION OF THE FINDINGS & FURTHER RECOMMENDATIONS

Humane euthanasia should be considered in this patient.





The information and recommendations provided are based on the images presented by the referring veterinarian. No evaluation can be communicated regarding pathology that was not visible in the image/video clips provided.

Thank you for this referral. If the clinical or image interpretation does not parallel your findings or if I can be of any further assistance please contact me.

Eric Lindquist, DMV, DABVP, Cert. IVUSS, CEO of SonoPath.com
 Eric.Lindquist@SonoPath.com