

**DATE PRESENTING CLINICAL SIGNS**

9/30/22

Sweetie Pie will have been on the urinary dissolution diet (Hills c/d) for 4 weeks at the time of the ultrasound and we are looking to see if the calculi/sand stones have dissolved and also if the bladder wall thickness has improved.

PATIENT

Sweetie Pie Ward

Current Medications: Hills c/d multicare

Lab Results: no other diagnostics performed since last u/s.

Date of Previous IntraPet Ultrasound: 8/30/22. See attached.

Sedation: Not required to complete full diagnostic ultrasound.

Stat Report: Not requested.

SPECIES

Feline

BREED

DSH

LIMITED ULTRASONOGRAPHIC EXAMINATION

The **urinary bladder** presented largely normal wall thickness with minor micropolypoid changes. Trace amount of dependent debris noted, yet no sand or overt calculi noted in the bladder itself.

SEX

Spayed Female

The **kidneys** presented normal size and contour with minor increased cortical echogenicity.

Corticomedullary definition and renal pelvises were unremarkable. Degenerative changes were considered mild. Slight pinpoint mineralizations noted in both kidneys. The right kidney measured 3.82 cm.

AGE

7/8/12

ULTRASONOGRAPHIC FINDINGS

- Minor residual polypoid bladder changes with minor debris
- Minor degenerative renal changes – expected for this age patient.

WEIGHT

11.75 Pounds

INTERPRETATION OF THE FINDINGS & FURTHER RECOMMENDATIONS**INTERPRETED BY**Eric Lindquist, DMV
DABVP, Cert. IVUSS

Near complete resolution of the urinary tract present. No further therapy warranted if no residual inflammatory sediment present on urinalysis.

IMAGING PERFORMED BY

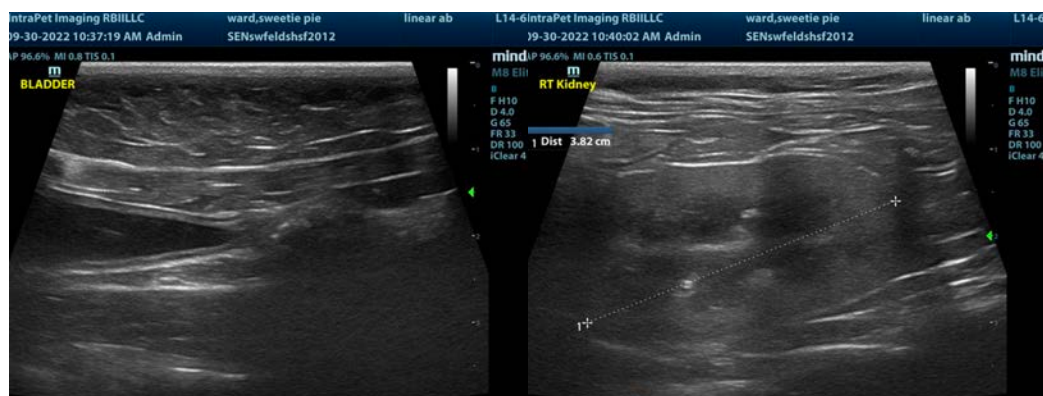Rachel Brilhart RDMS

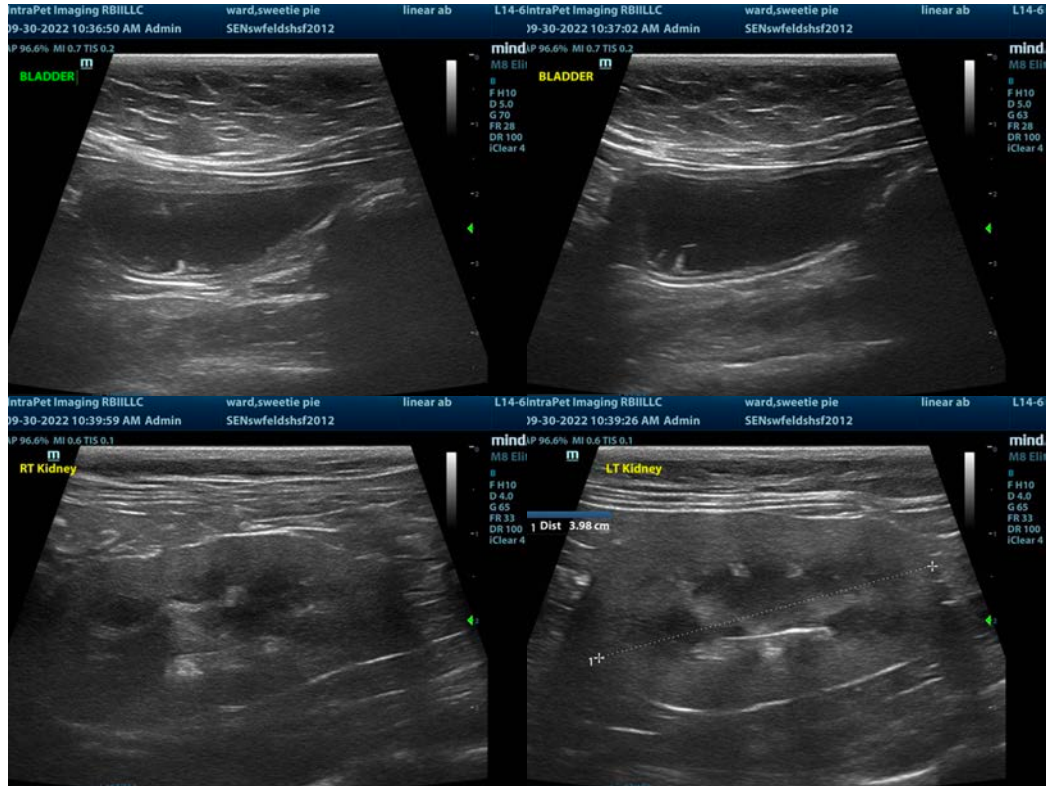
HOSPITAL NAMECat Sense Feline
Hospital**REFERRING VET**

Dr. Sinclair

INVOICE

41823





The information and recommendations provided are based on the images presented by the referring veterinarian/sonographer. No evaluation can be communicated regarding pathology that was not visible in the image/video clips provided.

Thank you for this referral. If the clinical or image interpretation does not parallel your findings or if I can be of any further assistance please contact me.

Eric Lindquist, DMV, DABVP, Cert. IVUSS, CEO of SonoPath.com
info@SonoPath.com