

**DATE**

9/30/22

PRESENTING CLINICAL SIGNS

History: Porcha was presented on 8/20/22 for evaluation of a mass on the right hind thigh. Cytology revealed likely Mast Cell Tumor.

PATIENT

Porcha Nolan

Current Medications: Diphenhydramine 50 mg PO BID started on 9/1/2022. Iverhart Plus and Advantage monthly. Dasuquin Advanced daily.

SPECIES

Canine

Lab Results: Cytologic Findings: Mast Cell Tumor.

Date of Previous IntraPet Ultrasound: No previous.

Sedation: Not required to complete full diagnostic ultrasound.

Stat Report: Not requested.

BREED

Dalmation

Imaging Performed By: Rachel Brillhart, RDMS.

ULTRASONOGRAPHIC EXAMINATION OF THE ABDOMEN**SEX**

Spayed Female

Urinary System

The **urinary bladder**, trigone, and pelvic urethra presented normal thicknesses and normal tone. The ureters were not visible which is normal. No uroliths or sediment were visualized and anechoic urine was present. No evidence of inflammatory or neoplastic changes were noted. Ureteral papillae were normal. The iliac lymph nodes were unremarkable.

AGE

12/2/12

The **kidneys** revealed normal size and structure, corticomedullary definition and ratio for this age. The cortices presented largely uniform texture with normal echogenic relationship to liver and spleen. Medullary structure differed distinctly from the cortex and no evidence of pelvic dilation was present. The capsules were acceptably uniform without significant irregularities. The left kidney measured 7.4 cm. The right kidney measured 6.3 cm. Hyperechoic medullary rim sign was noted in both kidneys, idiopathic.

WEIGHT

71.5 Pounds

Adrenal Glands

Both **adrenal glands** were visualized and recognized as having normal shape, size, position and echogenicity for this breed. The phrenic vasculature, glandular echogenicity and detail were unremarkable. Capsule, cortex, and medullary definition were normal for this age patient. The left adrenal gland measured 3.03 cm x 0.78 cm at the caudal pole and 0.74 cm at the cranial pole.

INTERPRETED BYEric Lindquist, DMV
DABVP, Cert. IVUSS**HOSPITAL NAME**

Bel Air VH

Spleen

The **spleen** revealed subtle micronodular changes and minor scalloping contour. Caudal folding of the spleen was noted.

REFERRING VET

Dr. Young

Liver

The **liver** images submitted revealed subjectively normal liver size, contour, and structure. Parenchymal echogenicity was naturally coarse and hypoechoic to the spleen. Vascular and biliary tracts were of normal volume with no evidence of congestion. The gallbladder presented acceptably thin walls with primarily anechoic content. The cystic and common bile ducts were normal. No pathological hepatic lymphadenopathy was evident. No overt structural evidence of inflammatory, infiltrative or regenerative pathology was evident.

INVOICE

17510

Gastrointestinal

Examination of the **gastrointestinal tract** revealed a stomach and intestine free of stasis, of normal wall thickness, acceptable curvilinear mural detail, and peristaltic activity. Small and large intestine demonstrated normal luminal chyme and stool consistency respectively. No obstructive or overt infiltrative disease was noted. No associated abnormal lymphatic activity was noted.

Pancreas

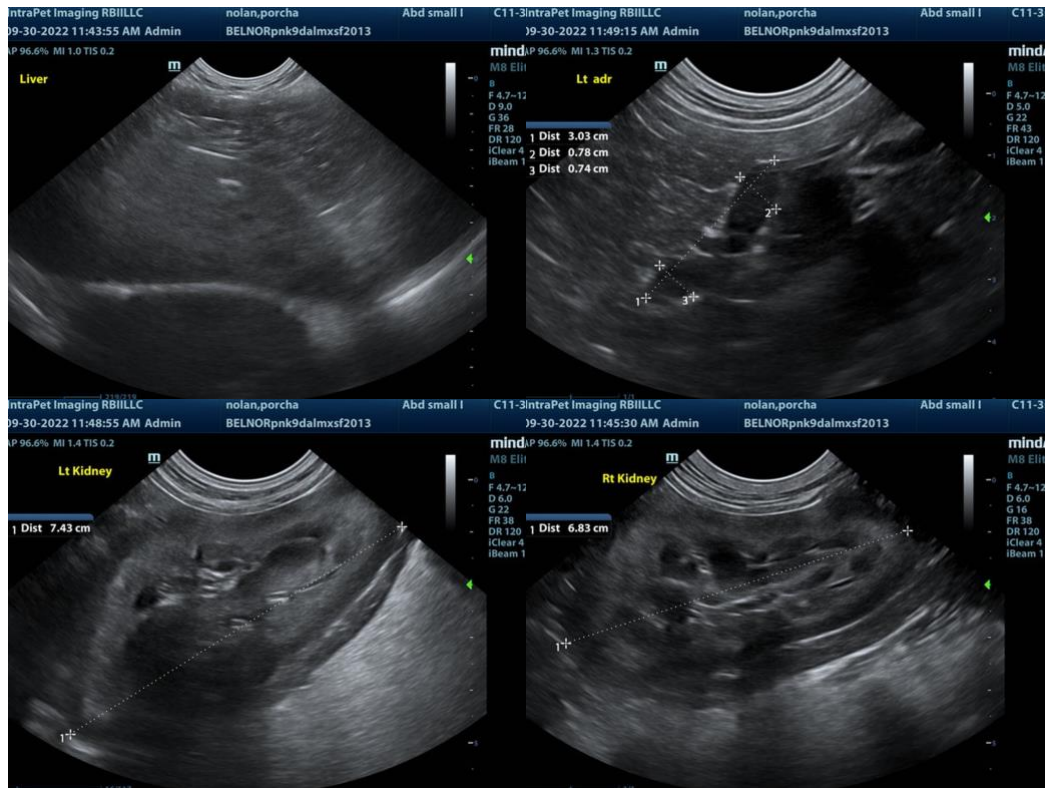
The base and limbs of the **pancreas** were observed to be largely isoechoic to surrounding omental fat. Pancreatic duct and capsular contour were acceptably normal and parenchyma respected normal curvilinear patterns. No overt evidence of active inflammatory or neoplastic disease was noted.

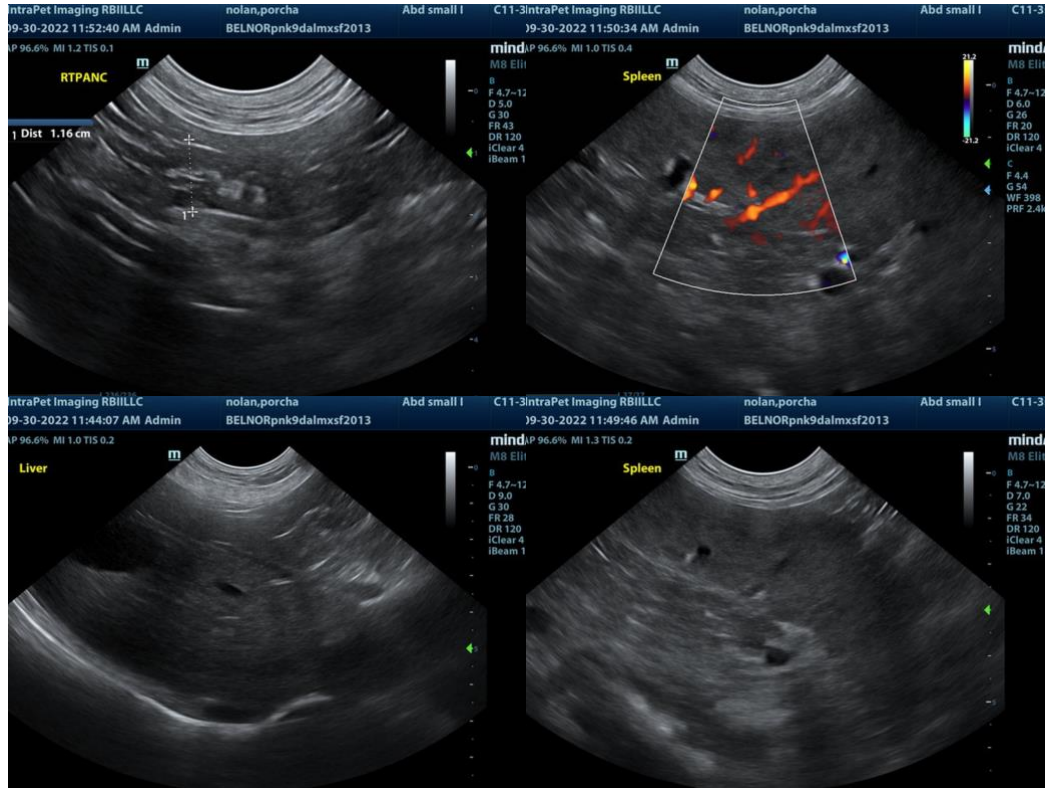
ULTRASONOGRAPHIC FINDINGS

- Micronodular hyperplasia splenic pattern.
- Idiopathic medullary rim kidneys

INTERPRETATION OF THE FINDINGS & FURTHER RECOMMENDATIONS

Regarding the spleen, given the patient history, FNA is warranted to ensure mast cell disease is not an issue in this organ. However, no overt suspicion of neoplasia.





The information and recommendations provided are based on the images presented by the referring veterinarian. No evaluation can be communicated regarding pathology that was not visible in the image/video clips provided.

Thank you for this referral. If the clinical or image interpretation does not parallel your findings or if I can be of any further assistance please contact me.

Eric Lindquist, DMV, DABVP, Cert. IVUSS, CEO of SonoPath.com
info@SonoPath.com