

**DATE**

9/30/22

PRESENTING CLINICAL SIGNS

History: Baby girl, F, 4, dachshund mix PC: potential FB, referral ATO in room: - hasn't eaten in 3-4 days - temp at RDVM 103-104 O unsure - saw blockage in stomach- O says it was gas or pyometra - no other diagnostics were performed at RDVM - diarrhea for 3-4 days with blood in it - Monday ingested/ bit into pork bone that was boiled - gassy on ride here

PATIENT

Baby Girl Beaudette

SPECIES

Canine

BREED

Dachshund Mix

Current Medications: Provable, Metronidazole, Protonix, Ondansetron, Buprenorphine.

Lab Results: See attached.

Radiographs: NSF.

Date of Previous IntraPet Ultrasound: No previous.

Sedation: Not required to complete full diagnostic ultrasound.

Stat Report: Not requested.

Imaging Performed By: Rachel Brillhart, RDMS.

SEX

Intact Female

ULTRASONOGRAPHIC EXAMINATION OF THE ABDOMEN**AGE**

6/15/18

Urinary System

The **urinary bladder**, trigone, and pelvic urethra presented normal thicknesses and normal tone. The ureters were not visible which is normal. No uroliths or sediment were visualized and anechoic urine was present. No evidence of inflammatory or neoplastic changes were noted. Ureteral papillae were normal.

WEIGHT

12.5 Pounds

The **kidneys** revealed normal size and structure, corticomedullary definition and ratio for this age. The cortices presented largely uniform texture with normal echogenic relationship to liver and spleen. Medullary structure differed distinctly from the cortex and no evidence of pelvic dilation was present. The capsules were acceptably uniform without significant irregularities. The right kidney measured 4.6 cm. The left kidney measured 4.6 cm.

INTERPRETED BY

Eric Lindquist, DMV
DABVP, Cert. IVUSS

Adrenal Glands

Both **adrenal glands** were visualized and recognized as having normal shape, size, position and echogenicity for this breed. The phrenic vasculature, glandular echogenicity and detail were unremarkable. Capsule, cortex, and medullary definition were normal for this age patient. The left adrenal gland measured 2.14 cm x 0.55 cm at the caudal pole and 0.65 cm at the cranial pole. The right adrenal gland measured 1.85 cm x 0.53 cm at the caudal pole and 0.57 cm at the cranial pole.

HOSPITAL NAME

Animal Emergency
Hospital

Spleen

The **spleen** presented a smooth homogeneous parenchyma hyperechoic to liver and renal cortical parenchyma. The capsule was smooth without noticeable expansion or deviation from within the spleen or adjacent pathology. The splenic vasculature demonstrated normal volume without signs of congestion or thrombosis. No sonographic evidence of acute or chronic inflammatory, neoplastic, or infarctual changes were noted.

REFERRING VET

Dr. Nacke-Horney

Liver

The **liver** images submitted revealed subjectively normal liver size, contour, and structure. Parenchymal echogenicity was naturally coarse and hypoechoic to the spleen. Vascular and biliary tracts were of normal volume with no evidence of congestion. The gallbladder presented acceptably thin walls with primarily anechoic content. The cystic and common bile ducts were normal. No pathological hepatic lymphadenopathy was evident. No overt structural evidence of inflammatory, infiltrative or regenerative pathology was evident.

INVOICE

17500

Gastrointestinal

Examination of the **gastrointestinal tract** revealed a stomach and intestine free of stasis, of normal wall thickness, acceptable curvilinear mural detail, and peristaltic activity. Small and large intestine demonstrated normal luminal chyme and stool consistency respectively. No obstructive or overt infiltrative disease was noted. No associated abnormal lymphatic activity was noted.

Pancreas

The **pancreas** revealed minor hyperechoic changes, consistent with remodeling and minor heterogeneous hypoechoic changes, suggestive for low grade inflammation.

Other

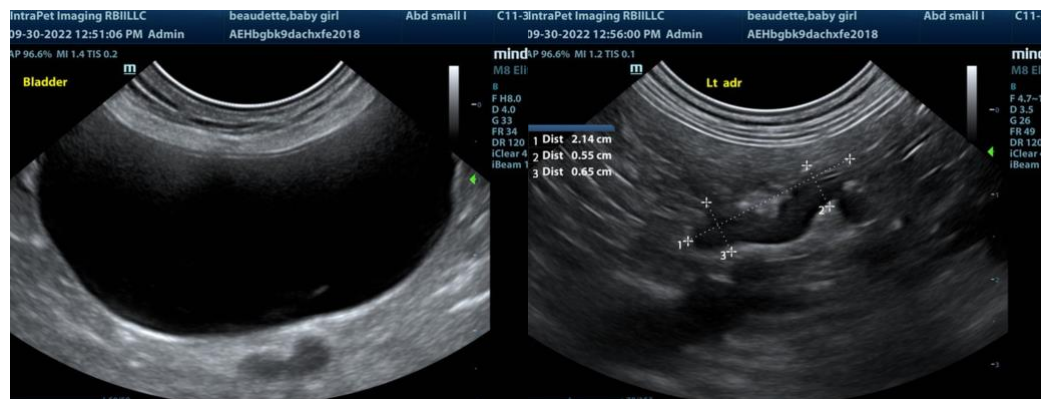
The left **ovary** was uniform, measuring 0.85 cm x 0.57 cm. The right ovary measured 1.09 cm x 0.62 cm. The uterus was dilated with fluid, measuring 0.72 cm.

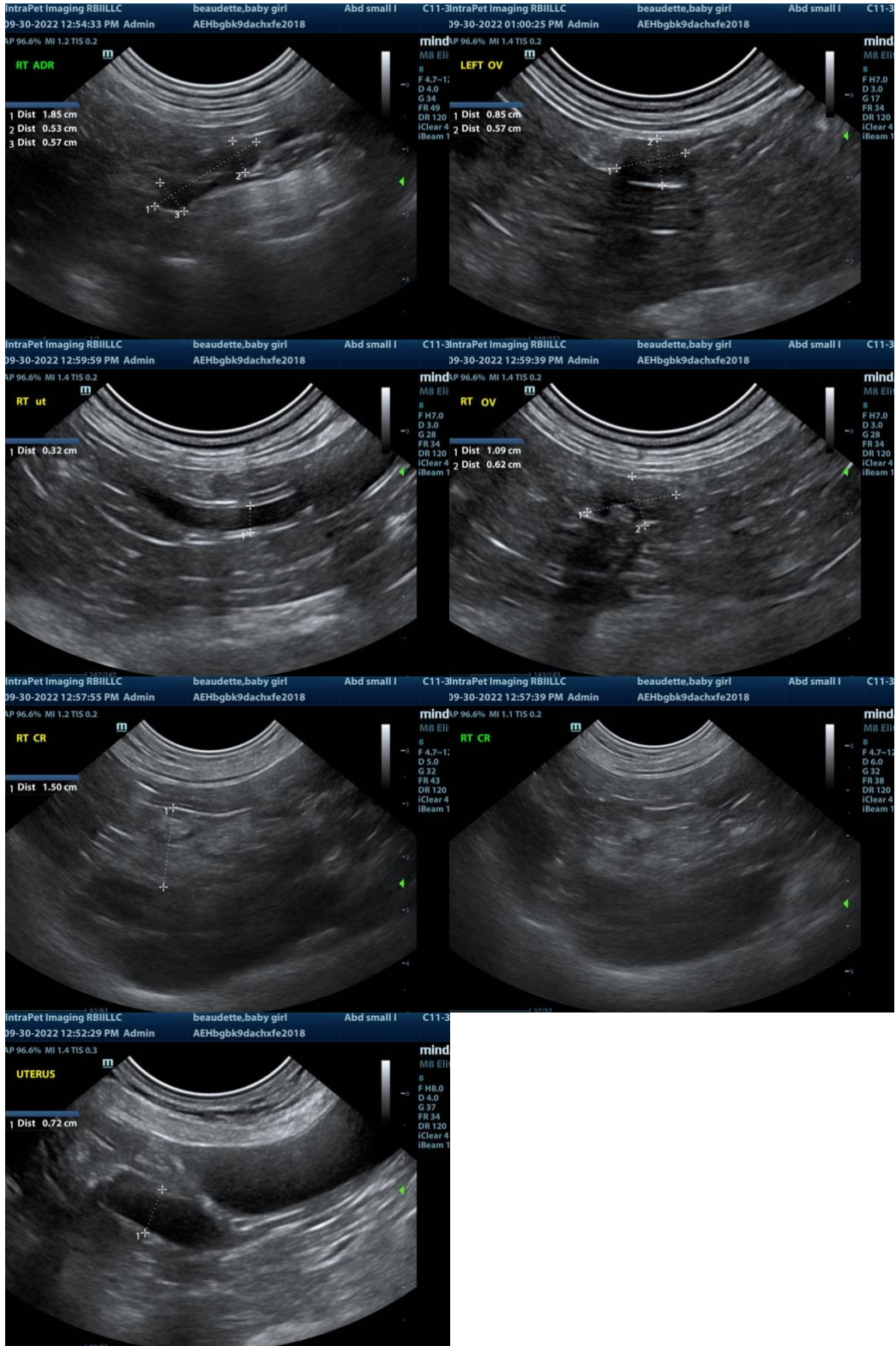
ULTRASONOGRAPHIC FINDINGS

- Mild hydrometra or pyometra
- Minor pancreatic remodeling, possible low grade pancreatitis

INTERPRETATION OF THE FINDINGS & FURTHER RECOMMENDATIONS

Ovariohysterectomy is likely in this patients best interest, however, may not be the complete cause of the clinical history. GI supportive protocol and outpatient treatment for pancreatitis is indicated. However, ovariohysterectomy would be optimal at this point. If OVH is not to be performed and only medical management is to be utilized, recheck sonogram in 48-72 hours indicated.





The information and recommendations provided are based on the images presented by the referring veterinarian. No evaluation can be communicated regarding pathology that was not visible in the image/video clips provided.

Thank you for this referral. If the clinical or image interpretation does not parallel your findings or if I can be of any further assistance please contact me.

Eric Lindquist, DMV, DABVP, Cert. IVUSS, CEO of SonoPath.com
info@SonoPath.com