



DATE
9/30/21

PRESENTING CLINICAL SIGNS

Recheck of prostatic mineralization and renal mineralization noted in July.
Current Medications: None

PATIENT

Lab Results & Radiographs: No new lab work or radiographs since previous ultrasound.

Date of Previous IntraPet Ultrasound: 07/05/2021

Sedation: not needed

Stat Report: not requested

Petey Mills

SPECIES

Canine

ULTRASONOGRAPHIC EXAMINATION OF THE ABDOMEN**Urinary System**

The **urinary bladder**, trigone, and pelvic urethra presented normal thicknesses and normal tone. The ureters were not visible which is normal. No uroliths or sediment were visualized and anechoic urine was present. No evidence of inflammatory or neoplastic changes was noted. Ureteral papillae were normal.

BREED

Boston Terrier

The prostate was uniform and regressed when compared to the prior sonogram. Slight, heterogenous parenchymal changes were noted. There was no evidence of residual pathology. The prostate measured 0.75 cm. There was no evidence of regional inflammation.

SEX

Neutered male

The **kidneys** revealed largely normal size and structure, corticomedullary definition and ratio (cortex 1/3 of medulla) were essentially maintained with some age-related loss of curvilinear patterns regarding the capsule and C/M junction. The cortices presented largely uniform texture with some increased echogenicity expected for this age patient. Medullary structure differed distinctly from that of the cortex and no evidence of pelvic dilation was present. Mild mineralization was noted in the kidneys. The right kidney measured 3.37 cm. The left kidney measured 4.18 cm.

AGE

2010

WEIGHT

15 lbs

ULTRASONOGRAPHIC FINDINGS

Further regressed prostate. No evidence of pathology.

INTERPRETED BY

Eric Lindquist, DMV
DABVP, Cert. IVUSS

INTERPRETATION OF THE FINDINGS & FURTHER RECOMMENDATIONS

No further therapy is recommended at this time.

HOSPITAL NAME

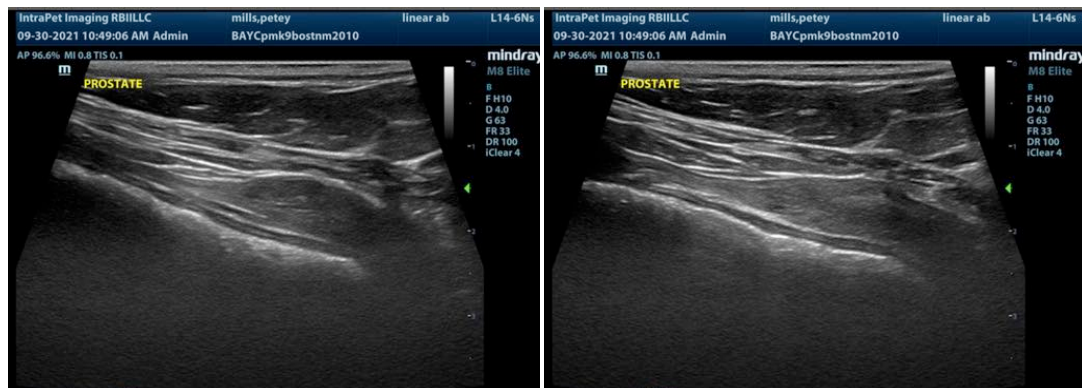
Bay Country VH

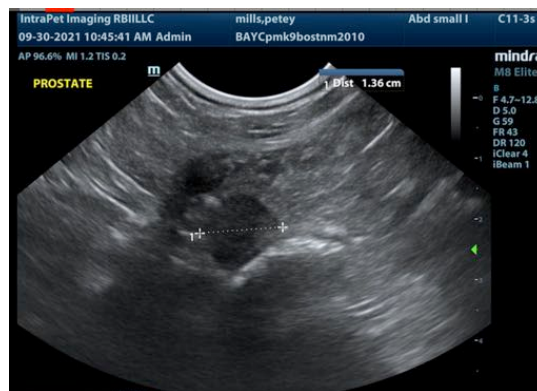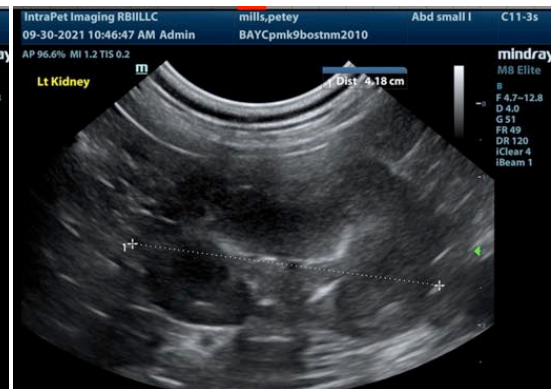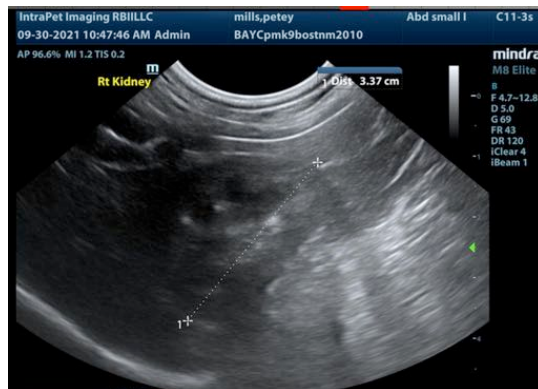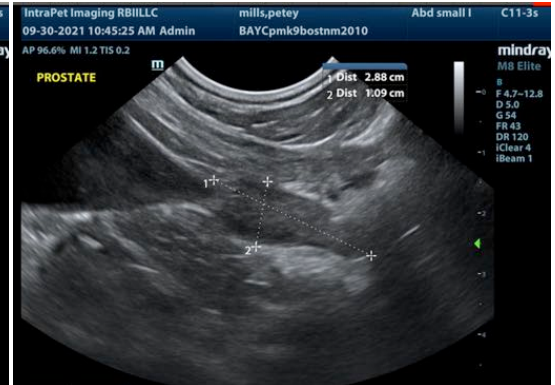
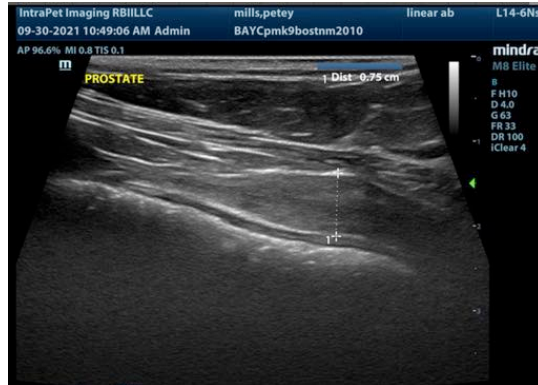
REFERRING VET

Dr. McLean

INVOICE

92117





The information and recommendations provided are based on the images presented by the referring veterinarian. No evaluation can be communicated regarding pathology that was not visible in the image/video clips provided.

Thank you for this referral. If the clinical or image interpretation does not parallel your findings or if I can be of any further assistance please contact me.

Eric Lindquist, DMV, DABVP, Cert. IVUSS, CEO of SonoPath.com
Eric.Lindquist@SonoPath.com