

PATIENT PRESENTING CLINICAL SIGNS

Atticus Finch Rose

History: Recheck AUS. History geriatric abdomen, lobar biliary calculi, renal calculi, mild pancreatic remodeling on prior AUS (6/4/18, Eric Lindquist, DVM, SonoPath). Currently, controlled asthma, IBD, hyperthyroid. Weight loss and poor appetite. Thyroid WNL Sedated with Alfaxalone.

SPECIES

Slightly panleukopenia, Specfpl 6.1 elevated vitb12 1x/monthly; tylosin 25 SID; gabapentin 12.5 mg SID; felimazole 2.5 mg BID

Feline

BREED

ULTRASONOGRAPHIC EXAMINATION OF THE ABDOMEN

Domestic Shorthair

Urinary System

SEX

The **urinary bladder**, trigone, and pelvic urethra presented normal thicknesses and normal tone. The ureters were not visible which is normal. No uroliths or sediment were visualized and anechoic urine was present. No evidence of inflammatory or neoplastic changes was noted. Ureteral papillae were normal.

Neutered Male

AGE

The **kidneys** presented a relatively uniform cortical hyperechogenicity when compared to the renal medulla, spleen and liver. No overt masses were noted. Corticomedullary definition was nebulous and the ratio favored the cortex slightly. The ureters were not visible and assumed to be normal. These changes are most consistent with chronic interstitial nephritis yet infiltrative disease could not be entirely ruled out without biopsy though neoplasia is not suspected. The right kidney revealed pyelectasia that measured 0.43 cm. The right kidney measured 4.12 cm with slight mineralization. The left kidney revealed slight pyelectasia that measured 0.16 cm and slight pelvic calculus. The left kidney measured 4.0 cm.

17 years

WEIGHT

11.3 lbs

INTERPRETED BY

Adrenal Glands

Eric Lindquist, DMV,
DABVP, Cert. IVUSS,
CEO of SonoPath.com

Both **adrenal glands** were visualized and recognized as having normal shape, size, position and echogenicity for this breed. The phrenic vasculature, glandular echogenicity and detail were unremarkable. Capsule, cortex, and medullary definition were normal for this age patient. The right adrenal gland measured 0.32 cm. The left adrenal gland measured 0.32 cm.

IMAGING PERFORMED BY

Spleen

Pamela Harrigan, RDCS

The **spleen** presented a smooth homogeneous parenchyma hyperechoic to liver and renal cortical parenchyma. The capsule was smooth without noticeable expansion or deviation from within the spleen or adjacent pathology. The splenic vasculature demonstrated normal volume without signs of congestion or thrombosis. No sonographic evidence of acute or chronic inflammatory, neoplastic, or infarctual changes was noted.

HOSPITAL NAME

Norfolk County VS

REFERRING VET

Dr. Poor

Liver

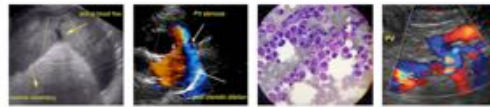
INVOICE

The **liver** was diffusely hyperechoic to the falciform fat. The gallbladder and common bile duct were unremarkable. There was no evidence of lobar biliary mineralization.

92118

DATE

9/30/21



PATIENT

Atticus Finch Rose

Gastrointestinal

SPECIES

Feline

Examination of the **gastrointestinal tract** revealed a stomach and intestine free of stasis, of normal wall thickness, acceptable curvilinear mural detail, and peristaltic activity. Small and large intestine demonstrated normal luminal chyme and stool consistency respectively. No obstructive or overt infiltrative disease was noted. No associated abnormal lymphatic activity was noted.

BREED

Domestic Shorthair

Pancreas

The **pancreas** revealed minor coarse architecture. There was no evidence of active inflammation.

SEX

Neutered Male

ULTRASONOGRAPHIC FINDINGS

Stable abdomen with chronic renal changes and mineralization, slight pyelectasia.

AGE

17 years

INTERPRETATION OF THE FINDINGS & FURTHER RECOMMENDATIONS

There was no evidence of residual hepatic or pancreatic pathology. The cause of the clinical signs is not evident. Urinary work-up is warranted if not already performed.

WEIGHT

11.3 lbs

Maldigestion panel, three view chest radiographs and full CNS examination is recommended to examine for occult disease that could be responsible for the weight loss. Evaluation for competitive eating environments should also be considered.

INTERPRETED BY

Eric Lindquist, DMV,
 DABVP, Cert. IVUSS,
 CEO of SonoPath.com

IMAGING PERFORMED BY

Pamela Harrigan, RDCS

HOSPITAL NAME

Norfolk County VS

REFERRING VET

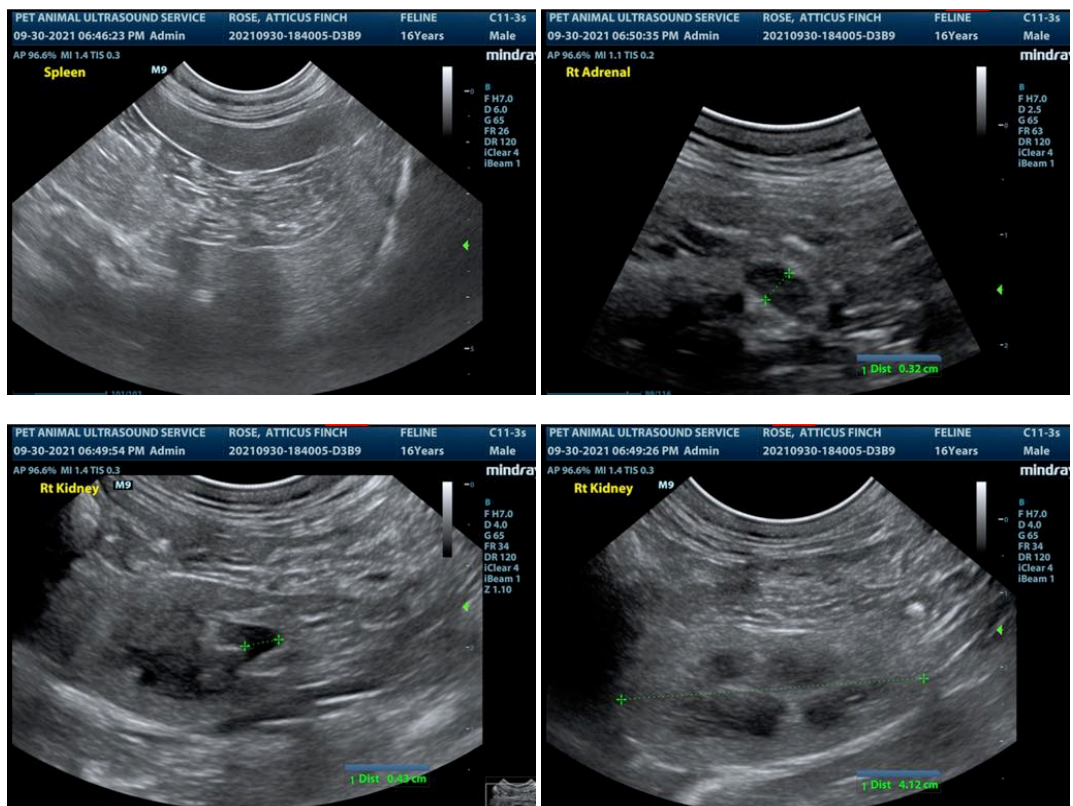
Dr. Poor

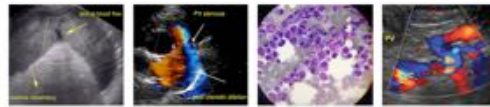
INVOICE

92118

DATE

9/30/21





PATIENT

Atticus Finch Rose

SPECIES

Feline

BREED

Domestic Shorthair

SEX

Neutered Male

AGE

17 years

WEIGHT

11.3 lbs

INTERPRETED BY

Eric Lindquist, DMV,
 DABVP, Cert. IVUS,
 CEO of SonoPath.com

IMAGING PERFORMED BY

Pamela Harrigan, RDCS

HOSPITAL NAME

Norfolk County VS

REFERRING VET

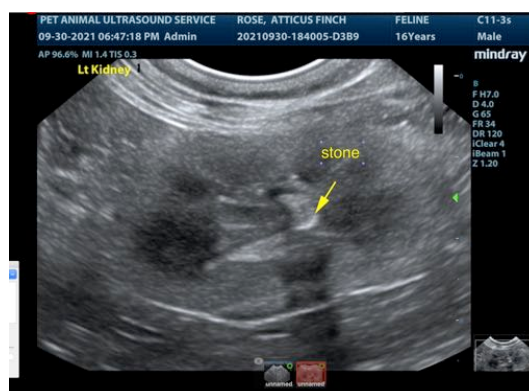
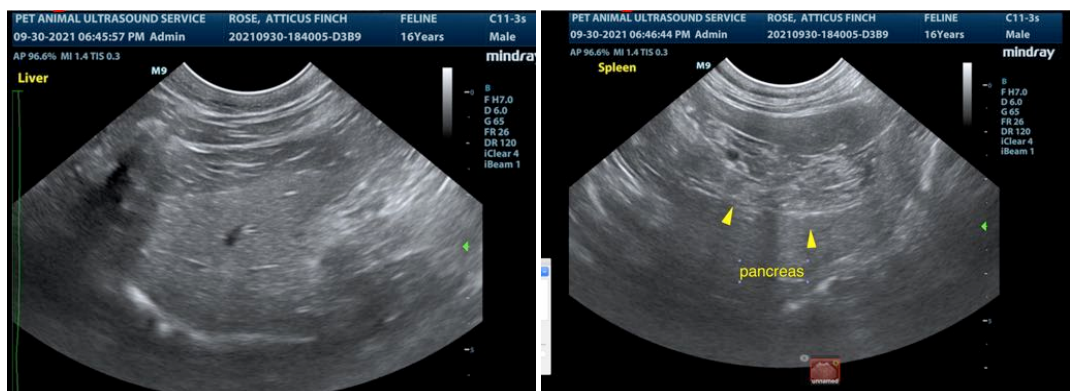
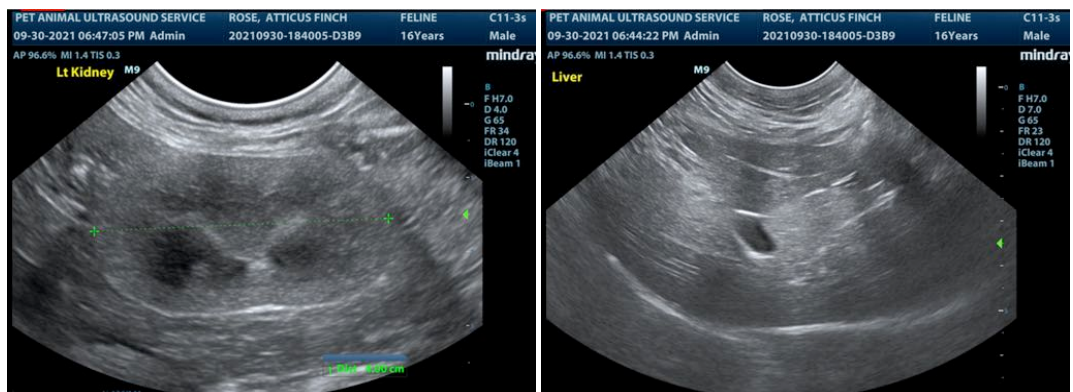
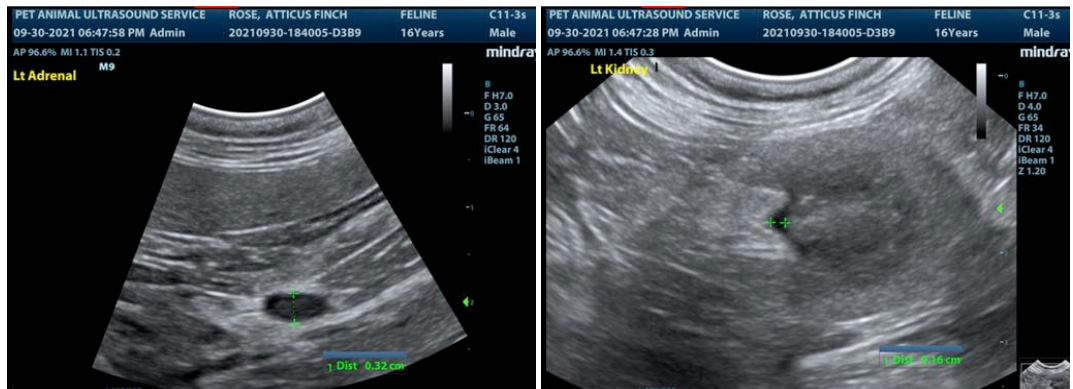
Dr. Poor

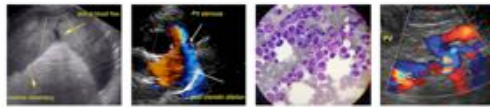
INVOICE

92118

DATE

9/30/21





PATIENT

Atticus Finch Rose

The information and recommendations provided are based on the images presented by the referring veterinarian. No evaluation can be communicated regarding pathology that was not visible in the image/video clips provided.

SPECIES

Feline

Thank you for this referral. If the clinical or image interpretation does not parallel your findings or if I can be of any further assistance please contact me.

Eric Lindquist, DMV, DABVP, Cert. IVUSS, CEO of SonoPath.com

BREED

Domestic Shorthair

Info@SonoPath.com

SEX

Neutered Male

AGE

17 years

WEIGHT

11.3 lbs

INTERPRETED BY

Eric Lindquist, DMV,
DABVP, Cert. IVUSS,
CEO of SonoPath.com

**IMAGING
PERFORMED BY**

Pamela Harrigan, RDMS

HOSPITAL NAME

Norfolk County VS

REFERRING VET

Dr. Poor

INVOICE

92118

DATE

9/30/21