



**PATIENT**

Rosie Kerrisk

**SPECIES**

Canine

**BREED**

Mix

**SEX**

Spayed Female

**AGE**

14 Years

**WEIGHT**

21.40 Pounds

**INTERPRETED BY**

Eric Lindquist, DMV  
DABVP, Cert. IVUSS

**IMAGING  
PERFORMED BY**

Marcela Salas

**HOSPITAL NAME**

Tenafly VC

**REFERRING VET**

Marcela Salas

**INVOICE**

12919

**DATE**

9/3/21

**PRESENTING CLINICAL SIGNS**

History: acute fx of tibia/fibula- for unknow cause- perhaps other dog? bone looks healthy. dog looks healthy but on labs we found azotemia and hyperphosphatemia along with anemia. dog looks good and is otherwise wnl clinically. right now we are working up the azotemia with lepto/ua/ucs, urine sp gr 1.025.

Abnormal PE/Chem/CBC/UA Results:

**ULTRASONOGRAPHIC EXAMINATION OF THE ABDOMEN**

**Urinary System**

The **urinary bladder**, trigone, and pelvic urethra presented normal thicknesses and normal tone. The ureters were not visible which is normal. No uroliths or sediment were visualized and anechoic urine was present. No evidence of inflammatory or neoplastic changes were noted. Ureteral papillae were normal.

The **kidneys** revealed largely normal size and structure, corticomedullary definition and ratio (cortex 1/3 of medulla) were essentially maintained with some mild to moderate age-related loss of curvilinear patterns regarding the capsule and C/M junction. The cortices presented largely uniform texture with some increased echogenicity expected for his age patient. Medullary structure differed distinctly from that of the cortex and no evidence of pelvic dilation was present. The left kidney measured 3.9 cm. The right kidney measured 3.55 cm.

**Adrenal Glands**

Both **adrenal glands** were visualized and recognized as having normal shape, size, position and echogenicity for this breed. The phrenic vasculature, glandular echogenicity and detail were unremarkable. Capsule, cortex, and medullary definition were normal for this age patient. The left adrenal gland measured 0.5 cm. The right adrenal gland measured 0.5 cm.

**Spleen**

The **spleen** was largely smooth with minor subtle heterogeneous parenchymal changes while maintaining normal echogenic relationship to the liver and kidney. These changes are consistent with normal age-related alteration. The capsule was smooth without noticeable impingement from within the spleen or from pathology in the adjacent abdomen. The splenic vasculature demonstrated normal volume without signs of congestion or significant contraction. A hypoechoic nodule was noted, measuring 0.8 cm x 0.4 cm.

**Liver**

The **liver** images from right and left intercostal as well as subcostal views revealed subjectively normal liver size, contour, and structure. Some moderate age-related parenchymal remodeling was noted but likely not clinically significant at this time. Vascular and biliary tracts were of normal volume and no evidence of congestion was noted. The gallbladder presented some dependent debris with essentially normal contour. The cystic and common bile ducts were normal. No overt evidence of active inflammatory, infiltrative or regenerative pathology was noted but should be paired with current or past LE elevations regarding any clinical significance to this presentation. The hepatic lymph nodes were unremarkable.



**PATIENT**

**Gastrointestinal**

Rosie Kerrisk

Examination of the **gastrointestinal tract** revealed a stomach and intestine free of stasis, of normal wall thickness, acceptable curvilinear mural detail, and peristaltic activity. Small and large intestine demonstrated normal luminal chyme and stool consistency respectively. No obstructive or overt infiltrative disease was noted. No associated abnormal lymphatic activity was noted.

**SPECIES**

Canine

**Pancreas**

**BREED**

Mix

The base and limbs of the **pancreas** were observed to be largely isoechoic to surrounding omental fat. Pancreatic duct and capsular contour were acceptably normal and parenchyma respected normal curvilinear patterns. No overt evidence of active inflammatory or neoplastic disease was noted.

**SEX**

Spayed Female

**ULTRASONOGRAPHIC FINDINGS**

- Unremarkable geriatric abdomen
- Splenic nodule, likely hyperplasia, minor potential for emerging round cell neoplasia

**AGE**

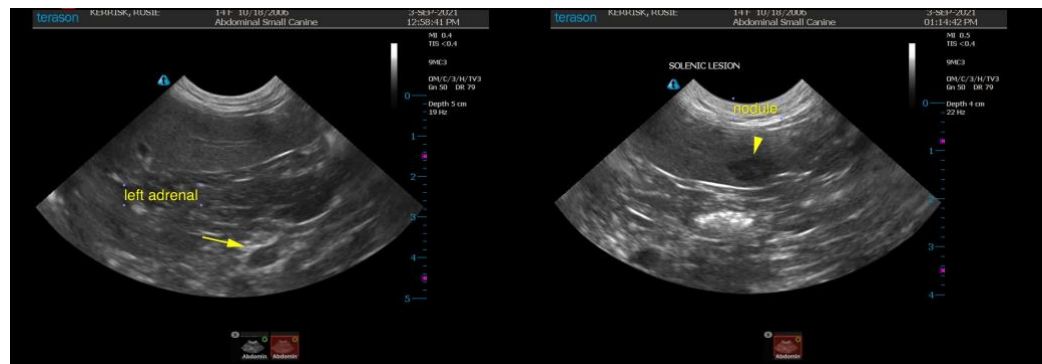
14 Years

**INTERPRETATION OF THE FINDINGS & FURTHER RECOMMENDATIONS**

No evidence of other disease.

**WEIGHT**

21.40 Pounds

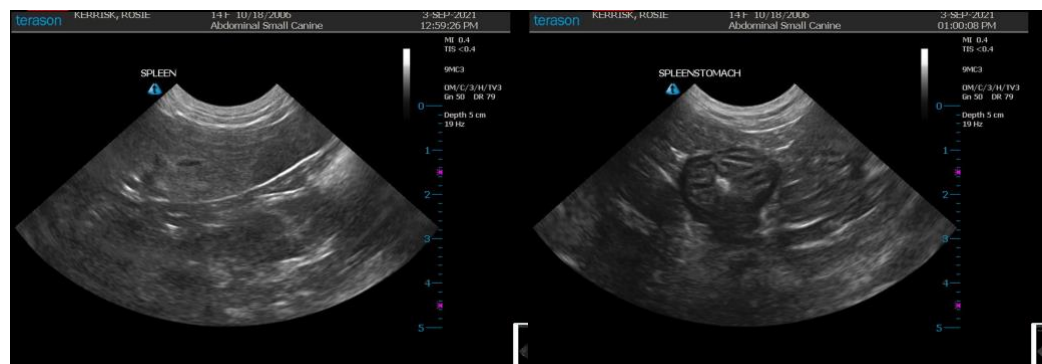

**INTERPRETED BY**

Eric Lindquist, DMV  
DABVP, Cert. IVUSS

**IMAGING PERFORMED BY**

Marcela Salas



**HOSPITAL NAME**

Tenafly VC

**REFERRING VET**

Marcela Salas

**INVOICE**

12919

**DATE**

9/3/21



**PATIENT**

Rosie Kerrisk

**SPECIES**

Canine

**BREED**

Mix

**SEX**

Spayed Female

**AGE**

14 Years

**WEIGHT**

21.40 Pounds

**INTERPRETED BY**

Eric Lindquist, DMV  
DABVP, Cert. IVUSS

**IMAGING PERFORMED BY**

Marcela Salas

**HOSPITAL NAME**

Tenafly VC

**REFERRING VET**

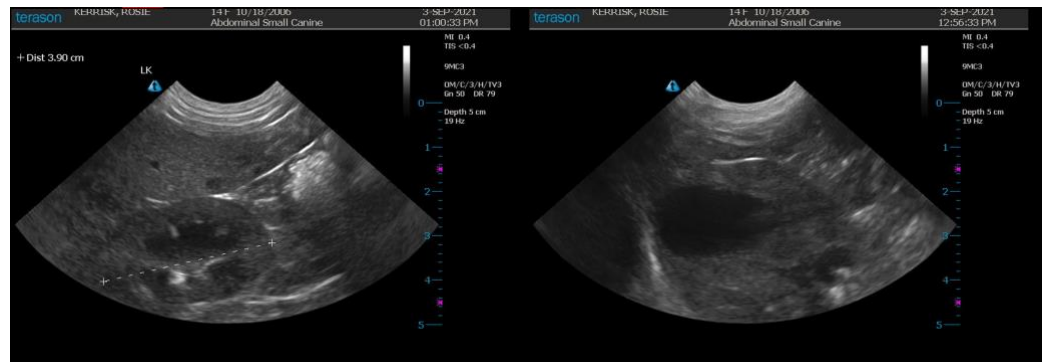
Marcela Salas

**INVOICE**

12919

**DATE**

9/3/21



The information and recommendations provided are based on the images presented by the referring veterinarian. No evaluation can be communicated regarding pathology that was not visible in the image/video clips provided.

Thank you for this referral. If the clinical or image interpretation does not parallel your findings or if I can be of any further assistance please contact me.

**Eric Lindquist**, DMV, DABVP, Cert. IVUSS, CEO of SonoPath.com  
info@SonoPath.com