



**PATIENT**

Zazu Gratt

**PRESENTING CLINICAL SIGNS**

History: Anemia Wt loss Diluted urine Pli + BW WNL

**SPECIES**

Feline

**ULTRASONOGRAPHIC EXAMINATION OF THE ABDOMEN**

**Urinary System**

**BREED**

Domestic Shorthair

The **urinary bladder**, trigone, and pelvic urethra presented normal thicknesses and normal tone. The ureters were not visible which is normal. No uroliths or sediment were visualized and anechoic urine was present. No evidence of inflammatory or neoplastic changes was noted. Ureteral papillae were normal.

**SEX**

Neutered male

The **kidneys** revealed largely normal size and structure, corticomedullary definition and ratio (cortex 1/3 of medulla) were essentially maintained with some age-related loss of curvilinear patterns regarding the capsule and C/M junction. The cortices presented largely uniform texture with some increased echogenicity expected for his age patient. Medullary structure differed distinctly from that of the cortex and no evidence of pelvic dilation was present. The right kidney measured 4.55 cm. The left kidney measured 3.8 cm.

**AGE**

15 years

**WEIGHT**

11.9 lbs

**Adrenal Glands**

Both **adrenal glands** were visualized and recognized as having normal shape, size, position and echogenicity for this breed. The phrenic vasculature, glandular echogenicity and detail were unremarkable. Capsule, cortex, and medullary definition were normal for this age patient.

**INTERPRETED BY**

Eric Lindquist, DMV  
DABVP, Cert. IVUSS

**Spleen**

The **spleen** presented a smooth homogeneous parenchyma hyperechoic to liver and renal cortical parenchyma. The capsule was smooth without noticeable expansion or deviation from within the spleen or adjacent pathology. The splenic vasculature demonstrated normal volume without signs of congestion or thrombosis. No sonographic evidence of acute or chronic inflammatory, neoplastic, or infarctual changes was noted.

**IMAGING PERFORMED BY**

Dr. Barnea

**HOSPITAL NAME**

Tenafly VC

**Liver**

The **liver** revealed coarse architecture. The gallbladder and common bile duct were unremarkable with mildly increased portal markings.

**REFERRING VET**

Dr. Barnea

**INVOICE**

39694

**Gastrointestinal**

The **gastrointestinal** presentation revealed mild uniform prominence of the gastric mucosa as well as areas of "ropey" small intestinal wall with slight disruption of the normal 1:3 muscularis/mucosal ratio. The intestinal submucosa was slightly irregular, thickened and hyperechoic suggestive of low grade, chronic disease. The mesenteric lymph node was enlarged and measured 2.5 cm. Other smaller lymph nodes were enlarged. However, the length to width ratio was maintained. No evidence of obstruction

**DATE**

9/29/22



**PATIENT**

Zazu Gratt

was present. Chronic inflammatory bowel disease is likely with a low possibility of an early neoplastic event such as lymphoma. Full thickness tissue biopsies via open laparotomy, ideally guided by intraoperative ultrasound in order to obtain the most representative mural sample, would be necessary to rule out this possibility.

**SPECIES**

Feline

**Pancreas**

**BREED**

Domestic Shorthair

The base and limbs of the **pancreas** were observed to be largely isoechoic to surrounding omental fat. Pancreatic duct and capsular contour were acceptably normal and parenchyma respected normal curvilinear patterns. No overt evidence of active inflammatory or neoplastic disease was noted.

**SEX**

Neutered male

**ULTRASONOGRAPHIC FINDINGS**

Variable intestinal thickening with mesenteric lymphadenopathy. Lymphadenitis, inflammatory bowel versus emerging round cell neoplasia.

**AGE**

15 years

Otherwise, age related abdominal changes.

**WEIGHT**

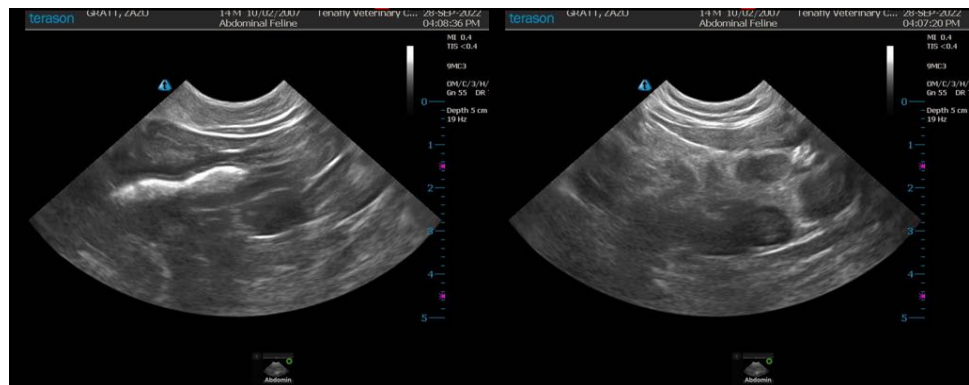
11.9 lbs

**INTERPRETATION OF THE FINDINGS & FURTHER RECOMMENDATIONS**

Ultrasound-guided FNA of the lymph nodes with cytology and culture is indicated. PCR or PARR evaluation of the cytology may be appropriate depending upon interpretation. Otherwise, full thickness intestinal lymph node biopsies would be indicated.

**INTERPRETED BY**

Eric Lindquist, DMV  
DABVP, Cert. IVUS



**IMAGING PERFORMED BY**

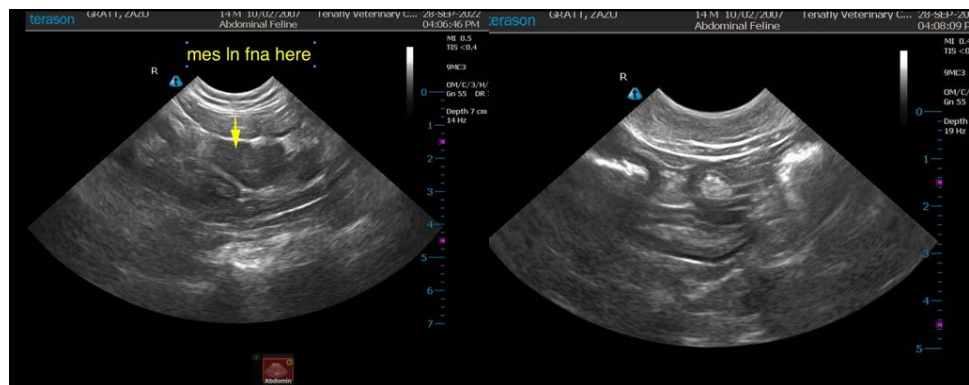
Dr. Barnea

**HOSPITAL NAME**

Tenafly VC

**REFERRING VET**

Dr. Barnea



**INVOICE**

39694

**DATE**

9/29/22



**PATIENT**

Zazu Gratt

**SPECIES**

Feline

**BREED**

Domestic Shorthair

**SEX**

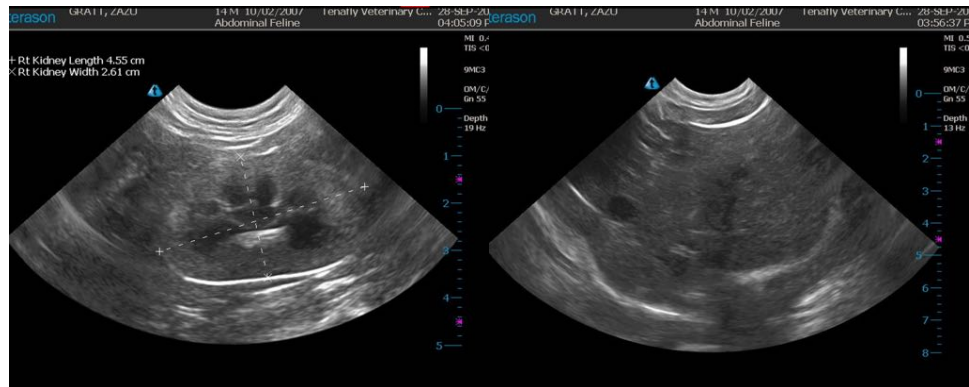
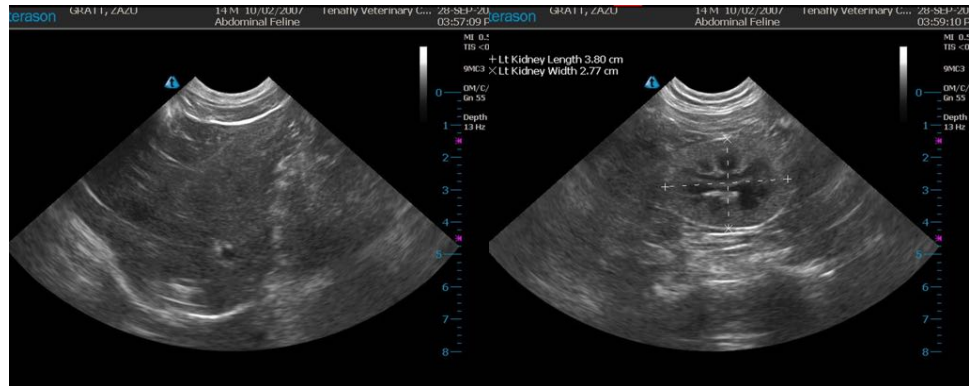
Neutered male

**AGE**

15 years

**WEIGHT**

11.9 lbs



**INTERPRETED BY**

Eric Lindquist, DMV  
DABVP, Cert. IVUSS

**IMAGING PERFORMED BY**

Dr. Barnea

**HOSPITAL NAME**

Tenafly VC

**REFERRING VET**

Dr. Barnea

**INVOICE**

39694

**DATE**

9/29/22

The information and recommendations provided are based on the images presented by the referring veterinarian/sonographer. No evaluation can be communicated regarding pathology that was not visible in the image/video clips provided.

Thank you for this referral. If the clinical or image interpretation does not parallel your findings or if I can be of any further assistance please contact me.

**Eric Lindquist**, DMV, DABVP, Cert. IVUSS, CEO of SonoPath.com  
info@SonoPath.com