



PATIENT

Gandalf Johnson

SPECIES

Feline

BREED

DSH

SEX

Spayed Female

AGE

13 Years

WEIGHT

7.4 Pounds

INTERPRETED BY

Eric Lindquist, DMV

DABVP, Cert. IVUSS

IMAGING PERFORMED BY

Jenn

HOSPITAL NAME

Rockaway AH

REFERRING VET

Dr. Maniar

INVOICE

41739

DATE

9/29/22

PRESENTING CLINICAL SIGNS

re check prev u/s showed geriatric abd with idiopathic cystitis Owner states doing well at home eating drinking normally, threw up once in the last few weeks.... food with hairball, had a couple of urinary accidents on the floor

ULTRASONOGRAPHIC EXAMINATION OF THE ABDOMEN

Urinary System

The **urinary bladder**, trigone, and pelvic urethra presented normal thicknesses and normal tone. The ureters were not visible which is normal. No uroliths or sediment were visualized and anechoic urine was present. No evidence of inflammatory or neoplastic changes were noted. Ureteral papillae were normal. The pelvic urethra was imaged 2.0 cm beyond the cystourethral junction.

The **kidneys** revealed largely normal size and structure, corticomedullary definition and ratio (cortex 1/3 of medulla) were essentially maintained with some age-related loss of curvilinear patterns regarding the capsule and C/M junction. The cortices presented largely uniform texture with some increased echogenicity expected for his age patient. Medullary structure differed distinctly from that of the cortex and no evidence of pelvic dilation was present. The right kidney measured 3.87 cm. The left kidney measured 3.56 cm.

Adrenal Glands

The regions of the **adrenal glands** were unremarkable.

Spleen

The **spleen** presented a smooth homogeneous parenchyma hyperechoic to liver and renal cortical parenchyma. The capsule was smooth without noticeable expansion or deviation from within the spleen or adjacent pathology. The splenic vasculature demonstrated normal volume without signs of congestion or thrombosis. No sonographic evidence of acute or chronic inflammatory, neoplastic, or infarctual changes were noted.

Liver

The **liver** images from right and left intercostal as well as subcostal views revealed subjectively normal liver size, contour, and structure. Some age-related parenchymal remodeling was noted but likely not clinically significant at this time. Vascular and biliary tracts were of normal volume and no evidence of congestion was noted. The gallbladder presented some dependent debris with essentially normal contour. The cystic and common bile ducts were normal. No overt evidence of active inflammatory, infiltrative or regenerative pathology was noted but should be paired with current or past LE elevations regarding any clinical significance to this presentation. The hepatic lymph nodes were unremarkable.

Gastrointestinal

The **gastrointestinal tract** revealed minor variable thickening and echogenic submucosal changes most consistent with low grade end result of chronic GI disease such as IBD and may be related to malassimilation of nutrients if any weight loss is present. Some soft shadowing material noted in the stomach, consistent with retention of ingesta and/or hairball accumulation.

Pancreas

The base and limbs of the **pancreas** were observed to be largely isoechoic to surrounding omental fat. Some parenchymal remodeling, however, with mild deviation from curvilinear normalcy was observed. Pancreatic duct and capsular irregularities were present consistent with age related changes. If pain



PATIENT

Gandalf Johnson

upon imaging (+ Murphy sign) was present or if the patient is focally painful in subxyphoid palpation then low-grade smoldering chronic pancreatitis should be suspected.

ULTRASONOGRAPHIC FINDINGS

SPECIES

Feline

- Chronic pancreatic changes
- Age related GI with likely hairball accumulation

INTERPRETATION OF THE FINDINGS & FURTHER RECOMMENDATIONS

BREED

DSH

Hairball therapy warranted. No other evidence of significant disease.

SEX

Spayed Female

AGE

13 Years

WEIGHT

7.4 Pounds

INTERPRETED BY

Eric Lindquist, DMV
DABVP, Cert. IVUSS

IMAGING PERFORMED BY

Jenn

HOSPITAL NAME

Rockway AH

REFERRING VET

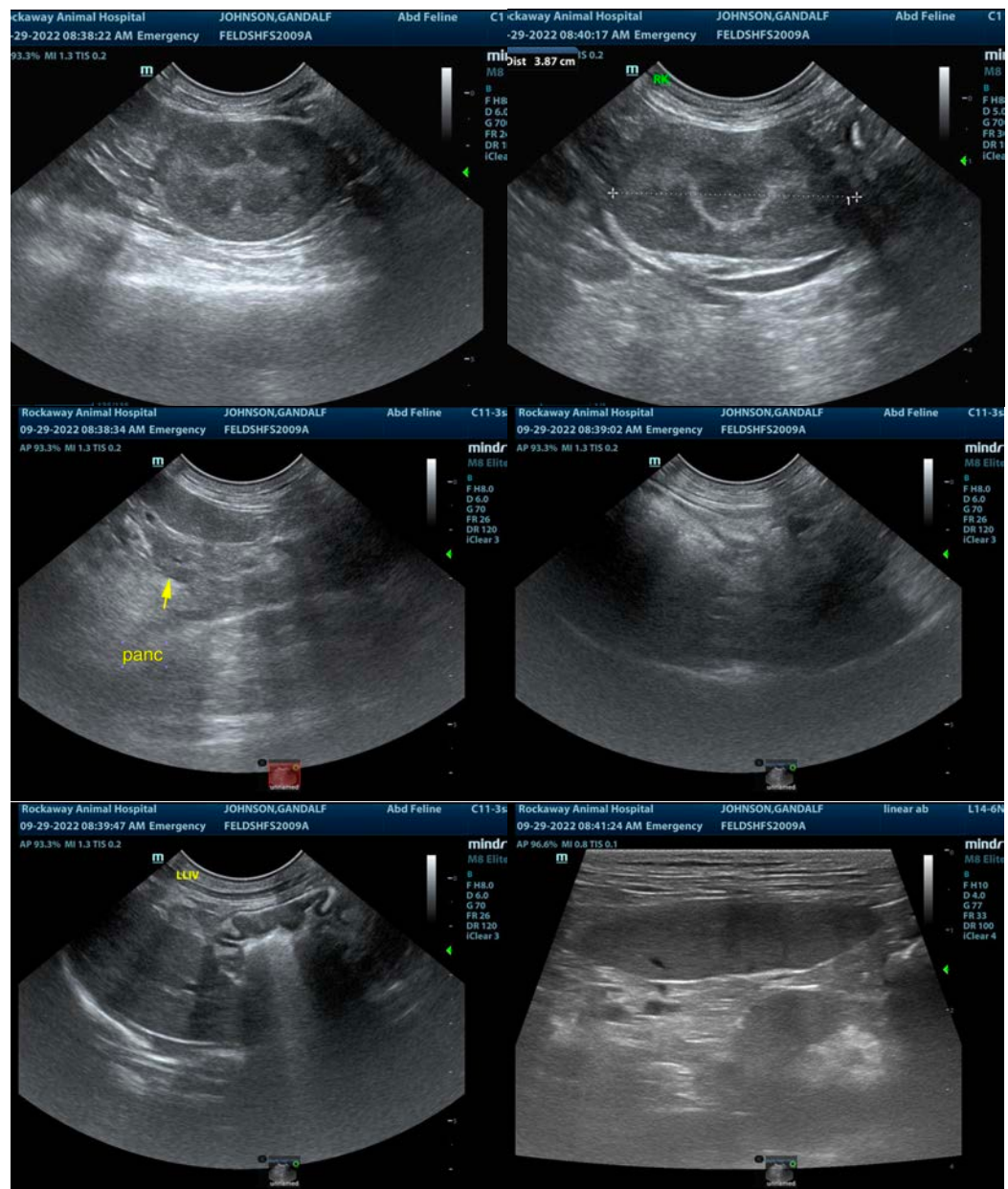
Dr. Maniar

INVOICE

41739

DATE

9/29/22





PATIENT

Gandalf Johnson

The information and recommendations provided are based on the images presented by the referring veterinarian/sonographer. No evaluation can be communicated regarding pathology that was not visible in the image/video clips provided.

SPECIES

Feline

Thank you for this referral. If the clinical or image interpretation does not parallel your findings or if I can be of any further assistance please contact me.

Eric Lindquist, DMV, DABVP, Cert. IVUSS, CEO of SonoPath.com

info@SonoPath.com

BREED

DSH

SEX

Spayed Female

AGE

13 Years

WEIGHT

7.4 Pounds

INTERPRETED BY

Eric Lindquist, DMV

DABVP, Cert. IVUSS

IMAGING PERFORMED BY

Jenn

HOSPITAL NAME

Rockaway AH

REFERRING VET

Dr. Maniar

INVOICE

41739

DATE

9/29/22