



PATIENT

Fox Brunt

PRESENTING CLINICAL SIGNS

Diabetic cat, recently reduced insulin from 2 units BID to 0.5 unit in AM to 1 unit PM, now acute vomiting.

SPECIES

Feline

Abnormal PE/Chem/CBC/UA Results: Sending out labs today to Idexx.

ULTRASONOGRAPHIC EXAMINATION OF THE ABDOMEN

BREED

DSH

Urinary System

The **urinary bladder**, trigone, and pelvic urethra presented normal thicknesses and normal tone. The ureters were not visible which is normal. No uroliths or sediment were visualized and anechoic urine was present. No evidence of inflammatory or neoplastic changes were noted. Ureteral papillae were normal.

SEX

Male

The **kidneys** revealed largely normal size and structure, corticomedullary definition and ratio (cortex 1/3 of medulla) were essentially maintained with some age-related loss of curvilinear patterns regarding the capsule and C/M junction. The cortices presented largely uniform texture with some increased echogenicity expected for his age patient. Medullary structure differed distinctly from that of the cortex. Slight mineralization and slight pyelectasia noted. The kidneys measured 3.5 cm each. Cortical remodeling noted in both kidneys.

AGE

9 Years

WEIGHT

13.5 Pounds

Adrenal Glands

The regions of the **adrenal glands** were unremarkable.

Spleen

The **spleen** presented a smooth homogeneous parenchyma hyperechoic to liver and renal cortical parenchyma. The capsule was smooth without noticeable expansion or deviation from within the spleen or adjacent pathology. The splenic vasculature demonstrated normal volume without signs of congestion or thrombosis. No sonographic evidence of acute or chronic inflammatory, neoplastic, or infarctual changes were noted.

INTERPRETED BY

Eric Lindquist, DMV

DABVP, Cert. IVUSS

IMAGING PERFORMED BY

Dr. Johnny Slaughter

HOSPITAL NAME

Camden-Inner Harbor

Liver

The **liver** images submitted revealed subjectively normal liver size, contour, and structure. Parenchymal echogenicity was naturally coarse and hypoechoic to the spleen. Vascular and biliary tracts were of normal volume with no evidence of congestion. The gallbladder presented acceptably thin walls with primarily anechoic content. The cystic and common bile ducts were normal. No pathological hepatic lymphadenopathy was evident. No overt structural evidence of inflammatory, infiltrative or regenerative pathology was evident.

REFERRING VET

Dr. Johnny Slaughter

Gastrointestinal

There was some residual chyme and gas was noted in the **stomach**, yet not pathological. This is consistent with end post prandial presentation. Transit of chyme into the small intestine was normal. Curvilinear patterns were maintained throughout the GI tract. No evidence of pathology. Small and large intestine demonstrated normal luminal chyme and stool consistency respectively. No obstructive or overt infiltrative disease was noted. No associated abnormal lymphatic activity was noted.

INVOICE

41783

DATE

9/30/22



PATIENT

Fox Brunt

SPECIES

Feline

BREED

DSH

SEX

Male

AGE

9 Years

WEIGHT

13.5 Pounds

INTERPRETED BY

Eric Lindquist, DMV

DABVP, Cert. IVUSS

IMAGING PERFORMED BY

Dr. Johnny Slaughter

HOSPITAL NAME

Camden-Inner Harbor

REFERRING VET

Dr. Johnny Slaughter

INVOICE

41783

DATE

9/30/22

Pancreas

The base and limbs of the **pancreas** were observed to be largely isoechoic to surrounding omental fat. Pancreatic duct and capsular contour were acceptably normal and parenchyma respected normal curvilinear patterns. No overt evidence of active inflammatory or neoplastic disease was noted.

ULTRASONOGRAPHIC FINDINGS

- Unremarkable abdomen with minor degenerative renal changes

INTERPRETATION OF THE FINDINGS & FURTHER RECOMMENDATIONS

No evidence of abdominal disease influencing the clinical status.

Potential Causes of Diabetic Dysregulation

This is a suggestive checkoff list when faced with an unregulated diabetic patient:

UTI

Dietary indiscretion/intolerance

Pancreatitis

Hyperthyroidism/hypothyroidism

Exogenous steroids (including topical eye meds)

Cushing's

Acromegaly

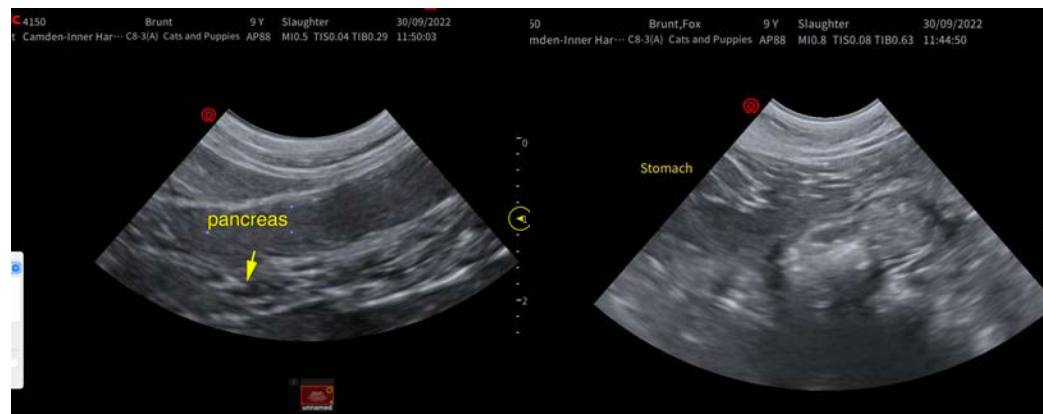
Owner compliance

Insulin quality issues

Antibodies to insulin

Underlying Neoplasia

Diffuse liver disease





PATIENT

Fox Brunt

SPECIES

Feline

BREED

DSH

SEX

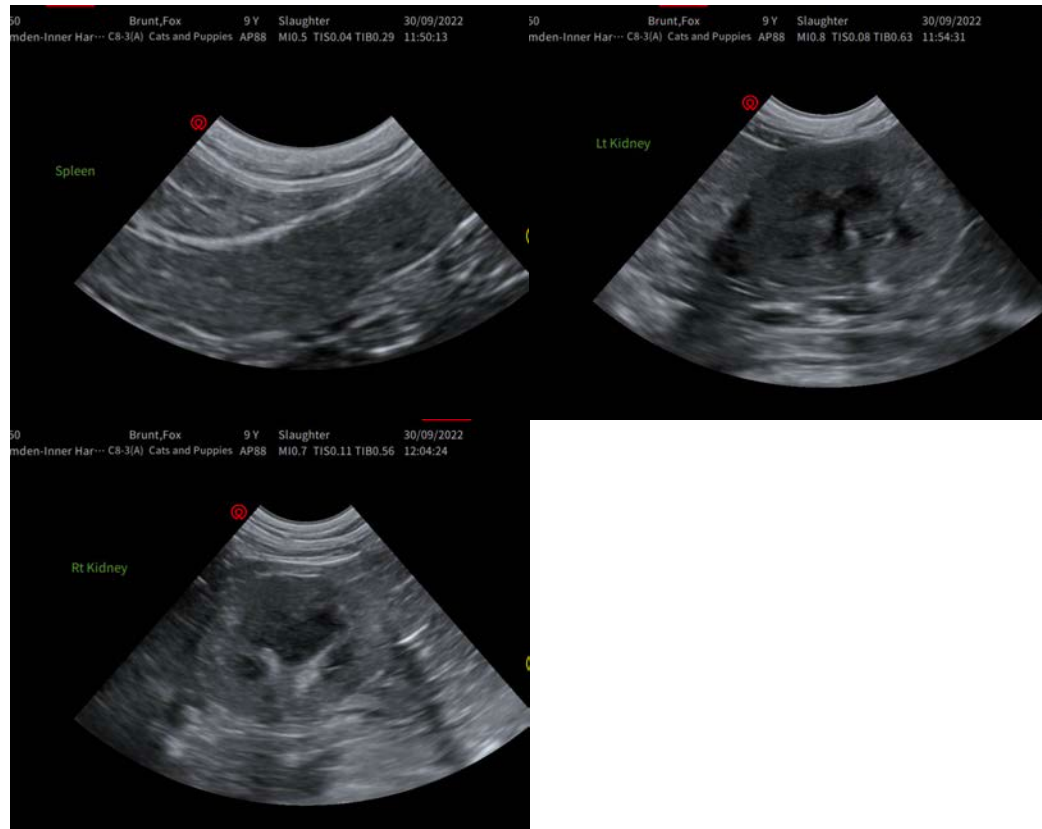
Male

AGE

9 Years

WEIGHT

13.5 Pounds



INTERPRETED BY

Eric Lindquist, DMV

DABVP, Cert. IVUSS

IMAGING PERFORMED BY

Dr. Johnny Slaughter

HOSPITAL NAME

Camden-Inner Harbor

REFERRING VET

Dr. Johnny Slaughter

INVOICE

41783

DATE

9/30/22

The information and recommendations provided are based on the images presented by the referring veterinarian/sonographer. No evaluation can be communicated regarding pathology that was not visible in the image/video clips provided.

Thank you for this referral. If the clinical or image interpretation does not parallel your findings or if I can be of any further assistance please contact me.

Eric Lindquist, DMV, DABVP, Cert. IVUSS, CEO of SonoPath.com

info@SonoPath.com