



**PATIENT**

Bron McFarquhar

**PRESENTING CLINICAL SIGNS**

re check prev u/s on 9/24 showed a full stomach with normal abd now vomiting

**SPECIES**

Canine

**ULTRASONOGRAPHIC EXAMINATION OF THE ABDOMEN**

**Urinary System**

The **urinary bladder**, trigone, and pelvic urethra presented normal thicknesses and normal tone. The ureters were not visible which is normal. No uroliths or sediment were visualized and anechoic urine was present. No evidence of inflammatory or neoplastic changes were noted. Ureteral papillae were normal. The pelvic urethra was imaged 2.0 cm beyond the cystourethral junction.

**BREED**

Mastiff X

**SEX**

Neutered Male

The **kidneys** revealed normal size and structure, corticomedullary definition and ratio for this age. The cortices presented largely uniform texture with normal echogenic relationship to liver and spleen. Medullary structure differed distinctly from the cortex and no evidence of pelvic dilation was present. The capsules were acceptably uniform without significant irregularities. The right kidney measured 6.06 cm. The left kidney measured 6.15 cm.

**AGE**

3 Years

**Adrenal Glands**

Both **adrenal glands** were visualized and recognized as having normal shape, size, position and echogenicity for this breed. The phrenic vasculature, glandular echogenicity and detail were unremarkable. Capsule, cortex, and medullary definition were normal for this age patient. The right adrenal gland measured 2.64 cm x 1.63 cm at the cranial pole and 0.75 cm at the caudal pole. The left adrenal gland measured 2.02 cm x 0.65 cm at the caudal pole and 0.98 cm at the cranial pole.

**WEIGHT**

63.5 Pounds

**Spleen**

The **spleen** presented a smooth homogeneous parenchyma hyperechoic to liver and renal cortical parenchyma. The capsule was smooth without noticeable expansion or deviation from within the spleen or adjacent pathology. The splenic vasculature demonstrated normal volume without signs of congestion or thrombosis. No sonographic evidence of acute or chronic inflammatory, neoplastic, or infarctual changes were noted.

**INTERPRETED BY**

Eric Lindquist, DMV

DABVP, Cert. IVUSS

**IMAGING PERFORMED BY**

Jenn

**HOSPITAL NAME**

Rockaway AH

**Liver**

The **liver** images submitted revealed subjectively normal liver size, contour, and structure. Parenchymal echogenicity was naturally coarse and hypoechoic to the spleen. Vascular and biliary tracts were of normal volume with no evidence of congestion. The gallbladder presented acceptably thin walls with primarily anechoic content. The cystic and common bile ducts were normal. No pathological hepatic lymphadenopathy was evident. No overt structural evidence of inflammatory, infiltrative or regenerative pathology was evident.

**REFERRING VET**

Dr. Maniar

**Gastrointestinal**

The **stomach** was significantly overdistended with anechoic fluid. Adjacent to the right of the stomach was a 2.5 cm progressively shadowing structure. This could not be distinguished between transverse colon and upper duodenum. Further imaging necessary, better yet 12-18 hour IV fluid support and NPO status with recheck sonogram at that time to assess for underlying foreign body obstruction. The remainder of the small intestine appeared empty.

**INVOICE**

41748

**DATE**

9/29/22



**PATIENT**

Bron McFarquhar

**Pancreas**

The base and limbs of the **pancreas** were observed to be largely isoechoic to surrounding omental fat. Pancreatic duct and capsular contour were acceptably normal and parenchyma respected normal curvilinear patterns. No overt evidence of active inflammatory or neoplastic disease was noted.

**SPECIES**

Canine

**ULTRASONOGRAPHIC FINDINGS**

- Gastric delayed outflow pattern – possible obstruction yet could not be confirmed.

**BREED**

Mastiff X

**INTERPRETATION OF THE FINDINGS & FURTHER RECOMMENDATIONS**

Conservative therapy and recheck sonogram in 12-24 hours recommended.

**SEX**

Neutered Male

**AGE**

3 Years

**WEIGHT**

63.5 Pounds

**INTERPRETED BY**

Eric Lindquist, DMV  
DABVP, Cert. IVUSS

**IMAGING PERFORMED BY**

Jenn

**HOSPITAL NAME**

Rockway AH

**REFERRING VET**

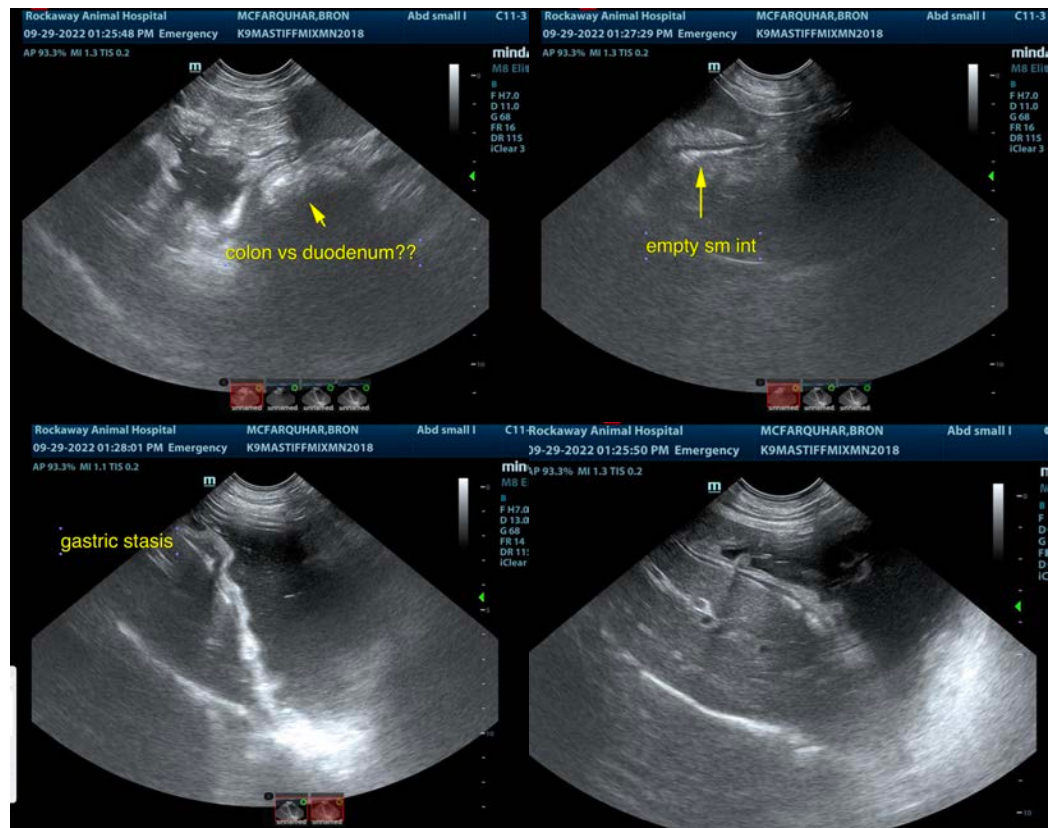
Dr. Maniar

**INVOICE**

41748

**DATE**

9/29/22





**PATIENT**

Bron McFarquhar

**SPECIES**

Canine

**BREED**

Mastiff X

**SEX**

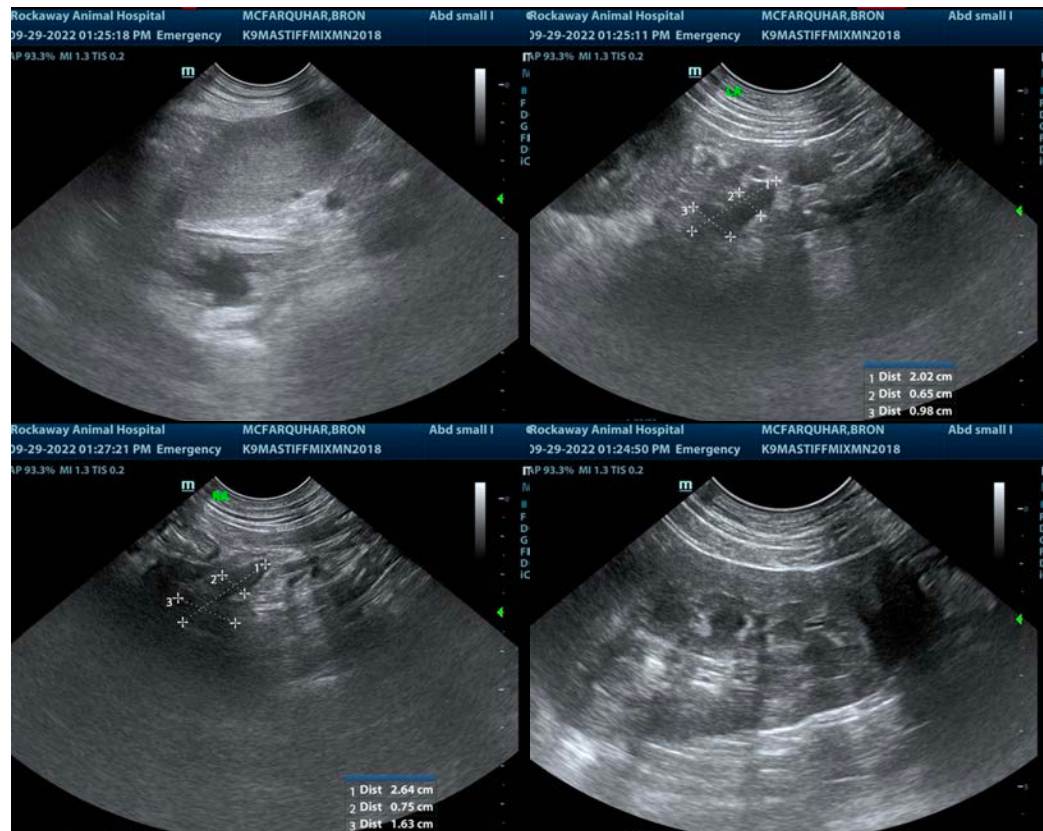
Neutered Male

**AGE**

3 Years

**WEIGHT**

63.5 Pounds



**INTERPRETED BY**

Eric Lindquist, DMV

DABVP, Cert. IVUSS

**IMAGING PERFORMED BY**

Jenn

**HOSPITAL NAME**

Rockway AH

**REFERRING VET**

Dr. Maniar

**INVOICE**

41748

**DATE**

9/29/22

The information and recommendations provided are based on the images presented by the referring veterinarian/sonographer. No evaluation can be communicated regarding pathology that was not visible in the image/video clips provided.

Thank you for this referral. If the clinical or image interpretation does not parallel your findings or if I can be of any further assistance please contact me.

Eric Lindquist, DMV, DABVP, Cert. IVUSS, CEO of SonoPath.com

[info@SonoPath.com](mailto:info@SonoPath.com)