



PATIENT

Bella Kuch

SPECIES

Canine

BREED

American Pit Bull

SEX

Spayed Female

AGE

8 Years

WEIGHT

55.8 Pounds

INTERPRETED BY

Eric Lindquist, DMV

DABVP, Cert. IVUSS

IMAGING PERFORMED BY

Dr. Michelle Bartus

HOSPITAL NAME

Valley Vet Service

REFERRING VET

Dr. Michelle Bartus

INVOICE

41776

DATE

9/29/22

PRESENTING CLINICAL SIGNS

Started with severe deep pyoderma in the Spring, resistant bacteria cultured. Has been treated with Zeniquin, 90% better but all lesions have not healed. Dog started to lose weight and get a pendulous look to abdomen recently. She is PU/PD.

Abnormal PE/Chem/CBC/UA Results: ALKP 351 (23-212), CHOL 497 (110-320); Low Lym 0.85 (1.05-5.1) U/A: Sp. Gr. 1.012 pH 6.5 Pro 30, Bld 50

ULTRASONOGRAPHIC EXAMINATION OF THE ABDOMEN

Urinary System

The **urinary bladder**, trigone, and pelvic urethra presented normal thicknesses and normal tone. The ureters were not visible which is normal. No uroliths or sediment were visualized and anechoic urine was present. No evidence of inflammatory or neoplastic changes were noted. Ureteral papillae were normal. The pelvic urethra was imaged 2.0 cm beyond the cystourethral junction.

The **kidneys** revealed largely normal size and structure, corticomedullary definition and ratio (cortex 1/3 of medulla) were essentially maintained with some age-related loss of curvilinear patterns regarding the capsule and C/M junction. The cortices presented largely uniform texture with some increased echogenicity expected for his age patient. Medullary structure differed distinctly from that of the cortex and no evidence of pelvic dilation was present. Slight mineralization noted in both kidneys. The right kidney measures 7.6 cm. The left kidney measures 6.73 cm.

Adrenal Glands

Both **adrenal glands** were visualized and recognized as having normal shape, size, position and echogenicity for this breed. The phrenic vasculature, glandular echogenicity and detail were unremarkable. Capsule, cortex, and medullary definition were normal for this age patient. The right adrenal gland measured 0.66 cm at the caudal pole and 0.69 cm at the cranial pole. The left adrenal gland was enlarged at 1.21 cm at the caudal pole and 0.90 cm at the cranial pole.

Spleen

The **spleen** presented a smooth homogeneous parenchyma hyperechoic to liver and renal cortical parenchyma. The capsule was smooth without noticeable expansion or deviation from within the spleen or adjacent pathology. The splenic vasculature demonstrated normal volume without signs of congestion or thrombosis. No sonographic evidence of acute or chronic inflammatory, neoplastic, or infarctual changes were noted.

Liver

The **liver** was diffusely hyperechoic to falciform fat. The parenchyma was unremarkable. The gallbladder presented a minor amount of excessive debris with micropolypoid changes, not to the level of mucocele formation.

Gastrointestinal

The **stomach** revealed shadowing material, consistent with foreign body, measuring approximately 3.0 cm. Minor amount of gastric stasis noted in addition to the shadowing structure.

Pancreas

Slight heterogeneous **pancreatic** changes noted.



PATIENT

Bella Kuch

SPECIES

Canine

BREED

American Pit Bull

SEX

Spayed Female

AGE

8 Years

WEIGHT

55.8 Pounds

INTERPRETED BY

Eric Lindquist, DMV

DABVP, Cert. IVUSS

IMAGING PERFORMED BY

Dr. Michelle Bartus

HOSPITAL NAME

Valley Vet Service

REFERRING VET

Dr. Michelle Bartus

INVOICE

41776

DATE

9/29/22

ULTRASONOGRAPHIC FINDINGS

- Pyloric foreign matter
- Metabolic hepatopathy
- Unremarkable abdomen otherwise

INTERPRETATION OF THE FINDINGS & FURTHER RECOMMENDATIONS

Assuming the patient was NPO, endoscopy or more likely gastrotomy indicated. Liver biopsy, manual expression of the gallbladder and left adrenalectomy also indicated. Left adrenalectomy is optimal, especially if hypertension is present and/or if underlying Cushing's is present. The left adrenal could be consistent with hyperplasia, mild potential for carcinoma or pheochromocytoma. SDEP #13 approach to the pyloric outflow recommended just prior to surgery to ensure that the gastric material is persistently present and has not been evacuated.

Efficient & Accurate Cushing's Work up-Lindquist

Notes regarding Cushing's Clinical Presentations:

Nearly all Cushing's dogs have SAP elevations and true PU/PD (USG < 1.025) and most are polyphagic. Cushing's dogs are > 6 years and usually > 9 years old, usually have poor skin coats, body scores > 3/5, and are usually sedentary animals.

Its important to remember that Cushing's dogs usually look and play the part and other diseases cause false + stress related cortisol spikes. On rare occasion a Cushing's dog will not follow the rules but this is truly an exception.

Potential Cushing's patient workups can be costly and frustrating if not definitive and, in my experience, the non-definitive patient usually has something else going on that may be contributing to some of the clinical signs a Cushing's dog will have, especially SAP elevations or PU/PD. Based on this prelude of information I came up with the following algorithm in the spirit of diagnostic efficiency.

The following suggested protocol is based on current available literature on Cushing's disease and extensive clinical-sonographic experience evaluation + Cushing's and False + LDDST & ACTH stim. cases in order to maximize the efficiency of a Cushing's workup in practice.

Screen first, workup second

1) **UA:** Repeatable (2-3 urine samples) Urine specific gravity & urine cortisol/creatinine ratio (UCCR): If **repeatable USG < 10.20 and + UCCR** move to next step 2.

Note: UA is inexpensive and easy to obtain and if UA criteria is not met for Cushing's then resources can be spent into other more pertinent diagnostics or left on hold until the UA criteria is met in emerging Cushing's cases.

2) **Sonogram:** Does the patient **have concurrent disease** clinically or sonographically as non-Cushing's illness will influence the potential false + LDDST or even ACTH stim. The sonogram gives a global perspective of the internal health of the patient to be considered in the Cushing's workup as an assessment of concurrent disease. Is there a concurrent neoplastic process, UTI pancreatitis, mucocele....? Are the adrenals enlarged (Cushing's-PDH, stress, age related or breed variant), or atrophied (iatrogenic Cushing's or adrenal burnout), have asymmetric enlargement (Adrenal tumor, hyperplasia, adenoma, age related variant), or is there vascular invasion (Invasive pheo with false + UA criteria or adenocarcinoma or phrenic thrombosis)? The sonogram answers these questions proactively.

3) **LDDST** (0.01 D-Sodium phosphate mg/kg IV) (Better screening test but plagued with false +) Use if there is potential early Cushing's or if adrenal asymmetry present on sonogram suspecting tumor. Use LDDST in cats at a higher dose (0.1 mg/kg IV).



PATIENT

Bella Kuch

SPECIES

Canine

BREED

American Pit Bull

SEX

Spayed Female

AGE

8 Years

WEIGHT

55.8 Pounds

INTERPRETED BY

Eric Lindquist, DMV
DABVP, Cert. IVUSS

IMAGING PERFORMED BY

Dr. Michelle Bartus

HOSPITAL NAME

Valley Vet Service

REFERRING VET

Dr. Michelle Bartus

INVOICE

41776

DATE

9/29/22

OR

4) **ACTH stim.** (Better confirming test but can have false +) Use if the patient “looks” Cushingoid or if bilateral adrenal enlargement is present, or high normal width on sonogram, or if iatrogenic Cushing’s suspected (Cortisone Tx in past).

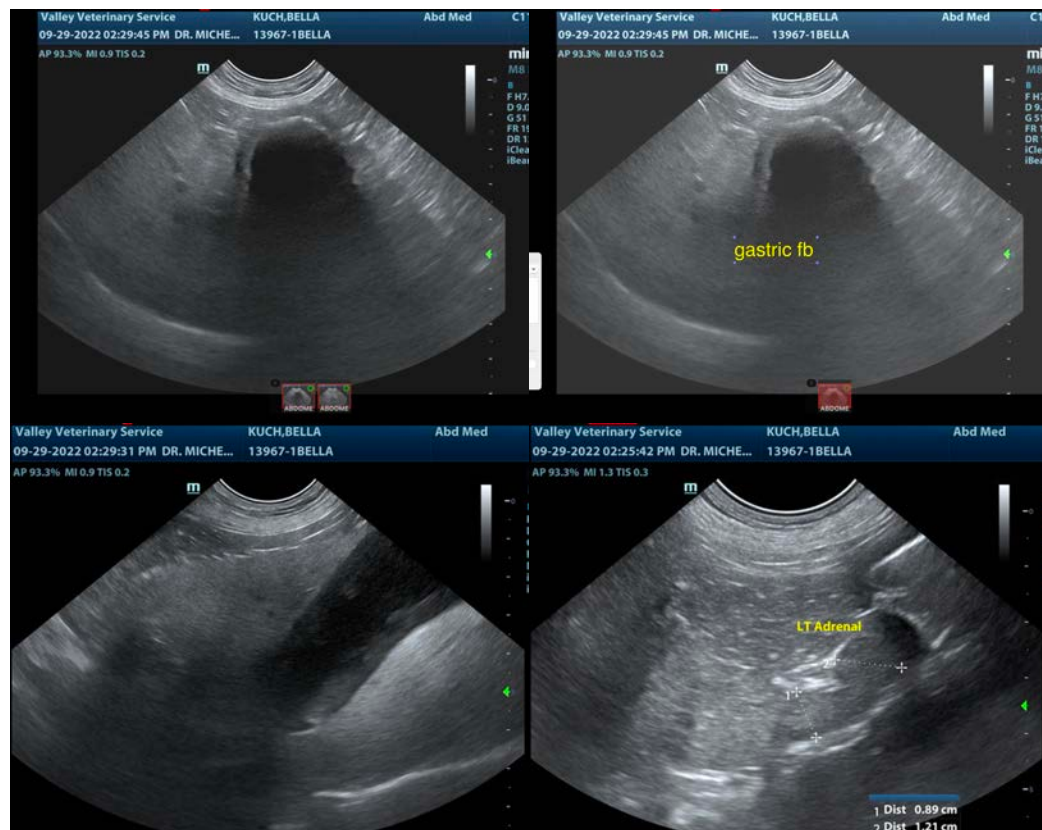
5) If **diabetic** then run both LDDST & ACTH stim.

5) Run a **serial blood pressure** in a BP friendly non “white coat effect” atmosphere. Run at least 3 at different times over a few hours or when eating as the patient tends to be calm when eating or give Torbutrol when entering the facility.

6) **Perform CT** of the pituitary to identify macro adenoma expansion if any lethargy or dullness or other central clinical CNS signs are minimally present.

Suggested reading:

Behrend EN, Kooistra HS, Nelson R, et al. Diagnosis of Spontaneous Canine Hyperadrenocorticism: 2012 ACVIM Consensus Statement (Small Animal). J Vet Intern Med 2013;27:1292–1304.





PATIENT

Bella Kuch

SPECIES

Canine

BREED

American Pit Bull

SEX

Spayed Female

AGE

8 Years

WEIGHT

55.8 Pounds

INTERPRETED BY

Eric Lindquist, DMV
DABVP, Cert. IVUSS

IMAGING PERFORMED BY

Dr. Michelle Bartus

HOSPITAL NAME

Valley Vet Service

REFERRING VET

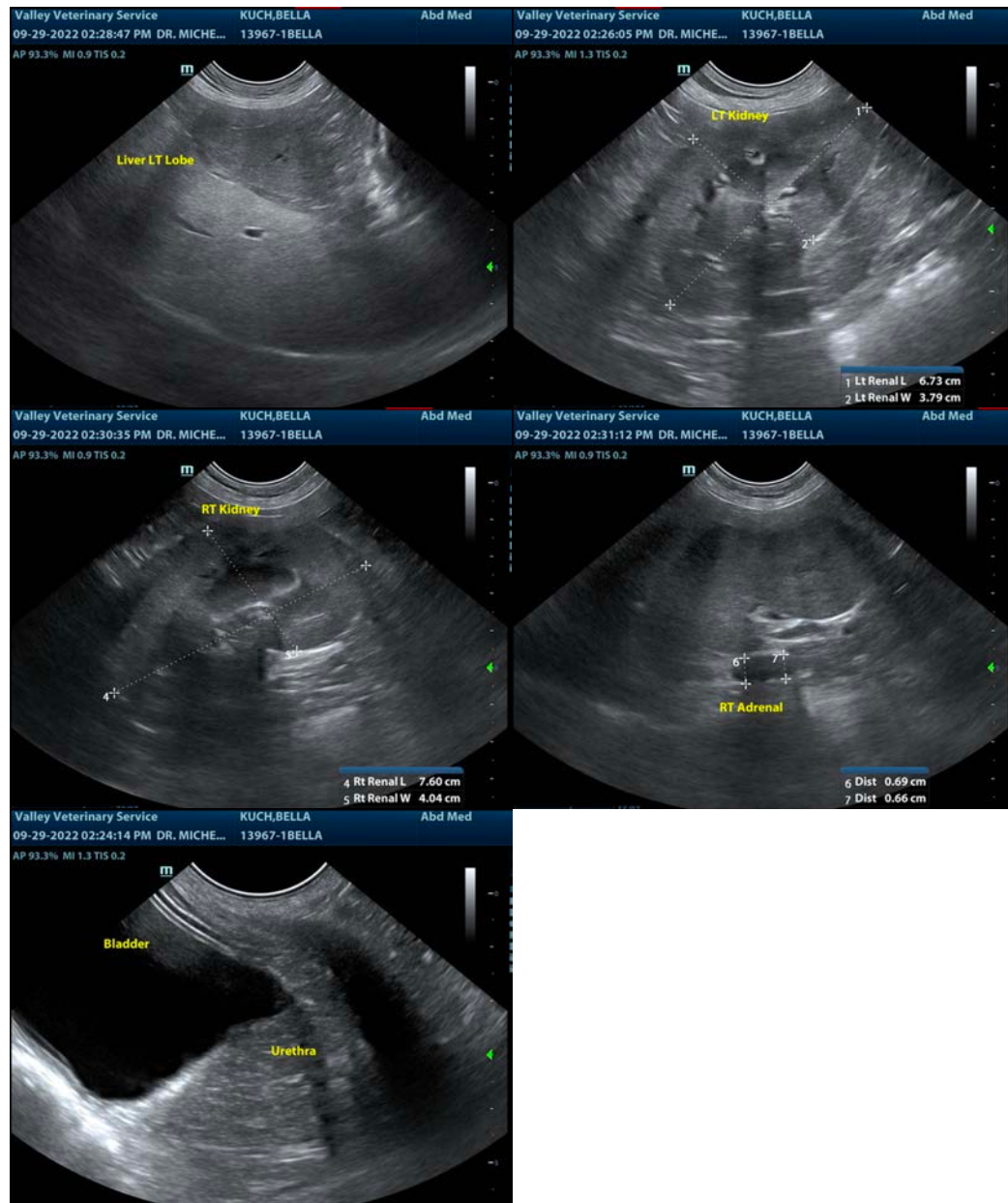
Dr. Michelle Bartus

INVOICE

41776

DATE

9/29/22



The information and recommendations provided are based on the images presented by the referring veterinarian/sonographer. No evaluation can be communicated regarding pathology that was not visible in the image/video clips provided.

Thank you for this referral. If the clinical or image interpretation does not parallel your findings or if I can be of any further assistance please contact me.

Eric Lindquist, DMV, DABVP, Cert. IVUSS, CEO of SonoPath.com

info@SonoPath.com