



PATIENT

Patch Bauer

SPECIES

Canine

BREED

Golden Retriever Mix

SEX

Intact male

AGE

12 years

WEIGHT

80 lbs

INTERPRETED BY

Eric Lindquist, DMV
DABVP, Cert. IVUSS

IMAGING PERFORMED BY

CHaley Hunt LVT

HOSPITAL NAME

Columbia AC

REFERRING VET

Dr. Engel

INVOICE

92083

DATE

9/29/21

PRESENTING CLINICAL SIGNS

History: History of elevated liver enzymes for a couple of years.
Abnormal PE/Chem/CBC/UA Results: 8/24/21: ALT = 136, ALKP = 1027 Borderline low T4 (0.8)

ULTRASONOGRAPHIC EXAMINATION OF THE ABDOMEN

Urinary System

The **bladder** in this patient was mildly thickened with slight echogenic mural changes. No calculi or masses were noted. Slight micropolypoid changes were noted. This is a frequent finding in older animals and may be linked to a history of chronic urinary tract infection or active urinary tract infection. Urinalysis would be recommended with culture if any evidence of inflammatory sediment is present. The region of the trigone and visible pelvic urethra were normal.

The **prostate** was uniformly enlarged with lobar swelling appeared to impinge upon the urethra and mildly deviate the descending colon. The prostatic tissue was hyperechoic containing focal areas of decreased echogenicity. These changes are suggestive of either chronic inflammatory episodes, benign cystic pathology or both. Underlying neoplasia cannot be completely ruled-out but is lower on the differential list. This presentation is most consistent with benign prostatic hyperplasia with possible active prostatitis. Neutering or off-label Finasteride (Propecia) (0.1-0.5 mg/kg Sid) treatment is indicated +/- FNA or prostatic wash cytology and culture. The prostate measured 4.5 cm.

The **kidneys** revealed largely normal size and structure, corticomedullary definition and ratio (cortex 1/3 of medulla) were essentially maintained with some age-related loss of curvilinear patterns regarding the capsule and C/M junction. The cortices presented largely uniform texture with some increased echogenicity expected for this age patient. Medullary structure differed distinctly from that of the cortex and no evidence of pelvic dilation was present. The left kidney measured 6.95 cm. The right kidney measured 6.65 cm.

Adrenal Glands

The right **adrenal gland** was mildly heterogenous and at the upper limits of normal measuring 1.3 cm at the cranial pole and 1.1 cm at the caudal pole. However, there is no suspected pathology. The left adrenal gland measured 0.6 cm.

Spleen

The **spleen** presented a smooth homogeneous parenchyma hyperechoic to liver and renal cortical parenchyma. The capsule was smooth without noticeable expansion or deviation from within the spleen or adjacent pathology. The splenic vasculature demonstrated normal volume without signs of congestion or thrombosis. No sonographic evidence of acute or chronic inflammatory, neoplastic, or infarctual changes was noted.

Liver

The **liver** images submitted revealed subjectively normal liver size, contour, and structure. Parenchymal echogenicity was naturally coarse and hypoechoic to the spleen. Vascular and biliary tracts were of normal volume with no evidence of congestion. The gallbladder presented acceptably thin walls with



PATIENT

Patch Bauer

primarily anechoic content. The cystic and common bile ducts were normal. No pathological hepatic lymphadenopathy was evident. No overt structural evidence of inflammatory, infiltrative or regenerative pathology was evident.

SPECIES

Canine

Gastrointestinal

Examination of the **gastrointestinal tract** revealed a stomach and intestine free of stasis, of normal wall thickness, acceptable curvilinear mural detail, and peristaltic activity. Small and large intestine demonstrated normal luminal chyme and stool consistency respectively. No obstructive or overt infiltrative disease was noted. No associated abnormal lymphatic activity was noted.

BREED

Golden Retriever Mix

SEX

Intact male

Pancreas

The base and limbs of the **pancreas** were observed to be largely isoechoic to surrounding omental fat. Pancreatic duct and capsular contour were acceptably normal and parenchyma respected normal curvilinear patterns. No overt evidence of active inflammatory or neoplastic disease was noted.

AGE

12 years

ULTRASONOGRAPHIC FINDINGS

WEIGHT

80 lbs

Geriatric abdomen.

Benign hepatopathy.

INTERPRETED BY

Eric Lindquist, DMV
DABVP, Cert. IVUSS

INTERPRETATION OF THE FINDINGS & FURTHER RECOMMENDATIONS

There is no evidence of significant disease. If hypertension is present and the patient appears Cushingoid then a recheck of the adrenal glands primarily of the right adrenal gland is recommended in a month.

IMAGING PERFORMED BY

CHaley Hunt LVT

HOSPITAL NAME

Columbia AC

REFERRING VET

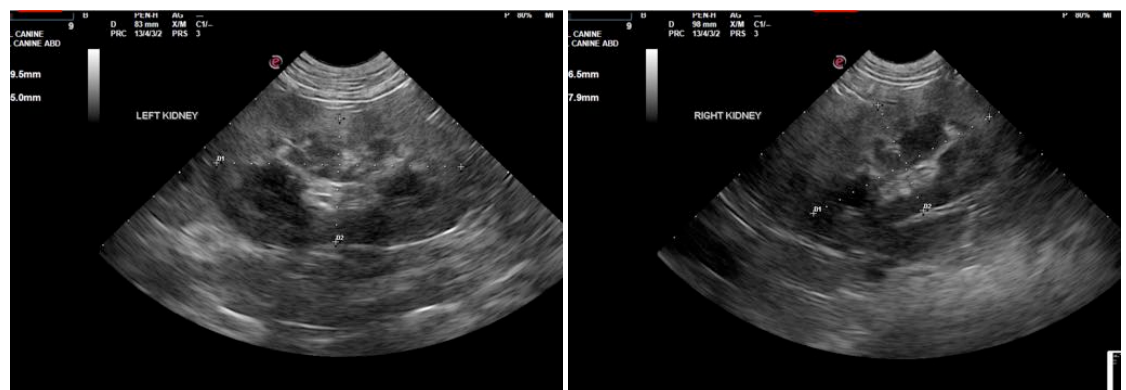
Dr. Engel

INVOICE

92083

DATE

9/29/21





PATIENT

Patch Bauer

SPECIES

Canine

BREED

Golden Retriever Mix

SEX

Intact male

AGE

12 years

WEIGHT

80 lbs

INTERPRETED BY

Eric Lindquist, DMV
DABVP, Cert. IVUS

IMAGING PERFORMED BY

CHaley Hunt LVT

HOSPITAL NAME

Columbia AC

REFERRING VET

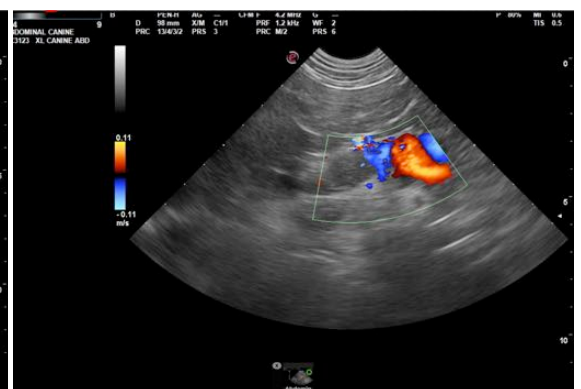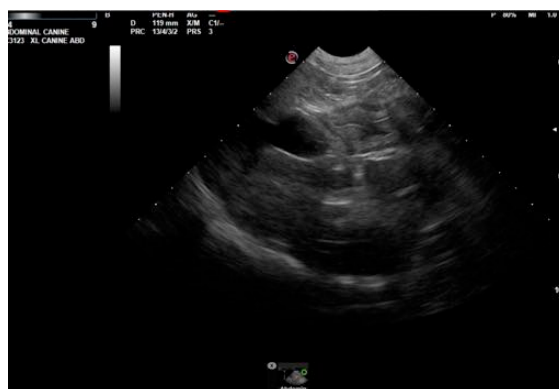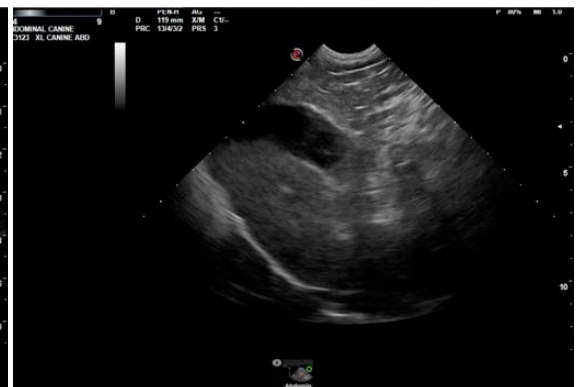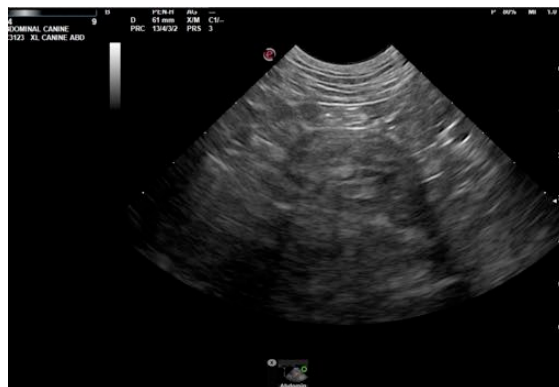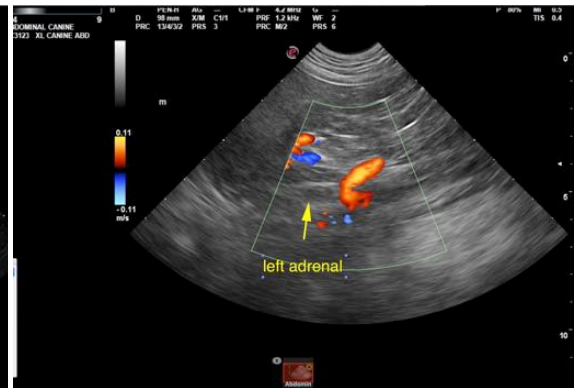
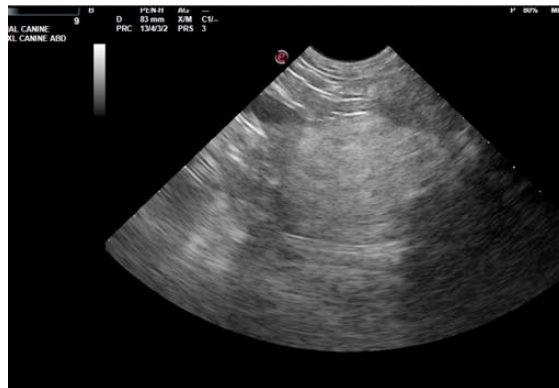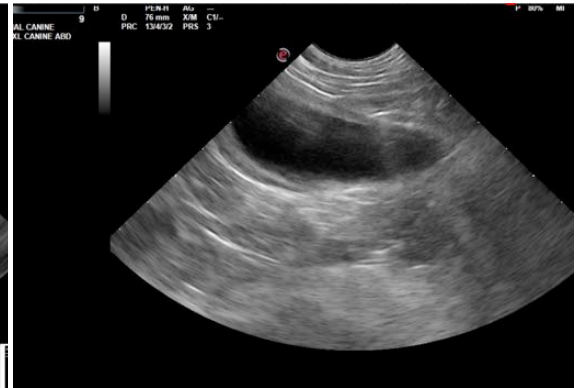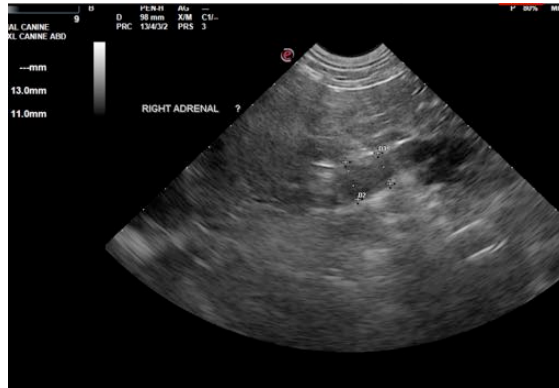Dr. Engel

INVOICE

92083

DATE

9/29/21





PATIENT

Patch Bauer

The information and recommendations provided are based on the images presented by the referring veterinarian. No evaluation can be communicated regarding pathology that was not visible in the image/video clips provided.

SPECIES

Canine

Thank you for this referral. If the clinical or image interpretation does not parallel your findings or if I can be of any further assistance please contact me.

BREED

Golden Retriever Mix

Eric Lindquist, DMV, DABVP, Cert. IVUSS, CEO of SonoPath.com
info@SonoPath.com

SEX

Intact male

AGE

12 years

WEIGHT

80 lbs

INTERPRETED BY

Eric Lindquist, DMV
DABVP, Cert. IVUSS

**IMAGING
PERFORMED BY**

CHaley Hunt LVT

HOSPITAL NAME

Columbia AC

REFERRING VET

Dr. Engel

INVOICE

92083

DATE

9/29/21