



PATIENT PRESENTING CLINICAL SIGNS

Chester Crane History: recheck

SPECIES ULTRASONOGRAPHIC EXAMINATION OF THE ABDOMEN

Canine **Urinary System**

BREED

French Bulldog

The **urinary bladder**, trigone, and pelvic urethra presented normal thicknesses and normal tone. The pelvic urethra was imaged 2.0 cm beyond the cystourethral junction. The ureters were not visible which is normal. No uroliths or sediment were visualized and anechoic urine was present. No evidence of inflammatory or neoplastic changes was noted. Ureteral papillae were normal.

SEX

Neutered male

The **kidneys** revealed normal size and structure, corticomedullary definition and ratio for this age. The cortices presented largely uniform texture with normal echogenic relationship to liver and spleen. Medullary structure differed distinctly from the cortex and no evidence of pelvic dilation was present. The capsules were acceptably uniform without significant irregularities. The left kidney measured 4.52 cm. The right kidney measured 4.14 cm.

AGE

3 years

Adrenal Glands

WEIGHT

28 lbs

Both **adrenal glands** were visualized and recognized as having normal shape, size, position and echogenicity for this breed. The phrenic vasculature, glandular echogenicity and detail were unremarkable. Capsule, cortex, and medullary definition were normal for this age patient.

INTERPRETED BY

Eric Lindquist, DMV
DABVP, Cert. IVUSS

Spleen

The **spleen** presented a smooth homogeneous parenchyma hyperechoic to liver and renal cortical parenchyma. The capsule was smooth without noticeable expansion or deviation from within the spleen or adjacent pathology. The splenic vasculature demonstrated normal volume without signs of congestion or thrombosis. No sonographic evidence of acute or chronic inflammatory, neoplastic, or infarctual changes was noted.

IMAGING PERFORMED BY

Jenn

HOSPITAL NAME

Rockaway AH

Liver

The **liver** images submitted revealed subjectively normal liver size, contour, and structure. Parenchymal echogenicity was naturally coarse and hypoechoic to the spleen. Vascular and biliary tracts were of normal volume with no evidence of congestion. The gallbladder presented acceptably thin walls with primarily anechoic content. The cystic and common bile ducts were normal. No pathological hepatic lymphadenopathy was evident. No overt structural evidence of inflammatory, infiltrative or regenerative pathology was evident.

REFERRING VET

Dr. Maniar

INVOICE

92054

Gastrointestinal

The **stomach** was filled with ingesta. The small intestine was empty and unremarkable.

DATE

9/29/21



PATIENT

Pancreas

Chester Crane

The base and limbs of the **pancreas** were observed to be largely isoechoic to surrounding omental fat. Pancreatic duct and capsular contour were acceptably normal and parenchyma respected normal curvilinear patterns. No overt evidence of active inflammatory or neoplastic disease was noted.

SPECIES

Canine

ULTRASONOGRAPHIC FINDINGS

BREED

French Bulldog

Currently full stomach, possible newly ingested foreign matter. However, delayed outflow pattern is suggested depending on when the patient ate prior to the sonogram.

SEX

Neutered male

INTERPRETATION OF THE FINDINGS & FURTHER RECOMMENDATIONS

No specific therapy is recommended.

AGE

3 years

WEIGHT

28 lbs

INTERPRETED BY

Eric Lindquist, DMV
DABVP, Cert. IVUSS

IMAGING PERFORMED BY

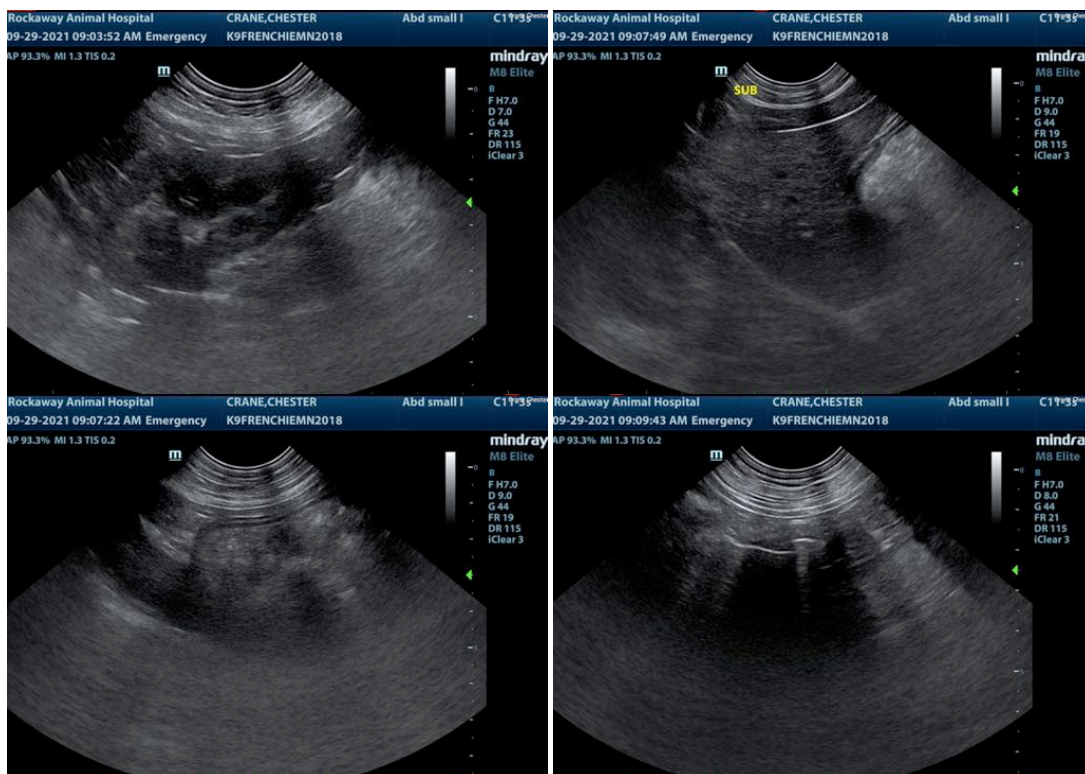
Jenn

HOSPITAL NAME

Rockaway AH

REFERRING VET

Dr. Maniar



INVOICE

92054

DATE

9/29/21



PATIENT

Chester Crane

SPECIES

Canine

BREED

French Bulldog

SEX

Neutered male

AGE

3 years

WEIGHT

28 lbs

INTERPRETED BY

Eric Lindquist, DMV
DABVP, Cert. IVUSS

**IMAGING
PERFORMED BY**

Jenn

HOSPITAL NAME

Rockaway AH

REFERRING VET

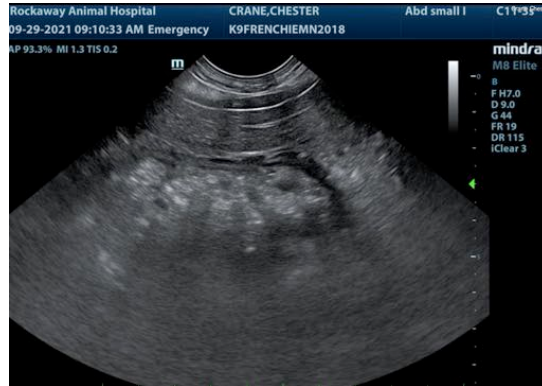Dr. Maniar

INVOICE

92054

DATE

9/29/21



The information and recommendations provided are based on the images presented by the referring veterinarian. No evaluation can be communicated regarding pathology that was not visible in the image/video clips provided.

Thank you for this referral. If the clinical or image interpretation does not parallel your findings or if I can be of any further assistance please contact me.

Eric Lindquist, DMV, DABVP, Cert. IVUSS, CEO of SonoPath.com
info@SonoPath.com