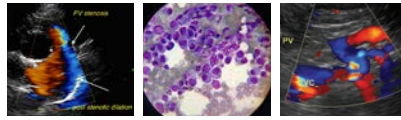


IMAGING PERFORMED BY

IntraPet.com



**SonoPath**

Clinical Sonography & Telecytology

EDUCATIONAL TELECONSULTATION SERVICES™

1-800-838-4268 info@sonopath.com SonoPath.com

**DATE**

9/28/22

**PATIENT**

Opie Cutler

**SPECIES**

Canine

**BREED**

Yorke-Poo

**SEX**

Neutered Male

**AGE**

12/26/16

**WEIGHT**

11.4 Pounds

**INTERPRETED BY**

Eric Lindquist, DMV  
DABVP, Cert. IVUSS

**IMAGING PERFORMED BY**

Rachel Brilhart RDMS

**HOSPITAL NAME**

Mt. Airy AH

**REFERRING VET**

Dr. Riley

**INVOICE**

41729

**PRESENTING CLINICAL SIGNS**

Intermittent seizures, elevated ALT (716), ST (318) and GGT (20). PU/PD.

Current Medications: Gabapentin 100mg BID.  
Date of Previous IntraPet Ultrasound: No previous.  
Sedation: Not required to complete full diagnostic ultrasound.  
Stat Report: Not requested.

**ULTRASONOGRAPHIC EXAMINATION OF THE ABDOMEN**

**Urinary System**

The **urinary bladder**, trigone, and pelvic urethra presented normal thicknesses and normal tone. The ureters were not visible which is normal. No uroliths or sediment were visualized and anechoic urine was present. No evidence of inflammatory or neoplastic changes were noted. Ureteral papillae were normal.

The **kidneys** revealed normal size and structure, corticomedullary definition and ratio for this age. The cortices presented largely uniform texture with normal echogenic relationship to liver and spleen. Medullary structure differed distinctly from the cortex and no evidence of pelvic dilation was present. The capsules were acceptably uniform without significant irregularities. The left kidney measured 3.77 cm. The right kidney measured 3.57 cm.

**Adrenal Glands**

Both **adrenal glands** were visualized and recognized as having normal shape, size, position and echogenicity for this breed. The phrenic vasculature, glandular echogenicity and detail were unremarkable. Capsule, cortex, and medullary definition were normal for this age patient. The left adrenal gland measured 1.63 cm x 0.57 cm at the caudal pole and 0.45 cm at the cranial pole. The right adrenal gland measured 1.53 cm x 0.57 cm at the caudal pole and 0.59 cm at the cranial pole.

**Spleen**

The **spleen** presented a smooth homogeneous parenchyma hyperechoic to liver and renal cortical parenchyma. The capsule was smooth without noticeable expansion or deviation from within the spleen or adjacent pathology. The splenic vasculature demonstrated normal volume without signs of congestion or thrombosis. No sonographic evidence of acute or chronic inflammatory, neoplastic, or infarctual changes were noted.

**Liver**

The **liver** presented mild increased portal markings and coarse architecture. The liver was slightly subnormal in size at 3.4 cm. The gallbladder and common bile duct were unremarkable. No evidence of intrahepatic or extrahepatic shunting. Portal vein to vena cava ratio was 1:1. The portal vein was normal in width at 0.57 cm.

**Gastrointestinal**

Examination of the **gastrointestinal tract** revealed a stomach and intestine free of stasis, of normal wall thickness, acceptable curvilinear mural detail, and peristaltic activity. Small and large intestine demonstrated normal luminal chyme and stool consistency respectively. No obstructive or overt infiltrative disease was noted. No associated abnormal lymphatic activity was noted.

**Pancreas**

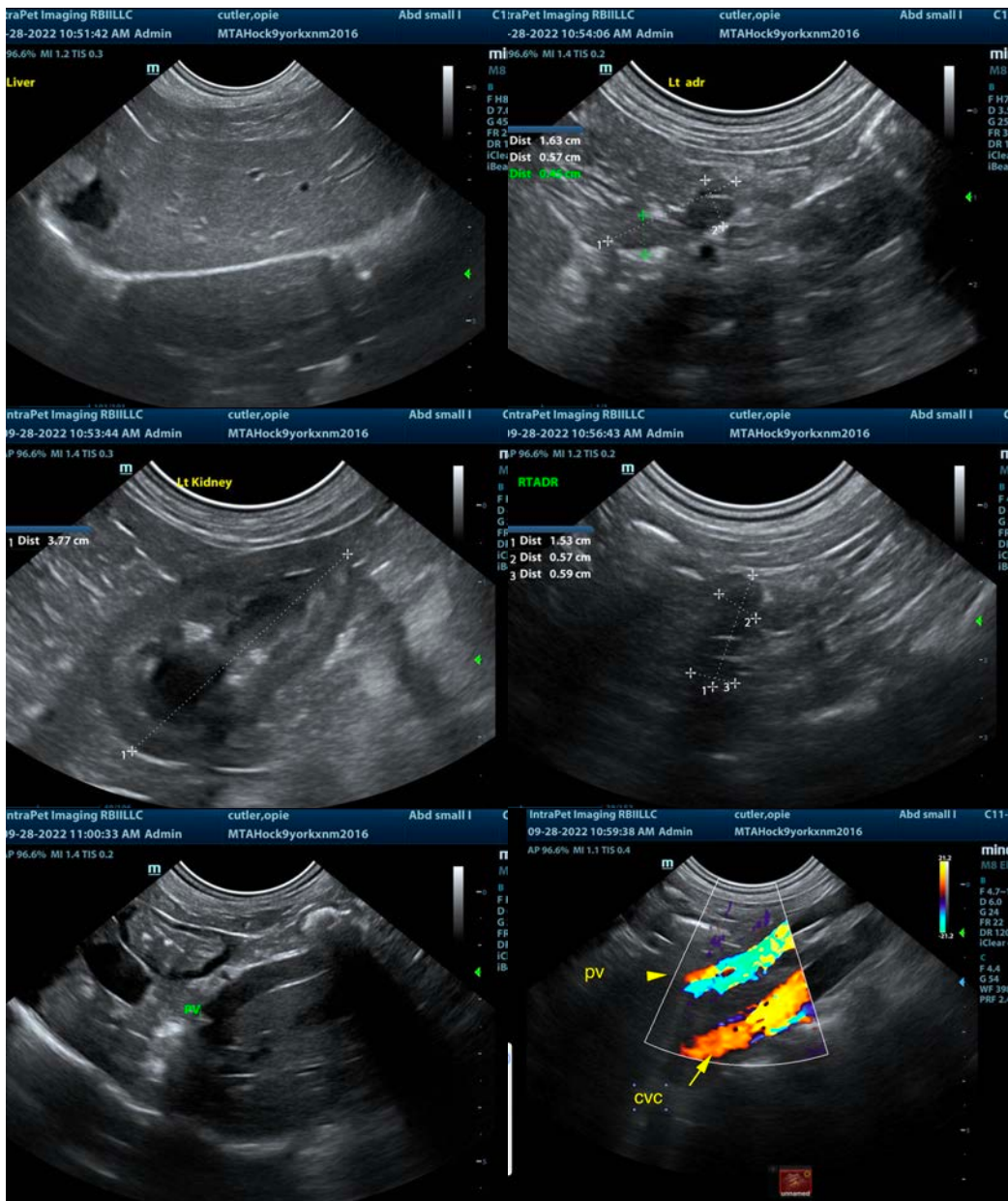
The base and limbs of the **pancreas** were observed to be largely isoechoic to surrounding omental fat. Pancreatic duct and capsular contour were acceptably normal and parenchyma respected normal curvilinear patterns. No overt evidence of active inflammatory or neoplastic disease was noted.

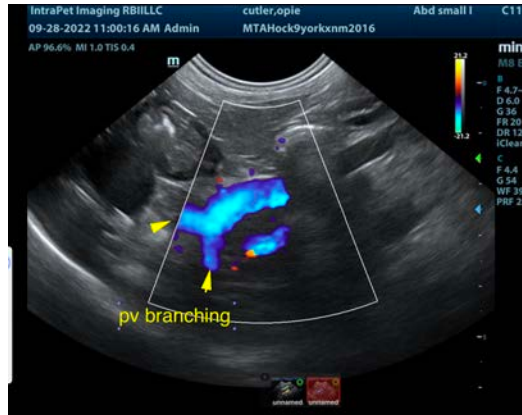
## ULTRASONOGRAPHIC FINDINGS

- Mild microhepatica and non-specific remodeling, no evidence of intrahepatic or extrahepatic shunting

## INTERPRETATION OF THE FINDINGS & FURTHER RECOMMENDATIONS

Non-specific chronic inflammatory hepatopathy. Leptospirosis titers warranted. Core liver biopsy warranted. Bile acid profile warranted. Quantitative copper evaluation warranted upon biopsy as well as to assess for portal hypoplasia/microvascular dysplasia.





The information and recommendations provided are based on the images presented by the referring veterinarian/sonographer. No evaluation can be communicated regarding pathology that was not visible in the image/video clips provided.

Thank you for this referral. If the clinical or image interpretation does not parallel your findings or if I can be of any further assistance please contact me.

**Eric Lindquist**, DMV, DABVP, Cert. IVUSS, CEO of SonoPath.com  
[info@SonoPath.com](mailto:info@SonoPath.com)