


PATIENT

Nate Dawg Spring

SPECIES

Canine

BREED

Boxer Cross

SEX

Neutered male

AGE

13 years

WEIGHT

62 lbs

INTERPRETED BY

 Eric Lindquist, DMV
 DABVP, Cert. IVUSS

IMAGING PERFORMED BY

Dr. Gunther

HOSPITAL NAME

 New Frontier Animal
 Medical Center

REFERRING VET

Dr. Gunther

INVOICE

39681

DATE

9/28/22

PRESENTING CLINICAL SIGNS

 History: Diagnosed with MMVD/MTVD in March 2022 Started on Vetmedin Asymptomatic Sleeping
 Respiratory Rate normal

ULTRASONOGRAPHIC EXAMINATION OF THE HEART

The echocardiogram in this patient revealed improved atrial size with persistent mitral insufficiency. The contractility was normal. The left atrial size was normal in all three parameters. No pericardial or pleural effusion was noted. All four chambers are normal in size. Trivial tricuspid insufficiency was noted, yet not clinically significant.

CANINE CARDIAC PARAMETERS	MR VMAX (m/s)	TR VMAX (m/s)	LA/AO (Boon method)	LA/AO (Heart Base; Swe)	FS (%)	EF (%)	EPSS (cm)
NORMAL PARAMETER	4.5-5.5	<2.7	1.3	<1.6	28-40	40-100	<0.6
PATIENT			1.14	1.58			0.33
CANINE CARDIAC PARAMETERS	HR (BPM)	AV VMAX (m/s)	PV MAX (m/s)	BODY WEIGHT	LA 2D short axis Base view (cm)	LVIDd Avg; 2D and m- mode short axis (cm)	LVIDs Avg; 2D and m-mode short axis (cm)
NORMAL PARAMETER	50-100	0.7-1.7	0.7-1.6	BELOW	BELOW	BELOW	BELOW
PATIENT		1.8	0.8	62 lbs	4.7		

ULTRASONOGRAPHIC FINDINGS

Stable valvular disease on current protocol.

INTERPRETATION OF THE FINDINGS & FURTHER RECOMMENDATIONS

Recheck echocardiogram is recommended in 6 months.



PATIENT

Nate Dawg Spring

SPECIES

Canine

BREED

Boxer Cross

SEX

Neutered male

AGE

13 years

WEIGHT

62 lbs

INTERPRETED BY

Eric Lindquist, DMV
DABVP, Cert. IVUS

IMAGING PERFORMED BY

Dr. Gunther

HOSPITAL NAME

New Frontier Animal
Medical Center

REFERRING VET

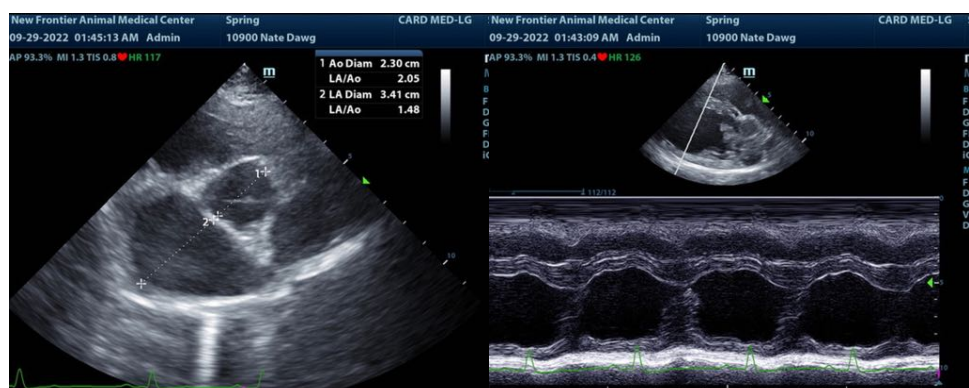
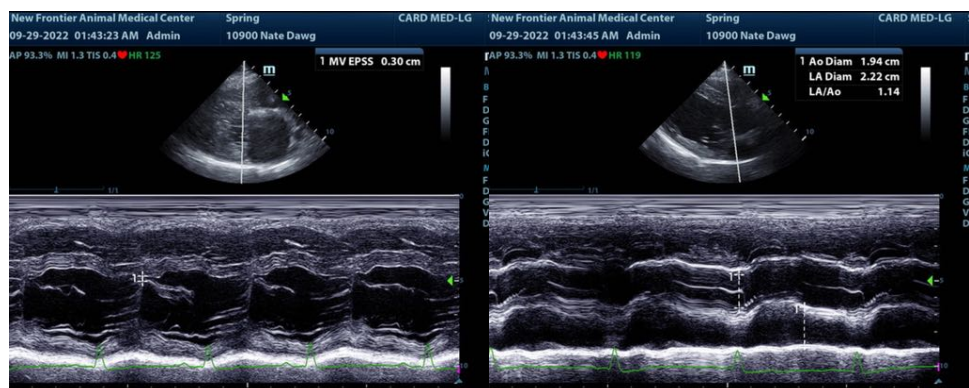
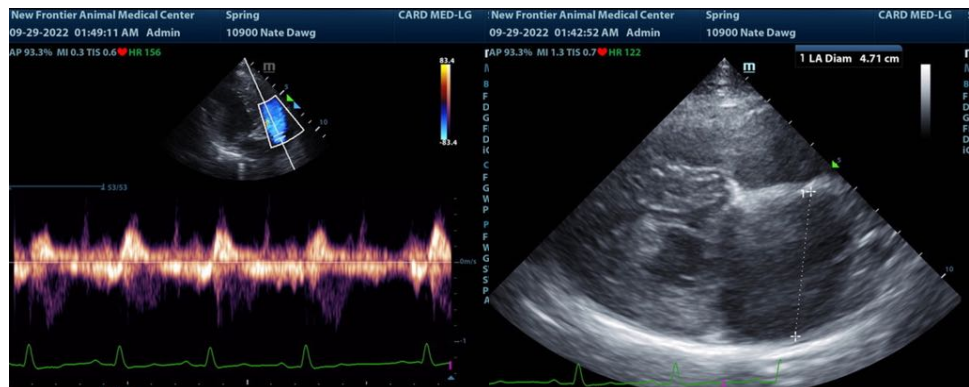
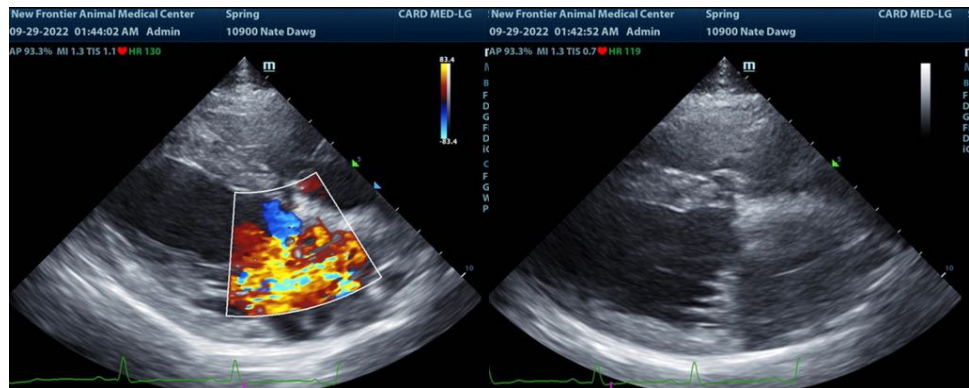
Dr. Gunther

INVOICE

39681

DATE

9/28/22





PATIENT

Nate Dawg Spring

The information and recommendations provided are based on the images presented by the referring veterinarian/sonographer. No evaluation can be communicated regarding pathology that was not visible in the image/video clips provided.

SPECIES

Canine

Thank you for this referral. If the clinical or image interpretation does not parallel your findings or if I can be of any further assistance please contact me.

BREED

Boxer Cross

Eric Lindquist, DMV, DABVP, Cert. IVUSS, CEO of SonoPath.com
info@SonoPath.com

SEX

Neutered male

AGE

13 years

WEIGHT

62 lbs

INTERPRETED BY

Eric Lindquist, DMV
DABVP, Cert. IVUSS

**IMAGING
PERFORMED BY**

Dr. Gunther

HOSPITAL NAME

New Frontier Animal
Medical Center

REFERRING VET

Dr. Gunther

INVOICE

39681

DATE

9/28/22