



PATIENT

Hana Blanchard

SPECIES

Canine

BREED

Boston Terrier

SEX

Spayed female

AGE

11 years

WEIGHT

24 lbs

INTERPRETED BY

Eric Lindquist, DMV
DABVP, Cert. IVUSS

IMAGING PERFORMED BY

Dr. Ebersole

HOSPITAL NAME

Scanvet

REFERRING VET

Dr. Peyser

INVOICE

39672

DATE

9/28/22

PRESENTING CLINICAL SIGNS

History: Elevated LE on routine BW. No clinical signs reported by owners.
Abnormal PE/Chem/CBC/UA Results: PE: mild potbelly appearance. ALP 1,362, ALT 208, GGT 17. Plt 727. Chol 392. USG 1.039, ph 5.5, urine protein 3+.

ULTRASONOGRAPHIC EXAMINATION OF THE ABDOMEN

Urinary System

The **urinary bladder**, trigone, and pelvic urethra presented normal thicknesses and normal tone. The ureters were not visible which is normal. No uroliths or sediment were visualized and anechoic urine was present. No evidence of inflammatory or neoplastic changes was noted. Ureteral papillae were normal.

The **kidneys** revealed normal size and structure, corticomedullary definition and ratio for this age. The cortices presented largely uniform texture with normal echogenic relationship to liver and spleen. Medullary structure differed distinctly from the cortex and no evidence of pelvic dilation was present. The capsules were acceptably uniform without significant irregularities. The right kidney measured 4.71 cm.

Adrenal Glands

Both **adrenal glands** were visualized and recognized as having normal shape, size, position and echogenicity for this breed. The phrenic vasculature, glandular echogenicity and detail were unremarkable. Capsule, cortex, and medullary definition were normal for this age patient. The right adrenal gland measured 0.71 cm at the caudal pole and 0.6 cm at the cranial pole. The left adrenal gland measured 0.69 cm at the caudal pole and 0.45 cm at the cranial pole.

Spleen

The **spleen** presented a smooth homogeneous parenchyma hyperechoic to liver and renal cortical parenchyma. The capsule was smooth without noticeable expansion or deviation from within the spleen or adjacent pathology. The splenic vasculature demonstrated normal volume without signs of congestion or thrombosis. No sonographic evidence of acute or chronic inflammatory, neoplastic, or infarctual changes was noted.

Liver

The **liver** images from right and left intercostal as well as subcostal views revealed subjectively normal liver size, contour, and structure. Some age-related parenchymal remodeling was noted but likely not clinically significant at this time. Vascular and biliary tracts were of normal volume and no evidence of congestion was noted. The gallbladder presented some dependent debris with essentially normal contour. The cystic and common bile ducts were normal. No overt evidence of active inflammatory, infiltrative or regenerative pathology was noted but should be paired with current or past LE elevations regarding any clinical significance to this presentation. The hepatic lymph nodes were unremarkable.



PATIENT

Gastrointestinal

Hana Blanchard

Examination of the **gastrointestinal tract** revealed a stomach and intestine free of stasis, of normal wall thickness, acceptable curvilinear mural detail, and peristaltic activity. Small and large intestine demonstrated normal luminal chyme and stool consistency respectively. No obstructive or overt infiltrative disease was noted. No associated abnormal lymphatic activity was noted.

SPECIES

Canine

BREED

Boston Terrier

Pancreas

The base and limbs of the **pancreas** were observed to be largely isoechoic to surrounding omental fat. Pancreatic duct and capsular contour were acceptably normal and parenchyma respected normal curvilinear patterns. No overt evidence of active inflammatory or neoplastic disease was noted.

SEX

Spayed female

ULTRASONOGRAPHIC FINDINGS

Hepatic remodeling, non-specific.

AGE

11 years

INTERPRETATION OF THE FINDINGS & FURTHER RECOMMENDATIONS

Low-grade inflammatory hepatopathy is likely. FNA could be considered for further definition. Bile acid profile would be ideal to assess any dysfunction; however, the changes were relatively mild.

WEIGHT

24 lbs

INTERPRETED BY

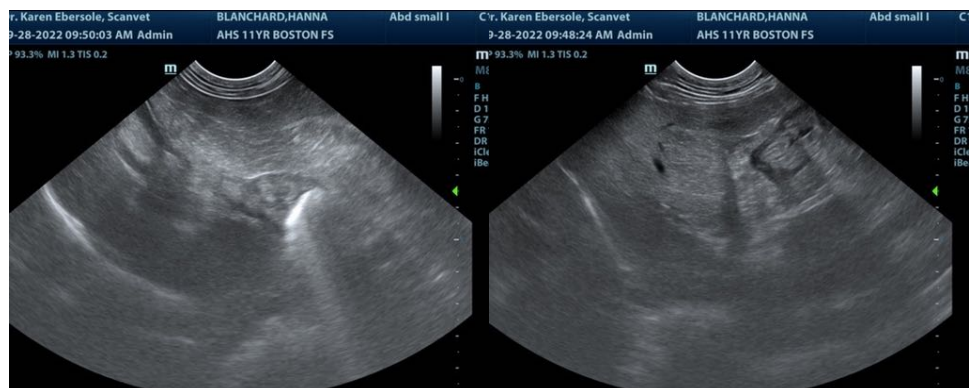
Eric Lindquist, DMV
DABVP, Cert. IVUS

IMAGING PERFORMED BY

Dr. Ebersole

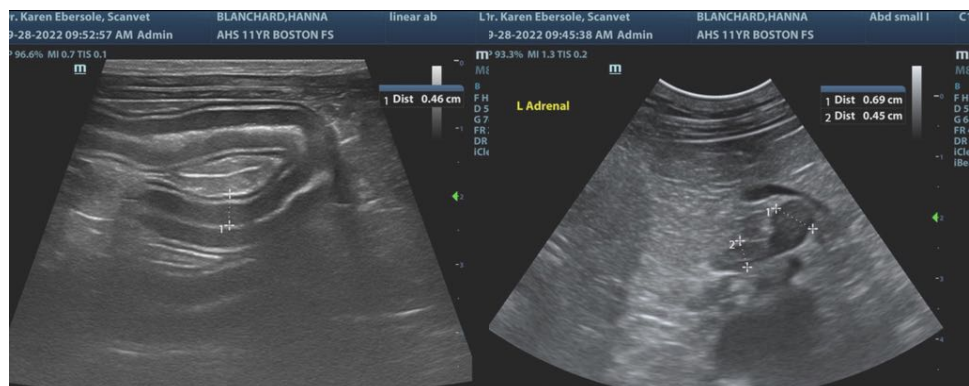
HOSPITAL NAME

Scanvet



REFERRING VET

Dr. Peyser



INVOICE

39672

DATE

9/28/22



PATIENT

Hana Blanchard

SPECIES

Canine

BREED

Boston Terrier

SEX

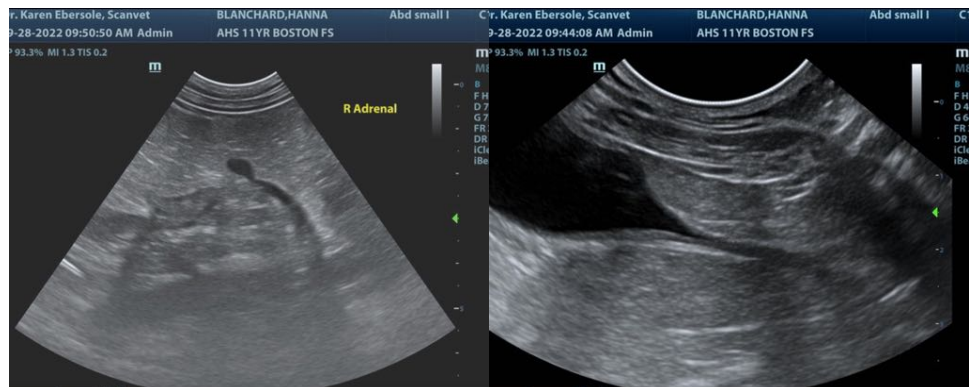
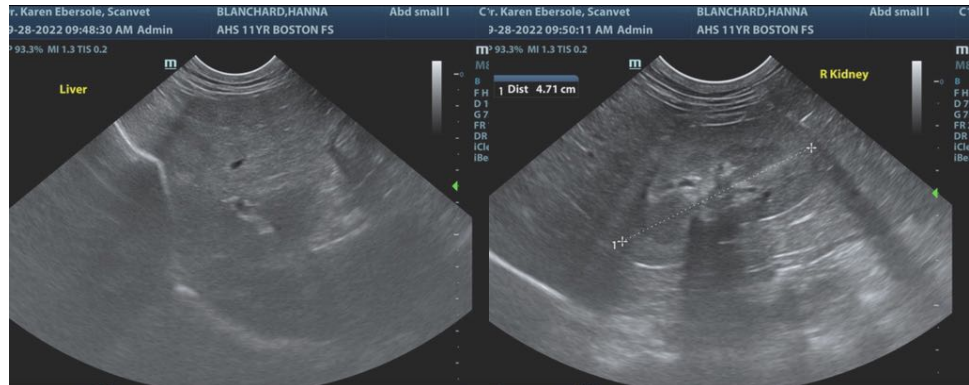
Spayed female

AGE

11 years

WEIGHT

24 lbs



INTERPRETED BY

Eric Lindquist, DMV
DABVP, Cert. IVUSS

IMAGING PERFORMED BY

Dr. Ebersole

HOSPITAL NAME

Scanvet

REFERRING VET

Dr. Peyser

INVOICE

39672

DATE

9/28/22

The information and recommendations provided are based on the images presented by the referring veterinarian/sonographer. No evaluation can be communicated regarding pathology that was not visible in the image/video clips provided.

Thank you for this referral. If the clinical or image interpretation does not parallel your findings or if I can be of any further assistance please contact me.

Eric Lindquist, DMV, DABVP, Cert. IVUSS, CEO of SonoPath.com
info@SonoPath.com