



PATIENT

Champion Guzman

SPECIES

Canine

BREED

Shih Tzu Mix

SEX

Neutered male

AGE

14 years

WEIGHT

6.4 lbs

INTERPRETED BY

Eric Lindquist, DMV
DABVP, Cert. IVUSS

IMAGING PERFORMED BY

Dr. Biederbeck

HOSPITAL NAME

Lomsnes VH

REFERRING VET

Dr. Biederbeck

INVOICE

39683

DATE

9/28/22

PRESENTING CLINICAL SIGNS

History: Ultrasound - spleen. age vs early neoplasia? *no weight loss Previous abd U/S done 6/28/22 and sent to you

ULTRASONOGRAPHIC EXAMINATION OF THE ABDOMEN

Spleen

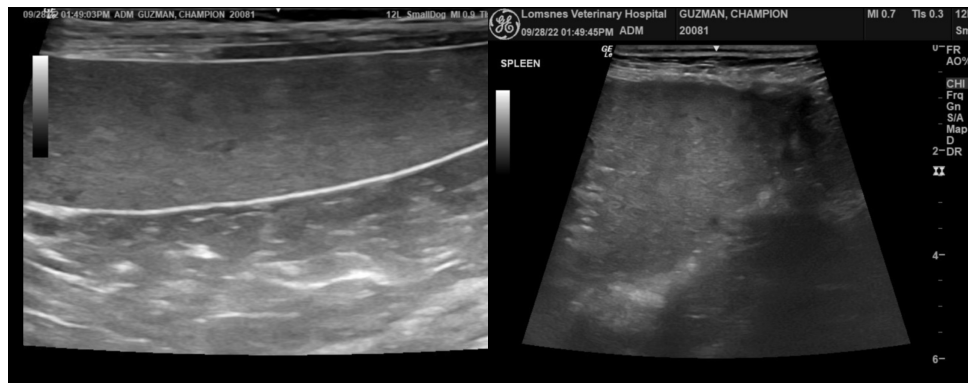
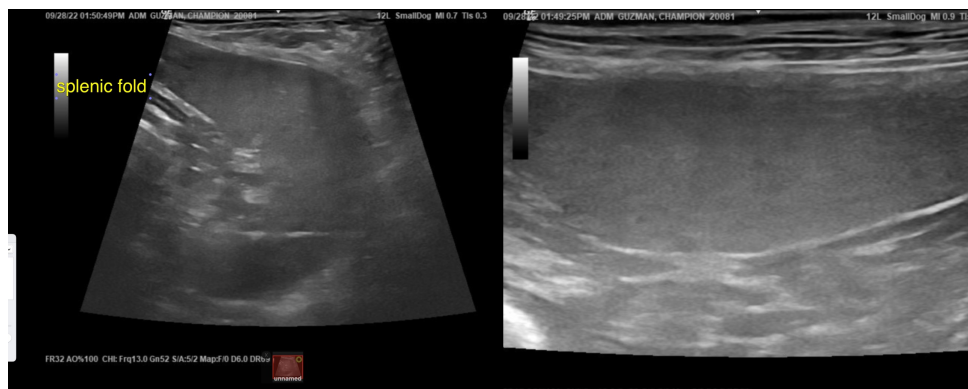
The **spleen** revealed subtle, micronodular changes. The capsular contour was maintained. The spleen was folded upon itself caudally. This is most consistent with nodular hyperplasia. FNA is indicated for further definition.

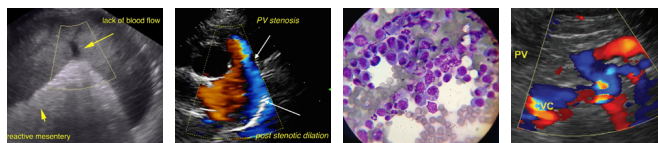
ULTRASONOGRAPHIC FINDINGS

Heterogenous spleen with normal positional variant to splenic fold.

INTERPRETATION OF THE FINDINGS & FURTHER RECOMMENDATIONS

Nodular hyperplasia pattern or reactive spleen. There is a minor potential for underlying neoplasia.





PATIENT

Champion Guzman

SPECIES

Canine

BREED

Shih Tzu Mix

SEX

Neutered male

AGE

14 years

WEIGHT

6.4 lbs

INTERPRETED BY

Eric Lindquist, DMV
DABVP, Cert. IVUSS

**IMAGING
PERFORMED BY**

Dr. Biederbeck

HOSPITAL NAME

Lomsnes VH

REFERRING VET

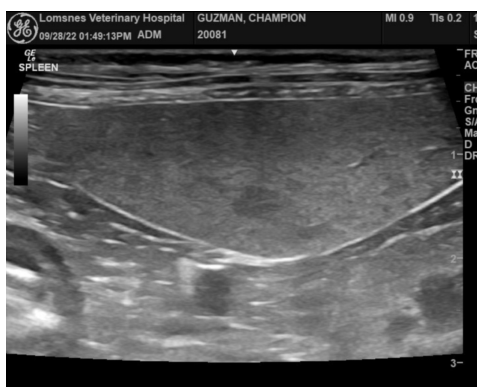Dr. Biederbeck

INVOICE

39683

DATE

9/28/22



The information and recommendations provided are based on the images presented by the referring veterinarian/sonographer. No evaluation can be communicated regarding pathology that was not visible in the image/video clips provided.

Thank you for this referral. If the clinical or image interpretation does not parallel your findings or if I can be of any further assistance please contact me.

Eric Lindquist, DMV, DABVP, Cert. IVUSS, CEO of SonoPath.com
info@SonoPath.com