



PATIENT

Bgatiatus Margaca

SPECIES

Canine

BREED

Labrador Mix

SEX

Neutered male

AGE

11 years

WEIGHT

58.6 lbs

INTERPRETED BY

Eric Lindquist, DMV
DABVP, Cert. IVUSS

IMAGING PERFORMED BY

Dr. Ferrer

HOSPITAL NAME

Paseos VC

REFERRING VET

Dr. Carrasquillo

INVOICE

39682

DATE

9/28/22

PRESENTING CLINICAL SIGNS

History: A focal abdominal u/s was done of the Gastro intestinal tract. Presented for Abdominal distension about 2 weeks post splenectomy surgery. Originally an abdominal u/s was done on 9-7-22 and had a splenic mass. Splenectomy was done on 9-8-22 and pt did well and pt was diagnosed with stromal sarcoma. Presented again on 9-27-22 with abdominal distension and moderate pain on abdominal palpation. GI dz (gastroenteritis fb ? decreased motility), Neoplasia, etc. Pt was manage with hospitalization iv fluids pantoprazole iv sid metronidazole iv bid
Abnormal PE/Chem/CBC/UA Results: PE: abdominal distension and abdominal tension and discomfort. CBC - WNL Radiograph severe gastric dilatation, also severe small bowel distention with gas.

ULTRASONOGRAPHIC EXAMINATION OF THE ABDOMEN

Gastrointestinal

The **stomach** revealed a severe amount of stasis and over distension. Variable portions of small intestine revealed minor areas of muscularis hypertrophy and a slight amount of free fluid. The mesenteric lymph nodes were reactive and measured up to 3.14 x 1.0 cm. A minor amount of free fluid was present.

Pancreas

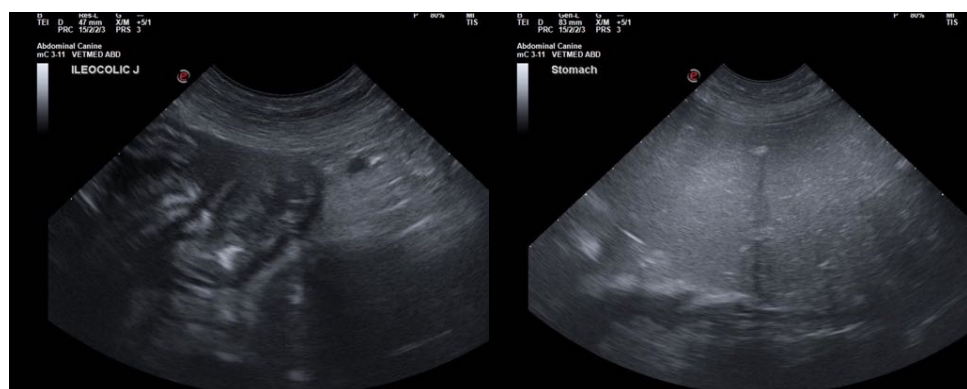The visible **pancreas** was unremarkable.

ULTRASONOGRAPHIC FINDINGS

Gastric stasis and variable small intestinal thickening of the free fluid.

INTERPRETATION OF THE FINDINGS & FURTHER RECOMMENDATIONS

Ultrasound-guided abdominocentesis or direct exploratory surgery is warranted. Delayed outflow pattern was noted, cause is unclear.





PATIENT

Bgatiatus Margaca

SPECIES

Canine

BREED

Labrador Mix

SEX

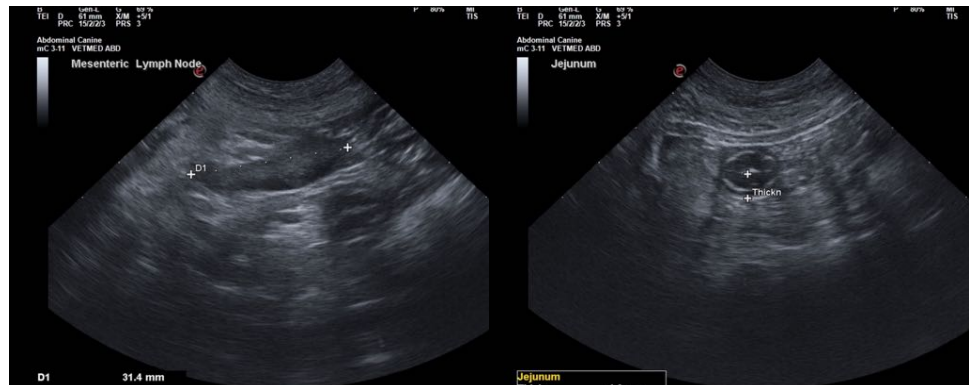
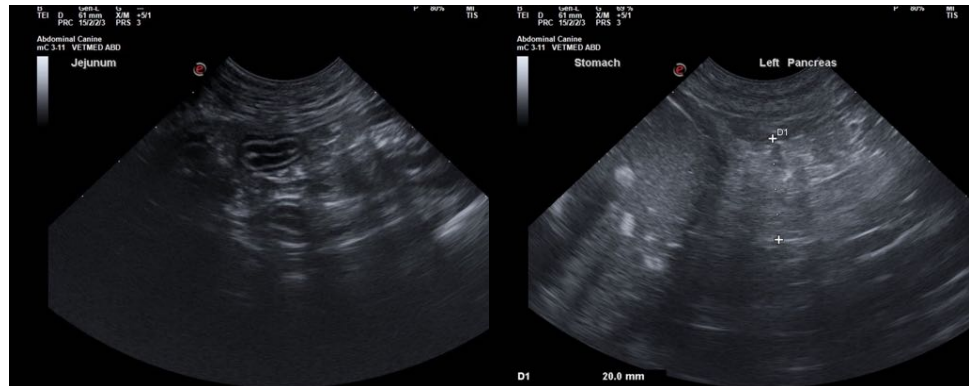
Neutered male

AGE

11 years

WEIGHT

58.6 lbs



INTERPRETED BY

Eric Lindquist, DMV
DABVP, Cert. IVUSS

IMAGING PERFORMED BY

Dr. Ferrer

HOSPITAL NAME

Paseos VC

REFERRING VET

Dr. Carrasquillo

INVOICE

39682

DATE

9/28/22

The information and recommendations provided are based on the images presented by the referring veterinarian/sonographer. No evaluation can be communicated regarding pathology that was not visible in the image/video clips provided.

Thank you for this referral. If the clinical or image interpretation does not parallel your findings or if I can be of any further assistance please contact me.

Eric Lindquist, DMV, DABVP, Cert. IVUSS, CEO of SonoPath.com
info@SonoPath.com