



PATIENT PRESENTING CLINICAL SIGNS

Petey Kolb

History: History of skin problems. Elevated liver values
Abnormal PE/Chem/CBC/UA Results: ALT 657, ALK PHOS 700, previous ALT 821, ALK PHOS 733 last month

SPECIES

Canine

ULTRASONOGRAPHIC EXAMINATION OF THE ABDOMEN

BREED

Urinary System

Pit Bull Mix

The **urinary bladder**, trigone, and pelvic urethra presented normal thicknesses and normal tone. The pelvic urethra was imaged 2.0 cm beyond the cystourethral junction. The ureters were not visible which is normal. No uroliths or sediment were visualized and anechoic urine was present. No evidence of inflammatory or neoplastic changes was noted. Ureteral papillae were normal.

SEX

Neutered male

The iliac trifurcation was unremarkable.

AGE

5 years

The **kidneys** revealed normal size and structure, corticomedullary definition and ratio for this age. The cortices presented largely uniform texture with normal echogenic relationship to liver and spleen. Medullary structure differed distinctly from the cortex and no evidence of pelvic dilation was present. The capsules were acceptably uniform without significant irregularities. The right kidney measured 7.68 cm. The left kidney measured 7.06 cm.

WEIGHT

90.5 lbs

Adrenal Glands

Both **adrenal glands** were visualized and recognized as having normal shape, size, position and echogenicity for this breed. The phrenic vasculature, glandular echogenicity and detail were unremarkable. Capsule, cortex, and medullary definition were normal for this age patient. The left adrenal gland measured 2.18 x 0.55 cm.

INTERPRETED BY

Eric Lindquist, DMV
DABVP, Cert. IVUSS

IMAGING PERFORMED BY

JK

Spleen

The **spleen** in this patient was mildly enlarged with uniform parenchyma and was folded upon itself cranially and caudally. This is a positional variant and is not pathological. There was no evidence of significant disease.

HOSPITAL NAME

Hamburg

Liver

REFERRING VET

Dr. Martens

The **liver** revealed uniform enlargement. The gallbladder in this patient was over distended. This is consistent with mucocele formation and measured 10 x 5 cm.

INVOICE

92033

Gastrointestinal

Gastric stasis was noted. This is consistent with delayed outflow. A large amount of echogenic debris was noted in the stomach. The small intestines and colon were unremarkable.

DATE

9/29/21



PATIENT

Pancreas

Petey Kolb

The base and limbs of the **pancreas** were observed to be largely isoechoic to surrounding omental fat. Pancreatic duct and capsular contour were acceptably normal and parenchyma respected normal curvilinear patterns. No overt evidence of active inflammatory or neoplastic disease was noted.

SPECIES

Canine

Free Abdomen

BREED

Pit Bull Mix

Mixed, hypoechoic, irregular mass was noted in the right cranial abdomen. The mass measured 8.0 cm. The exact origin is unclear. This could be adrenal, right liver or pancreatic in origin.

SEX

Neutered male

ULTRASONOGRAPHIC FINDINGS

Congested gallbladder/mucocele formation.

Right cranial liver mass of unknown origin, could be adrenal, right liver or pancreatic.

AGE

5 years

INTERPRETATION OF THE FINDINGS & FURTHER RECOMMENDATIONS

WEIGHT

90.5 lbs

Ultrasound-guided FNA would be necessary. There are two separate issues in this patient. CT evaluation would be ideal for further definition.

ABOUT SONOPATH CT SERVICES:

SonoPath CT Services are offered at the [Blairstown Animal Hospital](#). Blairstown, New Jersey. More information can be found at

<https://sonopath.com/resources/sonopaths-teleconsultation-services-and-sdep-certification/sonopath-ct-services>

INTERPRETED BY

Eric Lindquist, DMV
DABVP, Cert. IVUSS

IMAGING PERFORMED BY

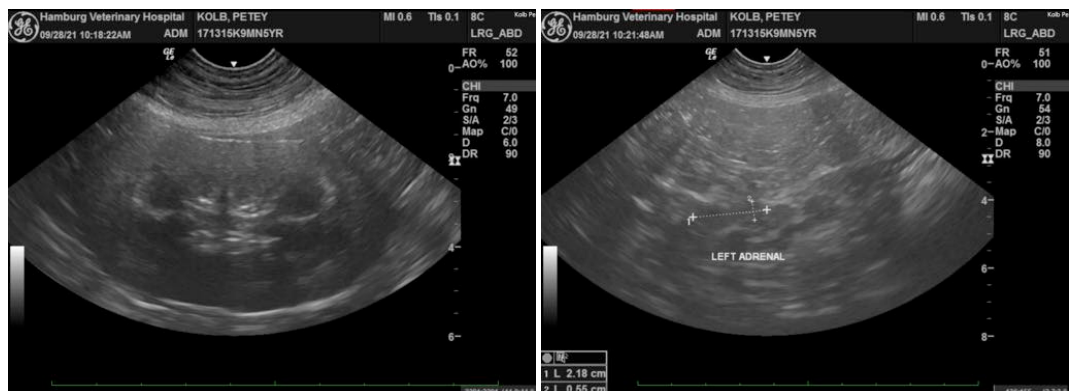
JK

HOSPITAL NAME

Hamburg

REFERRING VET

Dr. Martens



INVOICE

92033

DATE

9/29/21



PATIENT

Petey Kolb

SPECIES

Canine

BREED

Pit Bull Mix

SEX

Neutered male

AGE

5 years

WEIGHT

90.5 lbs

INTERPRETED BY

Eric Lindquist, DMV
DABVP, Cert. IVUSS

IMAGING PERFORMED BY

JK

HOSPITAL NAME

Hamburg

REFERRING VET

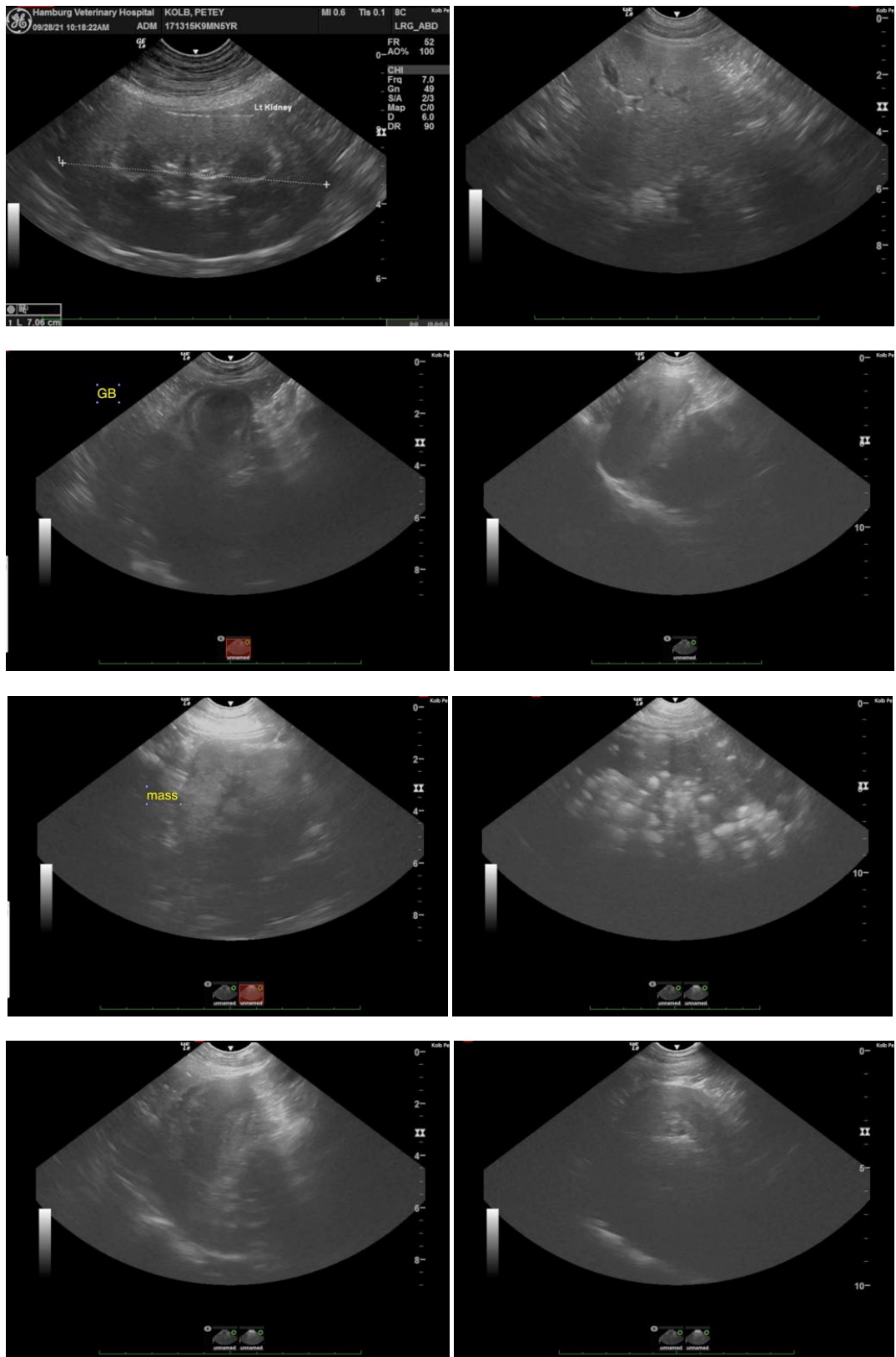
Dr. Martens

INVOICE

92033

DATE

9/29/21





PATIENT

Petey Kolb

The information and recommendations provided are based on the images presented by the referring veterinarian. No evaluation can be communicated regarding pathology that was not visible in the image/video clips provided.

SPECIES

Canine

Thank you for this referral. If the clinical or image interpretation does not parallel your findings or if I can be of any further assistance please contact me.

BREED

Pit Bull Mix

Eric Lindquist, DMV, DABVP, Cert. IVUSS, CEO of SonoPath.com
info@SonoPath.com

SEX

Neutered male

AGE

5 years

WEIGHT

90.5 lbs

INTERPRETED BY

Eric Lindquist, DMV
DABVP, Cert. IVUSS

**IMAGING
PERFORMED BY**

JK

HOSPITAL NAME

Hamburg

REFERRING VET

Dr. Martens

INVOICE

92033

DATE

9/29/21