



PATIENT PRESENTING CLINICAL SIGNS

Mitzi Bartolozzi History: Vomiting, diabetic. R/O Infection vs other. Current meds: Inj. given today Polyflex, Ondansetron, Metoclopramide, Famotidine
Abnormal PE/Chem/CBC/UA Results: Elevated PLT's, Lyme +, Elevated BG. U/A pending.

SPECIES

Canine

ULTRASONOGRAPHIC EXAMINATION OF THE ABDOMEN

BREED

Urinary System

Mix

The **urinary bladder**, trigone, and pelvic urethra presented normal thicknesses and normal tone. The pelvic urethra was imaged 3.0 cm beyond the cystourethral junction. The ureters were not visible which is normal. No uroliths or sediment were visualized and anechoic urine was present. No evidence of inflammatory or neoplastic changes was noted. Ureteral papillae were normal.

SEX

Spayed Female

AGE

7 years

The **kidneys** were normal in size and contour; however, a minor hyperechoic ring was noted at the corticomedullary junction. This is consistent with diabetic nephropathy. This is likely from glucosuria. However, assessment for proteinuria is also warranted. This is an idiopathic finding, but an expected finding in diabetic patients. The left kidney measured 7.6 cm. The right kidney measured 8.08 cm.

WEIGHT

90 lbs

Adrenal Glands

Both **adrenal glands** were visualized and recognized as having normal shape, size, position and echogenicity for this breed. The phrenic vasculature, glandular echogenicity and detail were unremarkable. Capsule, cortex, and medullary definition were normal for this age patient. The left adrenal gland measured 3.03 x 0.72 cm at the cranial pole and 0.62 cm at the caudal pole. The right adrenal gland measured 3.16 x 1.62 cm at the cranial pole and 1.2 cm at the caudal pole.

INTERPRETED BY

Eric Lindquist, DMV
DABVP, Cert. IVUSS

IMAGING PERFORMED BY

Shari Reffi, CVT

Spleen

The **spleen** revealed an expansive, progressively shadowing mass that measured 3.06 cm. The splenic mass was non-vascular. This is likely connective tissue origin/stromal tumor.

HOSPITAL NAME

North Warren AH

Liver

The **liver** was diffusely hyperechoic to the falciform fat. The gallbladder was unremarkable. Attenuating sound beam and generalized enlargement was noted. This is consistent with diabetic hepatopathy.

REFERRING VET

Dr. Corrado

INVOICE

Gastrointestinal

92052

Examination of the **gastrointestinal tract** revealed a stomach and intestine free of stasis, of normal wall thickness, acceptable curvilinear mural detail, and peristaltic activity. Small and large intestine demonstrated normal luminal chyme and stool consistency respectively. No obstructive or overt infiltrative disease was noted. No associated abnormal lymphatic activity was noted.

DATE

9/28/21



PATIENT

Pancreas

Mitzi Bartolozzi

The **pancreas** was heterogenous, hypoechoic and irregular in the right limb measuring 2.14 cm at maximum width. The pancreatic pathology appeared to be limited to the right limb.

SPECIES

Canine

ULTRASONOGRAPHIC FINDINGS

Right limb pancreatitis.

BREED

Mix

Diabetic hepatopathy, diabetic nephropathy.

Splenic mass, may be completely incidental.

SEX

Spayed Female

INTERPRETATION OF THE FINDINGS & FURTHER RECOMMENDATIONS

Eventual splenectomy and liver biopsy would be appropriate.

AGE

7 years

Potential Causes of Diabetic Dysregulation

This is a suggestive checkoff list when faced with an unregulated diabetic patient:

WEIGHT

90 lbs

UTI

INTERPRETED BY

Eric Lindquist, DMV
DABVP, Cert. IVUSS

Dietary indiscretion/intolerance

Pancreatitis

Hyperthyroidism/hypothyroidism

IMAGING PERFORMED BY

Shari Reffi, CVT

Exogenous steroids (including topical eye meds)

Cushing's

Acromegaly

HOSPITAL NAME

North Warren AH

Owner compliance

Insulin quality issues

REFERRING VET

Dr. Corrado

Antibodies to insulin

Underlying Neoplasia

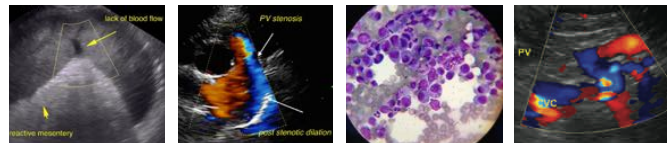
Diffuse liver disease

INVOICE

92052

DATE

9/28/21



PATIENT

Mitzi Bartolozzi

SPECIES

Canine

BREED

Mix

SEX

Spayed Female

AGE

7 years

WEIGHT

90 lbs

INTERPRETED BY

Eric Lindquist, DMV
DABVP, Cert. IVUSS

IMAGING PERFORMED BY

Shari Reffi, CVT

HOSPITAL NAME

North Warren AH

REFERRING VET

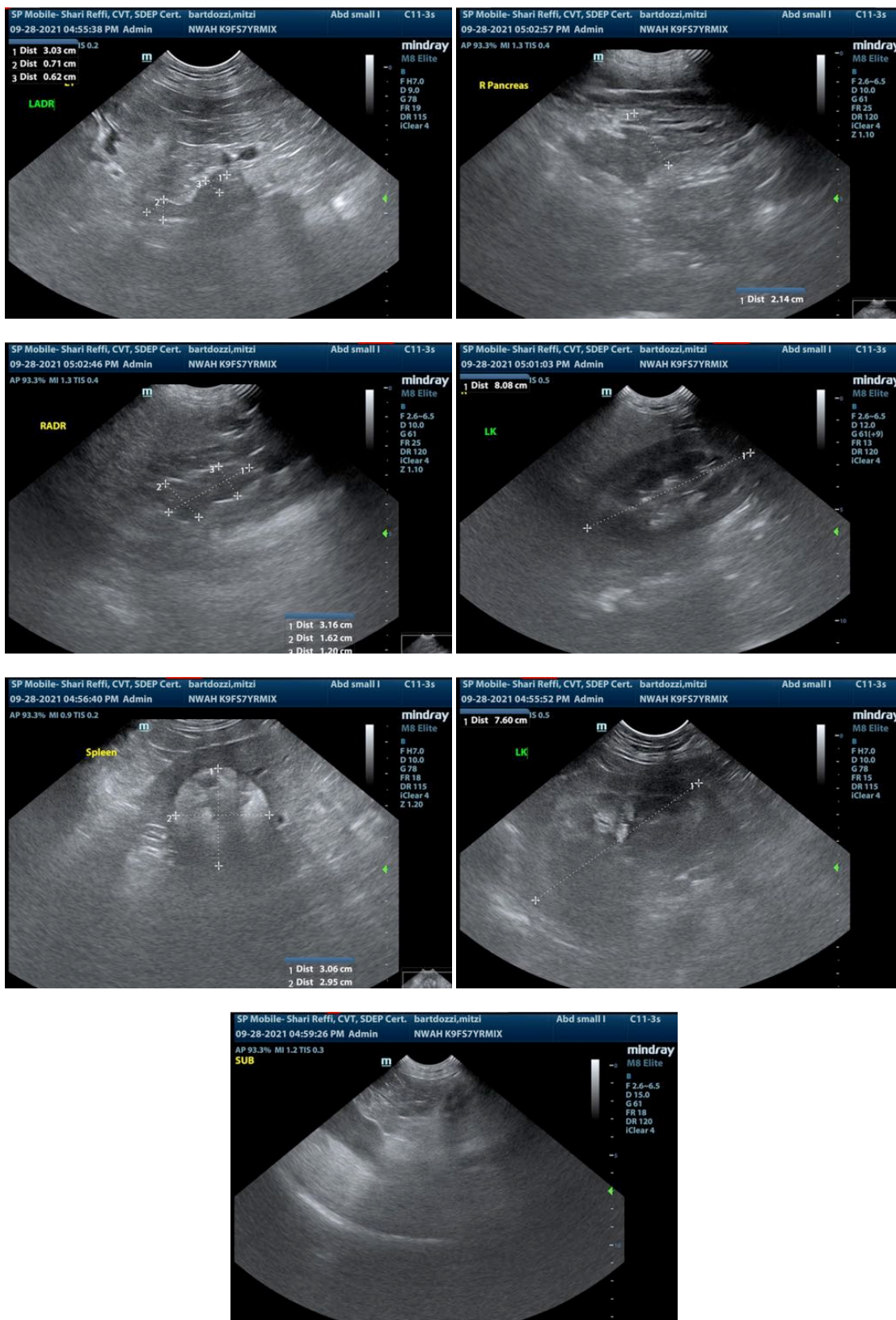
Dr. Corrado

INVOICE

92052

DATE

9/28/21





PATIENT

Mitzi Bartolozzi

veterinarian. No evaluation can be communicated regarding pathology that was not visible in the image/video clips provided.

Thank you for this referral. If the clinical or image interpretation does not parallel your findings or if I can be of any further assistance please contact me.

SPECIES

Canine

Eric Lindquist, DMV, DABVP, Cert. IVUSS, CEO of SonoPath.com
Info@SonoPath.com

BREED

Mix

SEX

Spayed Female

AGE

7 years

WEIGHT

90 lbs

INTERPRETED BY

Eric Lindquist, DMV
DABVP, Cert. IVUSS

**IMAGING
PERFORMED BY**

Shari Reffi, CVT

HOSPITAL NAME

North Warren AH

REFERRING VET

Dr. Corrado

INVOICE

92052

DATE

9/28/21