



**PATIENT PRESENTING CLINICAL SIGNS**

**PATIENT** Ichigo Mayo **History:** Diagnosed with a Grade 1 murmur previously. Murmur has not increased to a Grade 3 left systolic

**SPECIES BREED** **ULTRASONOGRAPHIC EXAMINATION OF THE HEART**

Feline

The echocardiogram in this patient demonstrated normal **left atrial** size based on 3 separate LA measurements. The cranial and caudal **mitral** valve leaflets presented normal linear structure and kinetics.. The **left ventricle** presented normal thicknesses with linear contour and was not dilated nor restricted. The **myocardium** presented normal echogenicity without subjective evidence of significant fibrotic or ischemic disease. **Contractility** of the ventricular walls was adequate and in normal range for this patient evidenced by the fractional shortening measurement and subjective evaluation of the different regions and angles of the myocardium. The **left ventricular outflow** tract demonstrated normal laminar flow and subjective structural integrity. The **right atrium** and auricle revealed normal size, structure and content. No evidence of masses was noted or chamber overload. **Tricuspid** valvular assessment demonstrated adequate linear morphology and kinetics. The **right ventricle** was of normal size (1/3 diameter of LV), chordae structure, myocardial echogenicity and thickness. **Pulmonic** tract assessment revealed normal valve structure, laminar flow, and diameter (approx.1:1 pa/ao ratio). No visible **pericardial** or free pleura fluid was noted or extra cardiac pathology in the visible planes. The cranial **mediastinum and pericardial regions** were free of masses in the visible window.

**BREED** Domestic Shorthair

**SEX**

Neutered male

**AGE**

16 years

**WEIGHT**

8 lbs

**INTERPRETED BY**

Eric Lindquist, DMV  
DABVP, Cert. IVUSS

**IMAGING PERFORMED BY**

Dr. Gotfredson

**HOSPITAL NAME**

Red Hills VH

**REFERRING VET**

Dr. Button

**INVOICE**

92057

**DATE**

9/28/21

FELINE CARDIAC PARAMETERS	BODY WEIGHT	HR (BPM)	IVSd (cm)	LVIDd (cm)	LVWd (cm)	FS (%)	EF (%)
NORMAL PARAMETER	-----	150-240	0.3-0.6	1.0-2.1	0.25-0.6	35-67	80-100
PATIENT	8 lbs	NM	0.4	1.6	0.4	50	90
FELINE CARDIAC PARAMETERS	LA/AO (Boon)	LA/AO HEART BASE (Sisson)	LA 2D 4-chamber long axis AS to FW (Sisson) (cm)	LVOT VEL. (m/s)	RVOT VEL. (m/s)	IVRT (m/)	
NORMAL PARAMETER	<1.5	0.88-1.79	0.7-1.7	<1.6	<1.3	40-60	
PATIENT	1.15	1.3	1.3 max			NM	
Adapted from June Boon, Veterinary Echocardiography, 1998 Sisson D et al. JVIM 1991; 5: 232, Jacobs et al. Am J Vet Res 1985; 46:1705							



**PATIENT**

Ichigo Mayo

**ULTRASONOGRAPHIC FINDINGS**

Structurally unremarkable with likely flow murmur.

**SPECIES**

Feline

**INTERPRETATION OF THE FINDINGS & FURTHER RECOMMENDATIONS**

There is no evidence of significant acquired disease. Assessment for causes of systemic volume shifts is recommended.

**BREED**

Domestic Shorthair

**SEX**

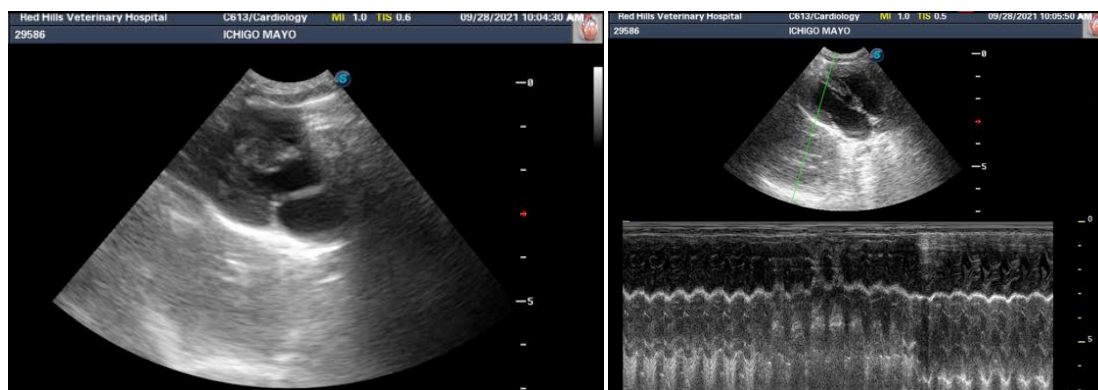
Neutered male

**AGE**

16 years

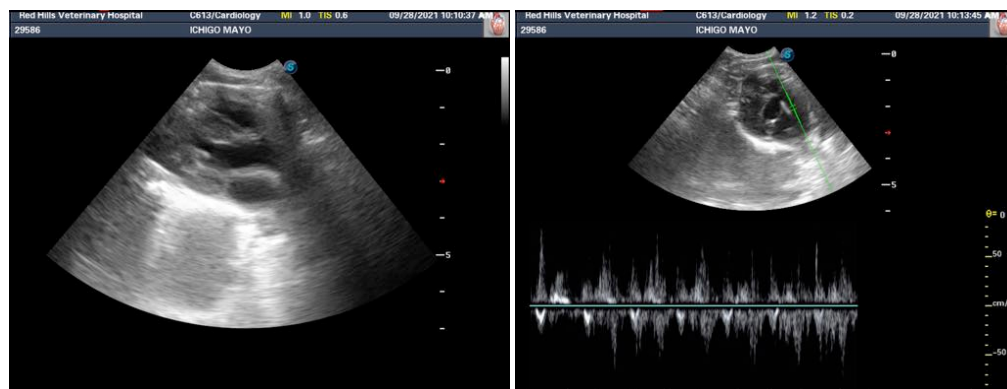
**WEIGHT**

8 lbs



**INTERPRETED BY**

Eric Lindquist, DMV  
DABVP, Cert. IVUSS



**IMAGING PERFORMED BY**

Dr. Gotfredson

**HOSPITAL NAME**

Red Hills VH

**REFERRING VET**

Dr. Button

The information and recommendations provided are based on the images presented by the referring veterinarian. No evaluation can be communicated regarding pathology that was not visible in the image/video clips provided.

**INVOICE**

92057

Thank you for this referral. If the clinical or image interpretation does not parallel your findings or if I can be of any further assistance please contact me.

**DATE**

9/28/21

Eric Lindquist, DMV, DABVP, Cert. IVUSS, CEO of SonoPath.com  
info@SonoPath.com