



PATIENT	PRESENTING CLINICAL SIGNS
Winifred Delia Young	History: Checking if spayed, cat does have a spay scar but owner needs confirmation/proof if spayed for rescue
SPECIES	ULTRASONOGRAPHIC EXAMINATION OF THE ABDOMEN
Feline	Urinary System
BREED	The urinary bladder , trigone, and pelvic urethra presented normal thicknesses and normal tone. The ureters were not visible which is normal. No uroliths or sediment were visualized and anechoic urine was present. No evidence of inflammatory or neoplastic changes was noted. Ureteral papillae were normal.
Domestic Shorthair	
SEX	Uterus was not visualized. Ovarian foci do not reveal any evidence of ovaries.
Female	The kidneys revealed normal size and structure, corticomedullary definition and ratio for this age. The cortices presented largely uniform texture with normal echogenic relationship to liver and spleen. Medullary structure differed distinctly from the cortex and no evidence of pelvic dilation was present. The capsules were acceptably uniform without significant irregularities. The right kidney measured 3.92 cm. The left kidney measured 4.25 cm.
AGE	
1 year	
WEIGHT	Adrenal Glands
8.4 lbs	Both adrenal glands were visualized and recognized as having normal shape, size, position and echogenicity for this breed. The phrenic vasculature, glandular echogenicity and detail were unremarkable. Capsule, cortex, and medullary definition were normal for this age patient.
INTERPRETED BY	Spleen
Eric Lindquist, DMV DABVP, Cert. IVUSS	The spleen presented a smooth homogeneous parenchyma hyperechoic to liver and renal cortical parenchyma. The capsule was smooth without noticeable expansion or deviation from within the spleen or adjacent pathology. The splenic vasculature demonstrated normal volume without signs of congestion or thrombosis. No sonographic evidence of acute or chronic inflammatory, neoplastic, or infarctual changes was noted.
IMAGING PERFORMED BY	Liver
Jenn	The liver images submitted revealed subjectively normal liver size, contour, and structure. Parenchymal echogenicity was naturally coarse and hypoechoic to the spleen. Vascular and biliary tracts were of normal volume with no evidence of congestion. The gallbladder presented acceptably thin walls with primarily anechoic content. The cystic and common bile ducts were normal. No pathological hepatic lymphadenopathy was evident. No overt structural evidence of inflammatory, infiltrative or regenerative pathology was evident.
HOSPITAL NAME	
Rockaway AH	
REFERRING VET	
Dr. Gannon	
INVOICE	
39619	
DATE	Gastrointestinal
9/27/22	Examination of the gastrointestinal tract revealed a stomach and intestine free of stasis, of normal wall thickness, acceptable curvilinear mural detail, and peristaltic activity. Small and large intestine



PATIENT

Winifred Delia Young

demonstrated normal luminal chyme and stool consistency respectively. No obstructive or overt infiltrative disease was noted. No associated abnormal lymphatic activity was noted.

SPECIES

Feline

Pancreas

The base and limbs of the **pancreas** were observed to be largely isoechoic to surrounding omental fat. Pancreatic duct and capsular contour were acceptably normal and parenchyma respected normal curvilinear patterns. No overt evidence of active inflammatory or neoplastic disease was noted.

BREED

Domestic Shorthair

ULTRASONOGRAPHIC FINDINGS

SEX

Female

Normal abdomen.

INTERPRETATION OF THE FINDINGS & FURTHER RECOMMENDATIONS

AGE

1 year

There was no evidence of reproductive organs. Prior ovariohysterectomy is suspected.

WEIGHT

8.4 lbs

INTERPRETED BY

Eric Lindquist, DMV
DABVP, Cert. IVUSS

IMAGING PERFORMED BY

Jenn

HOSPITAL NAME

Rockaway AH

REFERRING VET

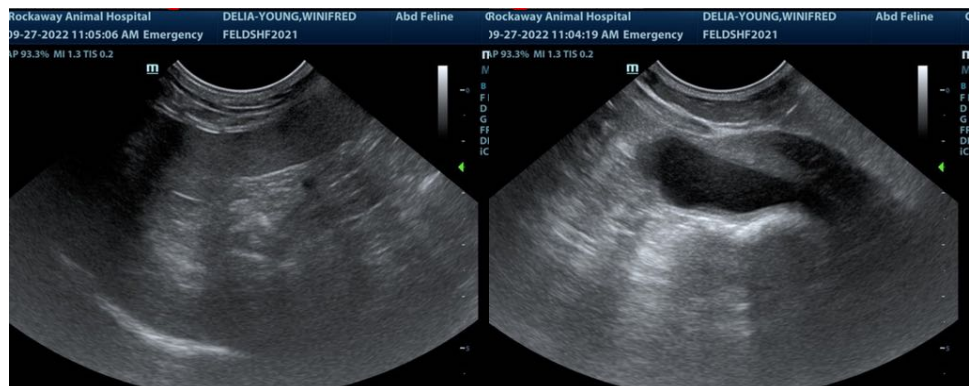
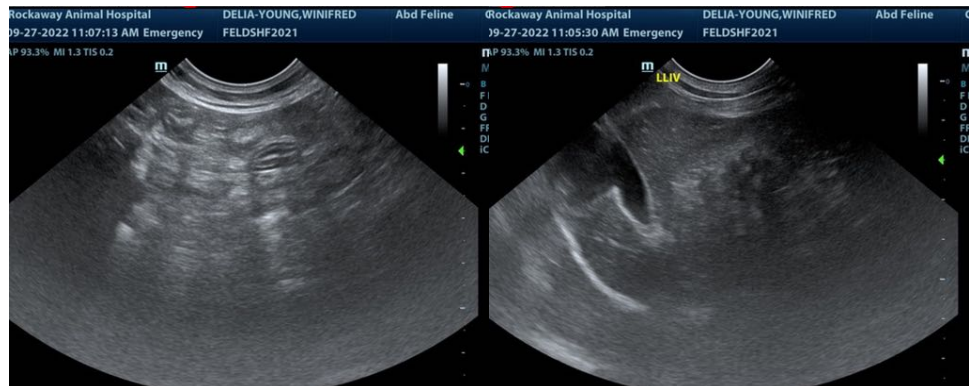
Dr. Gannon

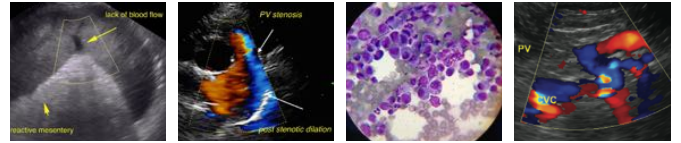
INVOICE

39619

DATE

9/27/22





PATIENT

Winifred Delia Young

SPECIES

Feline

BREED

Domestic Shorthair

SEX

Female

AGE

1 year

WEIGHT

8.4 lbs

INTERPRETED BY

Eric Lindquist, DMV
DABVP, Cert. IVUSS

IMAGING PERFORMED BY

Jenn

HOSPITAL NAME

Rockaway AH

REFERRING VET

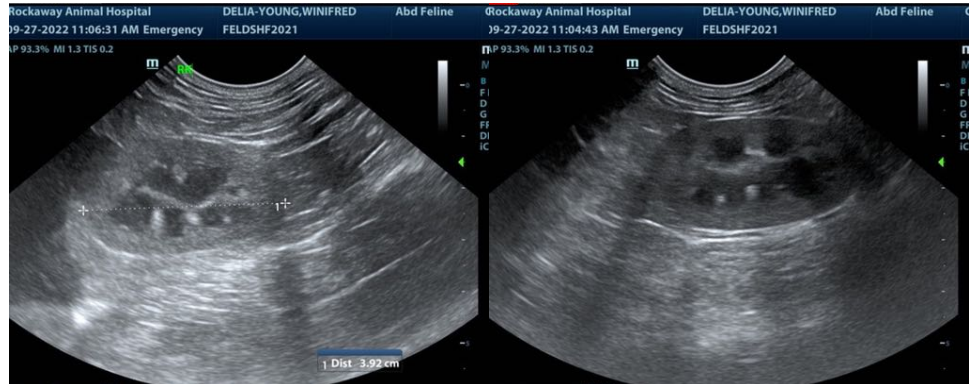
Dr. Gannon

INVOICE

39619

DATE

9/27/22



The information and recommendations provided are based on the images presented by the referring veterinarian/sonographer. No evaluation can be communicated regarding pathology that was not visible in the image/video clips provided.

Thank you for this referral. If the clinical or image interpretation does not parallel your findings or if I can be of any further assistance please contact me.

Eric Lindquist, DMV, DABVP, Cert. IVUSS, CEO of SonoPath.com
info@SonoPath.com