



PATIENT

Bodhi Saoud

SPECIES

Canine

BREED

Labrador

SEX

Neutered male

AGE

6 years

WEIGHT

70 lbs

INTERPRETED BY

Eric Lindquist, DMV
DABVP, Cert. IVUSS

IMAGING PERFORMED BY

Dr. Scott

HOSPITAL NAME

HoHoKus VH

REFERRING VET

Dr. Scott

INVOICE

39624

DATE

9/27/22

PRESENTING CLINICAL SIGNS

History: weight loss, all else normal (about 10 lbs in the last year), no explanation
Abnormal PE/Chem/CBC/UA Results: ALT 240, rest of BW WNL chest rads clear besides some disco
spondylosis in thoracic vertebrae

ULTRASONOGRAPHIC EXAMINATION OF THE ABDOMEN

Urinary System

The **urinary bladder**, trigone, and pelvic urethra presented normal thicknesses and normal tone. The pelvic urethra was imaged 1.0 cm beyond the cystourethral junction and appeared normal. The ureters were not visible which is normal. No uroliths or sediment were visualized and anechoic urine was present. No evidence of inflammatory or neoplastic changes was noted. Ureteral papillae were normal.

The **kidneys** revealed normal size and structure, corticomedullary definition and ratio for this age. The cortices presented largely uniform texture with normal echogenic relationship to liver and spleen. Medullary structure differed distinctly from the cortex and no evidence of pelvic dilation was present. The capsules were acceptably uniform without significant irregularities. The left kidney measured 4.5 cm. The right kidney measured 5.0 cm.

Adrenal Glands

The left **adrenal gland** was visualized and recognized as having normal shape, size, position and echogenicity for this breed. The phrenic vasculature, glandular echogenicity and detail were unremarkable. Capsule, cortex, and medullary definition were normal for this age patient. The left adrenal gland measured 0.5 cm. The region of the right adrenal gland was imaged with no evidence of pathology.

Spleen

The **spleen** presented a smooth homogeneous parenchyma hyperechoic to liver and renal cortical parenchyma. The capsule was smooth without noticeable expansion or deviation from within the spleen or adjacent pathology. The splenic vasculature demonstrated normal volume without signs of congestion or thrombosis. No sonographic evidence of acute or chronic inflammatory, neoplastic, or infarctual changes was noted.

Liver

The **liver** presented heterogenous parenchyma with increased portal markings and coarse architecture. Slight undulating capsular contour was noted. The gallbladder and common bile duct were unremarkable. This is consistent with chronic inflammatory hepatopathy.



PATIENT

Gastrointestinal

Bodhi Saoud

Examination of the **gastrointestinal tract** revealed a stomach and intestine free of stasis, of normal wall thickness, acceptable curvilinear mural detail, and peristaltic activity. Small and large intestine demonstrated normal luminal chyme and stool consistency respectively. No obstructive or overt infiltrative disease was noted. No associated abnormal lymphatic activity was noted.

SPECIES

Canine

BREED

Labrador

Pancreas

The base and limbs of the **pancreas** were observed to be largely isoechoic to surrounding omental fat. Pancreatic duct and capsular contour were acceptably normal and parenchyma respected normal curvilinear patterns. No overt evidence of active inflammatory or neoplastic disease was noted.

SEX

Neutered male

ULTRASONOGRAPHIC FINDINGS

Non-specific, mild chronic inflammatory hepatopathy.

AGE

6 years

INTERPRETATION OF THE FINDINGS & FURTHER RECOMMENDATIONS

WEIGHT

70 lbs

Bile acid profile is warranted as well as Leptospirosis. Otherwise, the abdomen was unremarkable. There was no other evidence of cause of weight loss.

Maldigestion panel, three view chest radiographs and full CNS examination is recommended to examine for occult disease that could be responsible for the weight loss. Evaluation for competitive eating environments should also be considered.

INTERPRETED BY

Eric Lindquist, DMV
DABVP, Cert. IVUSS

IMAGING PERFORMED BY

Dr. Scott

HOSPITAL NAME

HoHoKus VH

REFERRING VET

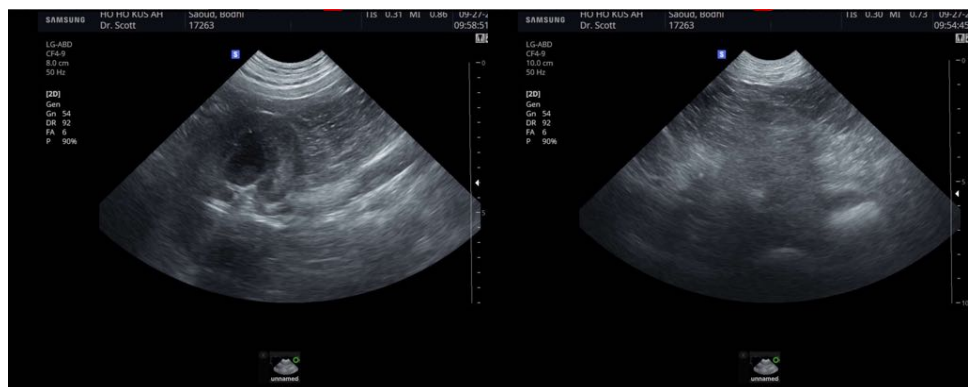
Dr. Scott

INVOICE

39624

DATE

9/27/22





PATIENT

Bodhi Saoud

SPECIES

Canine

BREED

Labrador

SEX

Neutered male

AGE

6 years

WEIGHT

70 lbs

INTERPRETED BY

Eric Lindquist, DMV
DABVP, Cert. IVUSS

IMAGING PERFORMED BY

Dr. Scott

HOSPITAL NAME

HoHoKus VH

REFERRING VET

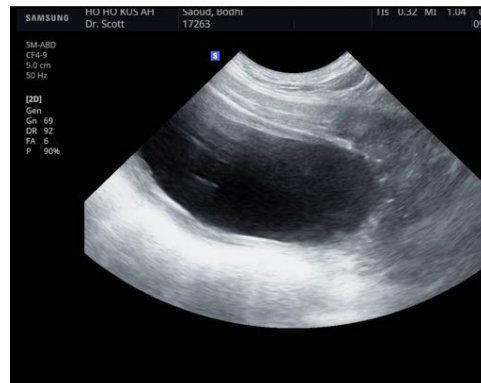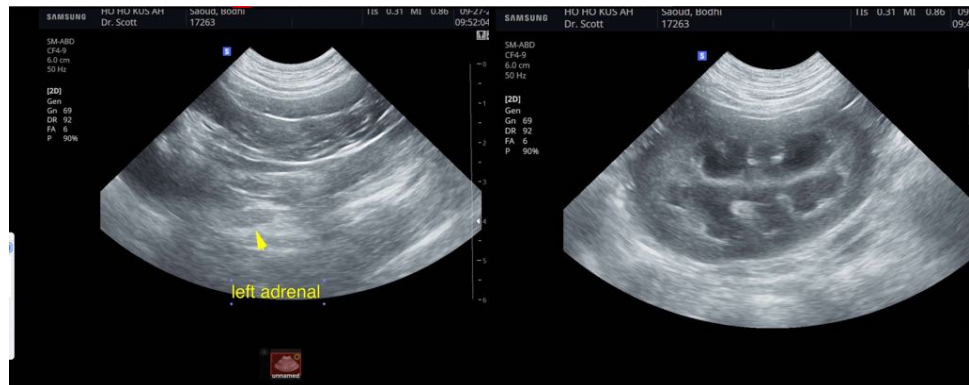
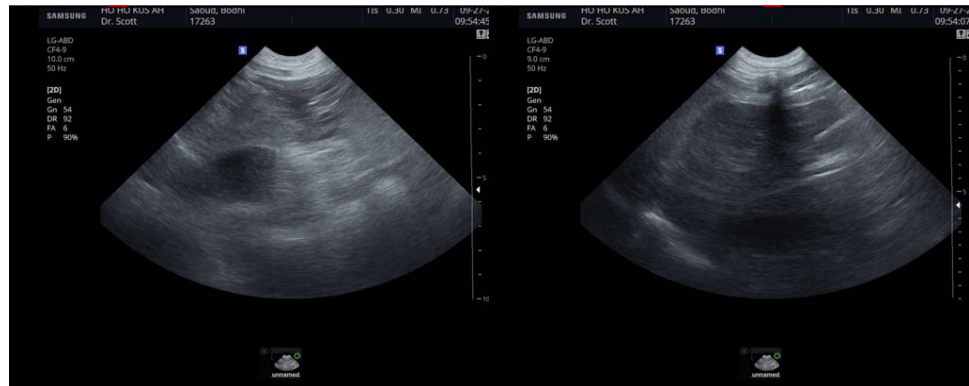
Dr. Scott

INVOICE

39624

DATE

9/27/22



The information and recommendations provided are based on the images presented by the referring veterinarian/sonographer. No evaluation can be communicated regarding pathology that was not visible in the image/video clips provided.

Thank you for this referral. If the clinical or image interpretation does not parallel your findings or if I can be of any further assistance please contact me.

Eric Lindquist, DMV, DABVP, Cert. IVUSS, CEO of SonoPath.com
info@SonoPath.com