



PATIENT

PRESENTING CLINICAL SIGNS

Simon Community Cat Advocates

History: Presented for not eating post-cystotomy and new anemia. Owner surrender to rescue, then had cystotomy for urolith at specialty clinic. Did well for 2 days, then anorexic x 4 days. At E clinic over the weekend, on IV fluids, Cerenia, Mirtazapine, Famotidine, Ampicillin and Buprinex. More BAR, but still only eating a tiny bit.

SPECIES

Feline

PE: BCS 4/9, sensitive on pressure to abdomen. Newly noted heart murmur Grade 3/6. BW (at Eclinic) HCT 23%, WBC 4,050, Plt 374k FeLV/FIV test NEG

BREED

Siamese

ULTRASONOGRAPHIC EXAMINATION OF THE ABDOMEN

SEX

Neutered male

Urinary System

The **urinary bladder** wall was thickened with loss of mural detail and minor polypoid changes.

The **kidneys** were mildly swollen and slightly irregular. Cortical infarcts were noted in the kidneys. The right kidney measured 3.92 cm. The left kidney measured 4.44 cm.

AGE

12 years

Adrenal Glands

Both **adrenal glands** were visualized and recognized as having normal shape, size, position and echogenicity for this breed. The phrenic vasculature, glandular echogenicity and detail were unremarkable. Capsule, cortex, and medullary definition were normal for this age patient.

WEIGHT

9.2 lbs

INTERPRETED BY

Eric Lindquist, DMV
DABVP, Cert. IVUSS

Spleen

The **spleen** was enlarged, irregular and hypoechoic with scalloping contour that measured 1.21 cm.

IMAGING PERFORMED BY

Dr. Ebersole

Liver

The **liver** revealed increased portal markings. The gallbladder and common bile duct were unremarkable.

HOSPITAL NAME

Scanvet

Gastrointestinal

Examination of the **gastrointestinal tract** revealed a stomach free of stasis, of normal wall thickness, acceptable curvilinear mural detail, and peristaltic activity. Multi-focal, infiltrative pattern was noted throughout the intestinal tract with regional lymphadenopathy. Loss of mural detail was noted. The mesenteric lymph nodes measured up to 1.5 cm. The epigastric lymph node measured 0.5 cm.

REFERRING VET

Dr. Lane

INVOICE

92022

Pancreas

The base and limbs of the **pancreas** were observed to be largely isoechoic to surrounding omental fat. Pancreatic duct and capsular contour were acceptably normal and parenchyma respected normal curvilinear patterns. No overt evidence of active inflammatory or neoplastic disease was noted.

DATE

9/27/21



PATIENT

Simon Community Cat Advocates

SPECIES

Feline

BREED

Siamese

SEX

Neutered male

AGE

12 years

WEIGHT

9.2 lbs

INTERPRETED BY

Eric Lindquist, DMV DABVP, Cert. IVUS

IMAGING PERFORMED BY

Dr. Ebersole

HOSPITAL NAME

Scanvet

REFERRING VET

Dr. Lane

INVOICE

92022

DATE

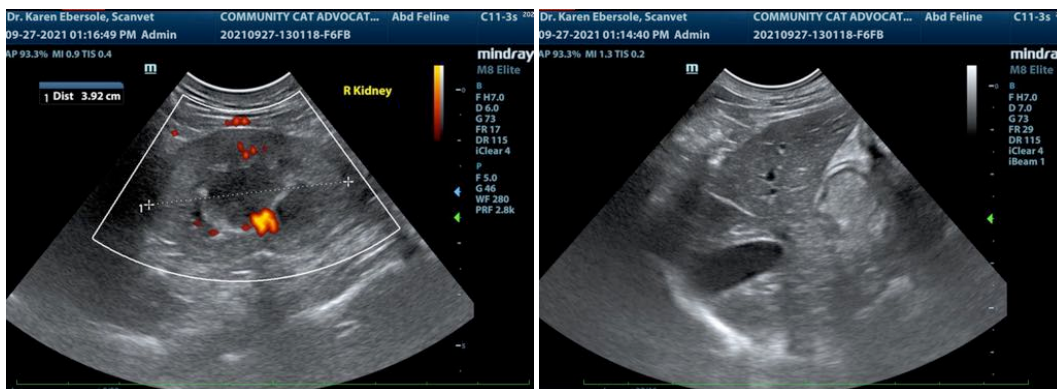
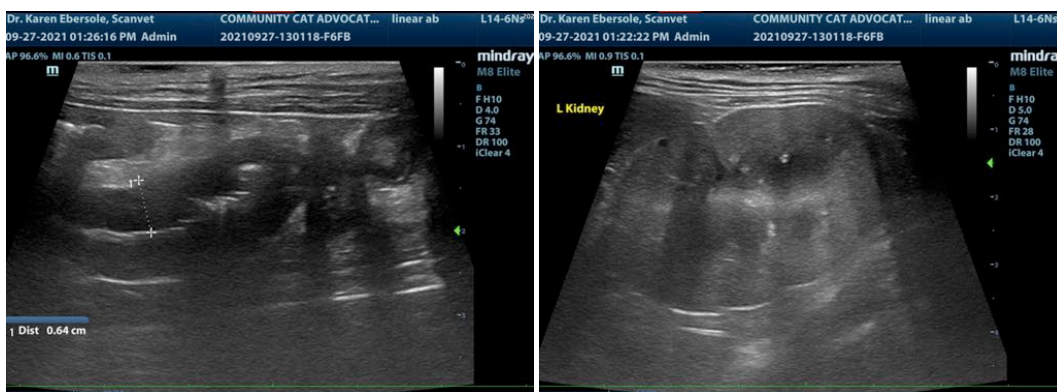
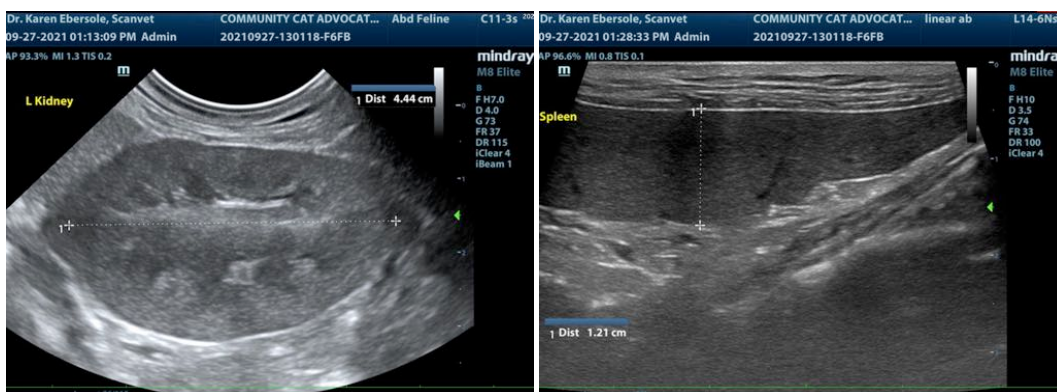
9/27/21

ULTRASONOGRAPHIC FINDINGS

Infiltrative splenic and intestinal pattern with regional lymphadenopathy. Reactive spleen/splenitis, complicated inflammatory bowel, lymphadenitis with chronic cystitis are all technically possible, however, neoplastic criteria is present in portions of the small intestine. Sampling is essential.

INTERPRETATION OF THE FINDINGS & FURTHER RECOMMENDATIONS

Given the splenic and intestinal presentation bladder lymphoma may be an issue versus chronic cystitis. Ultrasound-guided FNA of the spleen, lymph nodes and intestine would be warranted if accessible. The prognosis is guarded depending upon cytology results.





PATIENT

Simon Community Cat Advocates

SPECIES

Feline

BREED

Siamese

SEX

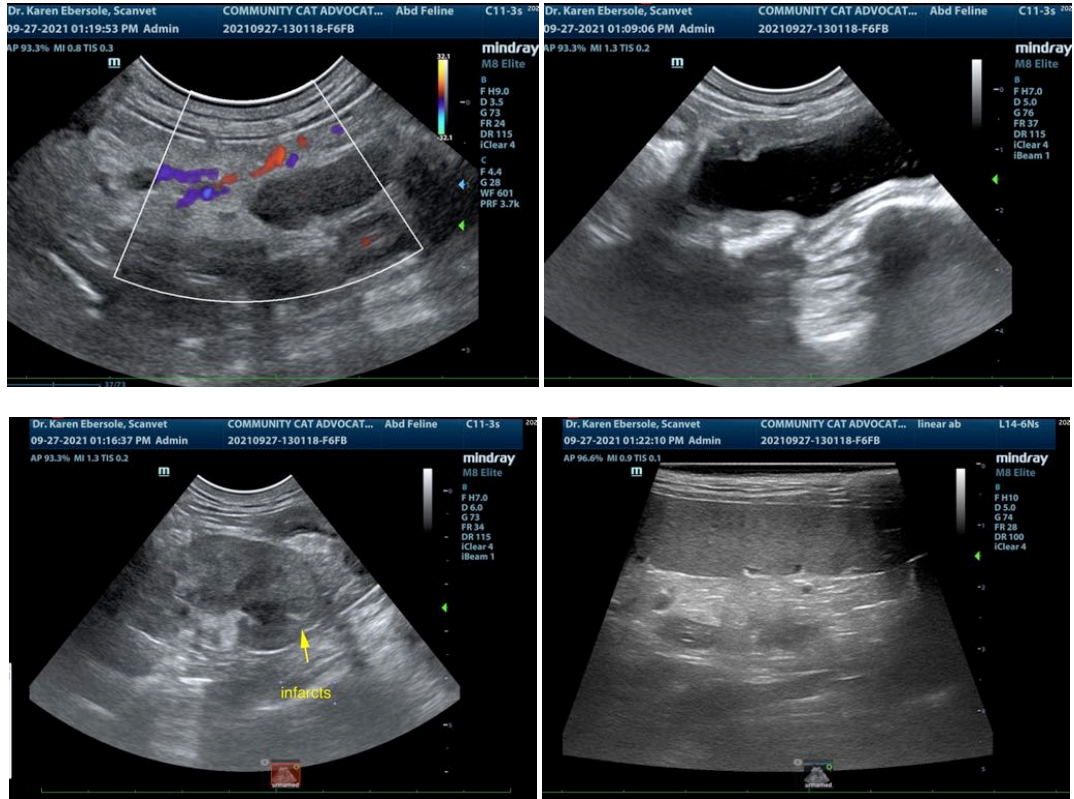
Neutered male

AGE

12 years

WEIGHT

9.2 lbs



INTERPRETED BY

Eric Lindquist, DMV
DABVP, Cert. IVUSS

IMAGING PERFORMED BY

Dr. Ebersole

HOSPITAL NAME

Scanvet

REFERRING VET

Dr. Lane

INVOICE

92022

DATE

9/27/21

The information and recommendations provided are based on the images presented by the referring veterinarian. No evaluation can be communicated regarding pathology that was not visible in the image/video clips provided.

Thank you for this referral. If the clinical or image interpretation does not parallel your findings or if I can be of any further assistance please contact me.

Eric Lindquist, DMV, DABVP, Cert. IVUSS, CEO of SonoPath.com
info@SonoPath.com