



**PATIENT**

Igor Stem-Faulk

**SPECIES**

Canine

**BREED**

Corgi

**SEX**

Male

**AGE**

5 Months

**WEIGHT**

13.5 Pounds

**INTERPRETED BY**

Eric Lindquist, DMV  
DABVP, Cert. IVUSS

**IMAGING PERFORMED BY**

Dr. Sarah Green

**HOSPITAL NAME**

Healing Spirit

**REFERRING VET**

Dr. Sarah Green

**INVOICE**

25820

**DATE**

9/27/21

**PRESENTING CLINICAL SIGNS**

acute onset vomiting, followed by hemorrhagic mucoid diarrhea. Radiographs suspicious for intestinal foreign material.

Abnormal PE/Chem/CBC/UA Results: subdued behavior, sensitive on abdominal palpation

**ULTRASONOGRAPHIC EXAMINATION OF THE ABDOMEN**

**Urinary System**

The **urinary bladder**, trigone, and pelvic urethra presented normal thicknesses and normal tone. The ureters were not visible which is normal. No uroliths or sediment were visualized and anechoic urine was present. No evidence of inflammatory or neoplastic changes were noted. Ureteral papillae were normal.

The **kidneys** revealed normal size and structure, corticomedullary definition and ratio for this age. The cortices presented largely uniform texture with normal echogenic relationship to liver and spleen. Medullary structure differed distinctly from the cortex and no evidence of pelvic dilation was present. The capsules were acceptably uniform without significant irregularities.

**Adrenal Glands**

The regions of the **adrenal glands** were unremarkable.

**Spleen**

The **spleen** presented a smooth homogeneous parenchyma hyperechoic to liver and renal cortical parenchyma. The capsule was smooth without noticeable expansion or deviation from within the spleen or adjacent pathology. The splenic vasculature demonstrated normal volume without signs of congestion or thrombosis. No sonographic evidence of acute or chronic inflammatory, neoplastic, or infarctual changes were noted.

**Liver**

The **liver** images submitted revealed subjectively normal liver size, contour, and structure. Parenchymal echogenicity was naturally coarse and hypoechoic to the spleen. Vascular and biliary tracts were of normal volume with no evidence of congestion. The gallbladder presented acceptably thin walls with primarily anechoic content. The cystic and common bile ducts were normal. No pathological hepatic lymphadenopathy was evident. No overt structural evidence of inflammatory, infiltrative or regenerative pathology was evident.

**Gastrointestinal**

The **stomach** was dilated with fluid. Mild pyloric thickening noted. The small intestine was empty. Enlarged, reactive mesenteric lymph nodes noted, measuring 2.0 cm x 0.5 cm. No evidence of foreign body.

**Pancreas**

The base and limbs of the **pancreas** were observed to be largely isoechoic to surrounding omental fat. Pancreatic duct and capsular contour were acceptably normal and parenchyma respected normal curvilinear patterns. No overt evidence of active inflammatory or neoplastic disease was noted.

**ULTRASONOGRAPHIC FINDINGS**

- Gastric stasis – delayed outflow, gastroenteritis



**PATIENT**

Igor Stem-Faulk

**INTERPRETATION OF THE FINDINGS & FURTHER RECOMMENDATIONS**

24 hr NPO recommended and reassessment of the sonogram for obvious obstruction in clinical signs persist. However, delayed outflow pattern is noted. However, pylorus was patent.

**SPECIES**

Canine

**BREED**

Corgi

**SEX**

Male

**AGE**

5 Months

**WEIGHT**

13.5 Pounds

**INTERPRETED BY**

Eric Lindquist, DMV  
DABVP, Cert. IVUSS

**IMAGING PERFORMED BY**

Dr. Sarah Green

**HOSPITAL NAME**

Healing Spirit

**REFERRING VET**

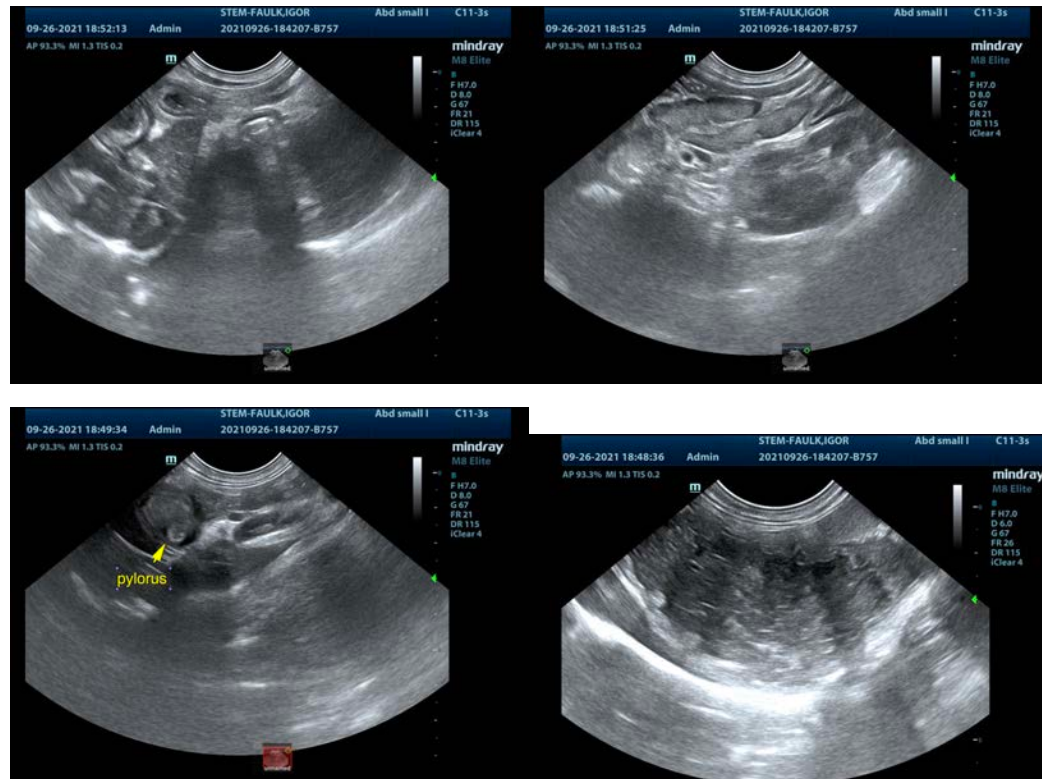
Dr. Sarah Green

**INVOICE**

25820

**DATE**

9/27/21



The information and recommendations provided are based on the images presented by the referring veterinarian. No evaluation can be communicated regarding pathology that was not visible in the image/video clips provided.

Thank you for this referral. If the clinical or image interpretation does not parallel your findings or if I can be of any further assistance please contact me.

**Eric Lindquist, DMV, DABVP, Cert. IVUSS, CEO of SonoPath.com**  
[info@SonoPath.com](mailto:info@SonoPath.com)