



PATIENT

Dolce Tambolleo

SPECIES

Canine

BREED

Pit Bull

SEX

Spayed Female

AGE

11 years

WEIGHT

71.4 lbs

INTERPRETED BY

Eric Lindquist, DMV
DABVP, Cert. IVUSS

IMAGING PERFORMED BY

Kelly Vazquez, CVT

HOSPITAL NAME

Bergen County VC

REFERRING VET

Dr. Lewis

INVOICE

92018

DATE

9/27/21

PRESENTING CLINICAL SIGNS

History: Hematuria - blood clots, history of UTI, suspect mass on focal aspect of bladder wall. Current meds: bladder supplements, 1 week of antibiotics. CBC/Chem: pending.

ULTRASONOGRAPHIC EXAMINATION OF THE ABDOMEN

Urinary System

The **urinary bladder** revealed an apical mass that measured 1.8 cm with tapering and apical wall thickening that extended to the cranial aspect of the ventral wall and the cranial aspect of the dorsal wall. The bladder mass appears resectable with removal of the apical third of the bladder wall. Given the position of the mass this may represent polypoid hyperplasia on top of an underlying urachal remnant. Underlying transitional cell carcinoma is a potential.

The **kidneys** revealed normal size and structure, corticomedullary definition and ratio for this age. The cortices presented largely uniform texture with normal echogenic relationship to liver and spleen. Medullary structure differed distinctly from the cortex and no evidence of pelvic dilation was present. The capsules were acceptably uniform without significant irregularities. The left kidney measured 5.91 cm.

Adrenal Glands

Both **adrenal glands** were visualized and recognized as having normal shape, size, position and echogenicity for this breed. The phrenic vasculature, glandular echogenicity and detail were unremarkable. Capsule, cortex, and medullary definition were normal for this age patient. The right adrenal gland measured 2.94 x 0.58 cm at the caudal pole and 1.15 cm at the cranial pole. The left adrenal gland measured 2.03 x 0.73 cm at the caudal pole and 0.51 cm at the cranial pole.

Spleen

The **spleen** presented a smooth homogeneous parenchyma hyperechoic to liver and renal cortical parenchyma. The capsule was smooth without noticeable expansion or deviation from within the spleen or adjacent pathology. The splenic vasculature demonstrated normal volume without signs of congestion or thrombosis. No sonographic evidence of acute or chronic inflammatory, neoplastic, or infarctual changes was noted.

Liver

The **liver** images submitted revealed subjectively normal liver size, contour, and structure. Parenchymal echogenicity was naturally coarse and hypoechoic to the spleen. Vascular and biliary tracts were of normal volume with no evidence of congestion. The gallbladder presented acceptably thin walls with primarily anechoic content. The cystic and common bile ducts were normal. No pathological hepatic lymphadenopathy was evident. No overt structural evidence of inflammatory, infiltrative or regenerative pathology was evident.



PATIENT

Gastrointestinal

Dolce Tambolleo

Examination of the **gastrointestinal tract** revealed a stomach and intestine free of stasis, of normal wall thickness, acceptable curvilinear mural detail, and peristaltic activity. Small and large intestine demonstrated normal luminal chyme and stool consistency respectively. No obstructive or overt infiltrative disease was noted. No associated abnormal lymphatic activity was noted.

SPECIES

Canine

BREED

Pit Bull

SEX

Spayed Female

AGE

11 years

WEIGHT

71.4 lbs

Pancreas

The base and limbs of the **pancreas** were observed to be largely isoechoic to surrounding omental fat. Pancreatic duct and capsular contour were acceptably normal and parenchyma respected normal curvilinear patterns. No overt evidence of active inflammatory or neoplastic disease was noted.

ULTRASONOGRAPHIC FINDINGS

Apical bladder mass, may be non-neoplastic, possible hyperplastic tissue overlying urachal remnant.

INTERPRETATION OF THE FINDINGS & FURTHER RECOMMENDATIONS

Removal of the cranial half to 1/3 of the urinary bladder is recommended with appropriate biopsies in the center of the mass as well as the margins to assess for adequate resection. Culture and sensitivity of the bladder mass is also indicated.

INTERPRETED BY

Eric Lindquist, DMV
DABVP, Cert. IVUSS

IMAGING PERFORMED BY

Kelly Vazquez, CVT

HOSPITAL NAME

Bergen County VC

REFERRING VET

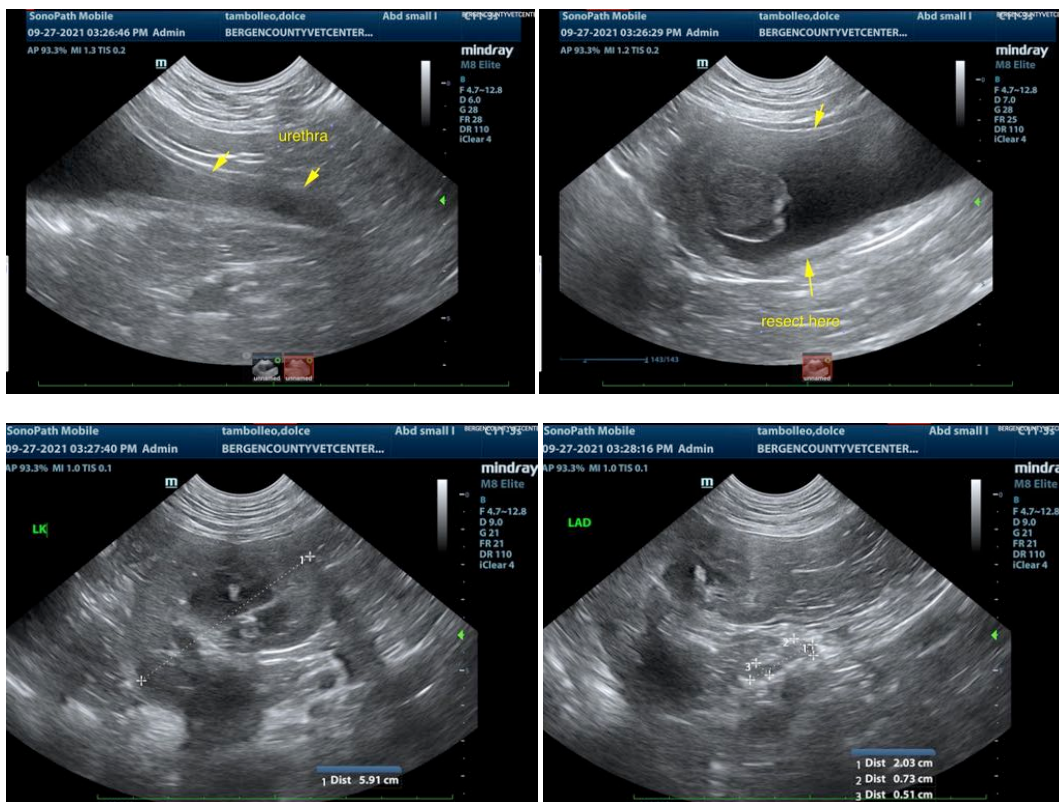
Dr. Lewis

INVOICE

92018

DATE

9/27/21





PATIENT

Dolce Tambolleo

SPECIES

Canine

BREED

Pit Bull

SEX

Spayed Female

AGE

11 years

WEIGHT

71.4 lbs

INTERPRETED BY

Eric Lindquist, DMV
DABVP, Cert. IVUSS

IMAGING PERFORMED BY

Kelly Vazquez, CVT

HOSPITAL NAME

Bergen County VC

REFERRING VET

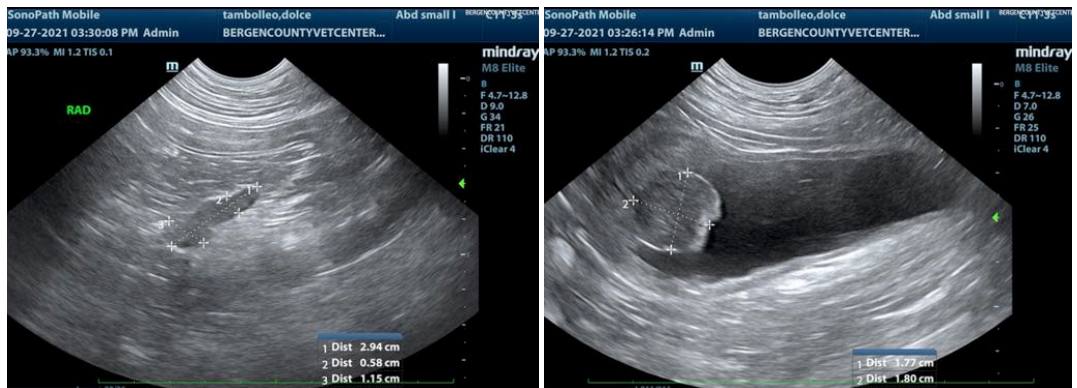
Dr. Lewis

INVOICE

92018

DATE

9/27/21



The information and recommendations provided are based on the images presented by the referring veterinarian. No evaluation can be communicated regarding pathology that was not visible in the image/video clips provided.

Thank you for this referral. If the clinical or image interpretation does not parallel your findings or if I can be of any further assistance please contact me.

Eric Lindquist, DMV, DABVP, Cert. IVUSS, CEO of SonoPath.com
info@SonoPath.com