



PATIENT

Cloud Digiovanni

SPECIES

Feline

BREED

Domestic Shorthair

SEX

14 years

AGE

13 lbs

WEIGHT

13 lbs

INTERPRETED BY

Eric Lindquist, DMV
DABVP, Cert. IVUSS

IMAGING PERFORMED BY

Dr. Caughman

HOSPITAL NAME

Dogwood AH

REFERRING VET

Dr. Caughman

INVOICE

92020

DATE

9/27/21

PRESENTING CLINICAL SIGNS

History: Cloud is a Diabetic well controlled on 1 unit PROZINC insulin twice daily. She has a history of recurrent urinary tract infections.

Glucose 283, creatinine 2.6, BUN 49. Hematuria- chronic.

ULTRASONOGRAPHIC EXAMINATION OF THE ABDOMEN

Urinary System

The **urinary bladder**, trigone, and pelvic urethra presented normal thicknesses and normal tone. The pelvic urethra was imaged 2.0 cm beyond the cystourethral junction. The ureters were not visible which is normal. No uroliths or sediment were visualized and anechoic urine was present. No evidence of inflammatory or neoplastic changes was noted. Ureteral papillae were normal.

The iliac trifurcation was unremarkable.

The **kidneys** revealed largely normal size and structure, corticomedullary definition and ratio (cortex 1/3 of medulla) were essentially maintained with some age-related loss of curvilinear patterns regarding the capsule and C/M junction. The cortices presented largely uniform texture with some increased echogenicity expected for this age patient. Medullary structure differed distinctly from that of the cortex and no evidence of pelvic dilation was present. Trace pyelectasia was noted in the right kidney.

Adrenal Glands

Both **adrenal glands** were visualized and recognized as having normal shape, size, position and echogenicity for this breed. The phrenic vasculature, glandular echogenicity and detail were unremarkable. Capsule, cortex, and medullary definition were normal for this age patient. The left adrenal gland measured 0.4 cm. The right adrenal gland measured 0.4 cm.

Spleen

The **spleen** presented a smooth homogeneous parenchyma hyperechoic to liver and renal cortical parenchyma. The capsule was smooth without noticeable expansion or deviation from within the spleen or adjacent pathology. The splenic vasculature demonstrated normal volume without signs of congestion or thrombosis. No sonographic evidence of acute or chronic inflammatory, neoplastic, or infarctual changes was noted.

Liver

The **liver** images submitted revealed subjectively normal liver size, contour, and structure. Parenchymal echogenicity was naturally coarse and hypoechoic to the spleen. Vascular and biliary tracts were of normal volume with no evidence of congestion. The gallbladder presented acceptably thin walls with primarily anechoic content. The cystic and common bile ducts were normal. No pathological hepatic lymphadenopathy was evident. No overt structural evidence of inflammatory, infiltrative or regenerative pathology was evident.



PATIENT	Gastrointestinal
Cloud Digiovanni	Examination of the gastrointestinal tract revealed a stomach and intestine free of stasis, of normal wall thickness, acceptable curvilinear mural detail, and peristaltic activity. Small and large intestine demonstrated normal luminal chyme and stool consistency respectively. No obstructive or overt infiltrative disease was noted. No associated abnormal lymphatic activity was noted.
SPECIES	
Feline	
BREED	Pancreas
Domestic Shorthair	The base and limbs of the pancreas were observed to be largely isoechoic to surrounding omental fat. Pancreatic duct and capsular contour were acceptably normal and parenchyma respected normal curvilinear patterns. No overt evidence of active inflammatory or neoplastic disease was noted.
SEX	
14 years	ULTRASONOGRAPHIC FINDINGS
AGE	Unremarkable abdomen, largely age related changes.
13 lbs	Slight renal pyelectasia.
WEIGHT	INTERPRETATION OF THE FINDINGS & FURTHER RECOMMENDATIONS
13 lbs	Full urinalysis is warranted. Given the underlying urinary tract infection this may be playing a significant role in the diabetic dysregulation. The kidneys do not appear end stage, complicating factors such as hypertension, toxin exposure and infectious disease should be considered for the diabetic dysregulation.
INTERPRETED BY	For an additional charge an internal medicine consult can be utilized through SonoPath.com . You can select the internal medicine drop down at http://spa.sonopath.com/ .
Eric Lindquist, DMV DABVP, Cert. IVUSS	One of the world's top internists & SonoPath associate Dr. Remo Lobetti BVSc, MMedVet, PhD, DECVIM can evaluate your case through SonoPath. https://sonopath.com/resources/sonopath-services/internal-medicine-teleconsultation-services
IMAGING PERFORMED BY	
Dr. Caughman	
HOSPITAL NAME	Potential Causes of Diabetic Dysregulation
Dogwood AH	This is a suggestive checkoff list when faced with an unregulated diabetic patient:
REFERRING VET	UTI
Dr. Caughman	Dietary indiscretion/intolerance
INVOICE	Pancreatitis
92020	Hyperthyroidism/hypothyroidism
	Exogenous steroids (including topical eye meds)
DATE	Cushing's
9/27/21	Acromegaly



PATIENT

Owner compliance

Cloud Digiovanni

Insulin quality issues

Antibodies to insulin

SPECIES

Underlying Neoplasia

Feline

Diffuse liver disease

BREED

Domestic Shorthair

SEX

14 years

AGE

13 lbs

WEIGHT

13 lbs

INTERPRETED BY

Eric Lindquist, DMV
DABVP, Cert. IVUSS

IMAGING PERFORMED BY

Dr. Caughman

HOSPITAL NAME

Dogwood AH

REFERRING VET

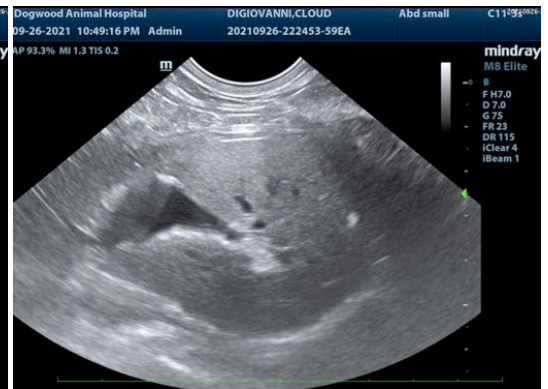
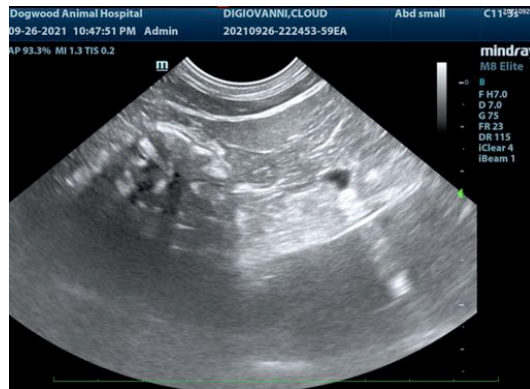
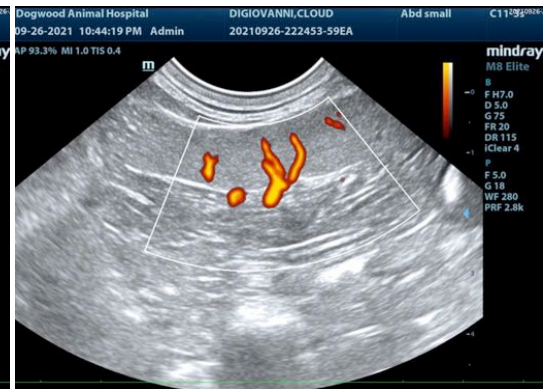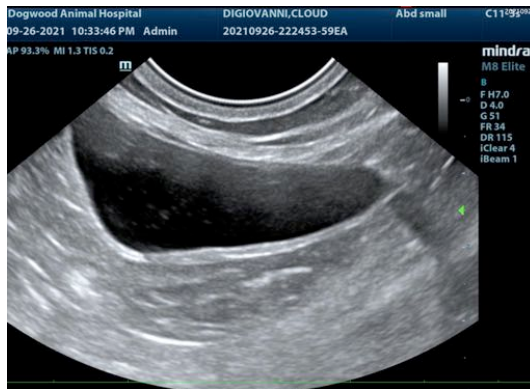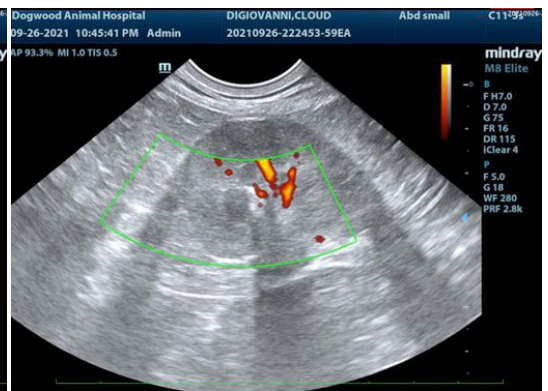
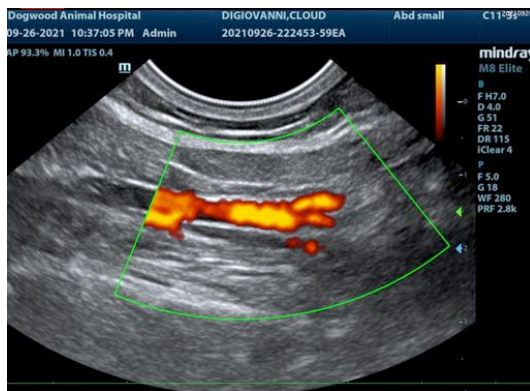
Dr. Caughman

INVOICE

92020

DATE

9/27/21





PATIENT

Cloud Digiovanni

SPECIES

Feline

BREED

Domestic Shorthair

SEX

14 years

AGE

13 lbs

WEIGHT

13 lbs

INTERPRETED BY

Eric Lindquist, DMV
DABVP, Cert. IVUSS

IMAGING PERFORMED BY

Dr. Caughman

HOSPITAL NAME

Dogwood AH

REFERRING VET

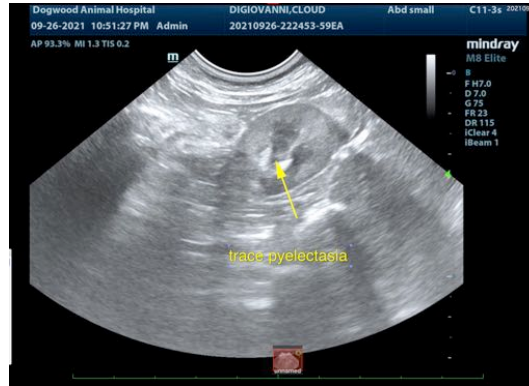
Dr. Caughman

INVOICE

92020

DATE

9/27/21



The information and recommendations provided are based on the images presented by the referring veterinarian. No evaluation can be communicated regarding pathology that was not visible in the image/video clips provided.

Thank you for this referral. If the clinical or image interpretation does not parallel your findings or if I can be of any further assistance please contact me.

Eric Lindquist, DMV, DABVP, Cert. IVUSS, CEO of SonoPath.com
info@SonoPath.com