



PATIENT PRESENTING CLINICAL SIGNS

Tokyo Ramirez presented for having 4 seizures in 1 day

SPECIES ULTRASONOGRAPHIC EXAMINATION OF THE ABDOMEN

Canine Urinary System

BREED The urinary bladder, trigone, and pelvic urethra presented normal thicknesses and normal tone. The ureters were not visible which is normal. No uroliths or sediment were visualized and anechoic urine was present. No evidence of inflammatory or neoplastic changes were noted. Ureteral papillae were normal.

SEX The kidneys revealed normal size and structure, corticomedullary definition and ratio for this age. The cortices presented largely uniform texture with normal echogenic relationship to liver and spleen. Medullary structure differed distinctly from the cortex and no evidence of pelvic dilation was present.

M The capsules were acceptably uniform without significant irregularities. The left kidney measured 5.11 cm in length. The right kidney measured 4.45 cm in length.

AGE The prostate appeared uniform measuring 2.0 cm.

3

Adrenal Glands

WEIGHT Both adrenal glands were visualized and recognized as having normal shape, size, position and echogenicity for this breed. The phrenic vasculature, glandular echogenicity and detail were unremarkable. Capsule, cortex, and medullary definition were normal for this age patient. The left adrenal gland measured 1.93 cm in length by 0.55 cm caudal pole width by 0.53 cm cranial pole width. The right adrenal gland measured 1.78 cm in length by 0.58 cm caudal pole width by 1.29 cm cranial pole width.

26.5

INTERPRETED BY

Eric Lindquist, DMV
DABVP, Cert. IVUSS

Spleen

The spleen presented a smooth homogeneous parenchyma hyperechoic to liver and renal cortical parenchyma. The capsule was smooth without noticeable expansion or deviation from within the spleen or adjacent pathology. The splenic vasculature demonstrated normal volume without signs of congestion or thrombosis. No sonographic evidence of acute or chronic inflammatory, neoplastic, or infarctual changes were noted.

IMAGING PERFORMED BY
Jenn

Liver

HOSPITAL NAME

Rockaway Animal
Hospital

The liver images submitted revealed subjectively normal liver size, contour, and structure. Parenchymal echogenicity was naturally coarse and hypoechoic to the spleen. Vascular and biliary tracts were of normal volume with no evidence of congestion. The gallbladder presented acceptably thin walls with primarily anechoic content. The cystic and common bile ducts were normal. No pathological hepatic lymphadenopathy was evident. No overt structural evidence of inflammatory, infiltrative or regenerative pathology was evident.

REFERRING VET

Dr. Maniar

Gastrointestinal

INVOICE

11710ag

Examination of the gastrointestinal tract revealed a stomach and intestine free of stasis, of normal wall thickness, acceptable curvilinear mural detail, and peristaltic activity. Small and large intestine demonstrated normal luminal chyme and stool consistency respectively. No obstructive or overt infiltrative disease was noted. No associated abnormal lymphatic activity was noted.

DATE

09/26/2022

Pancreas



PATIENT

Tokyo Ramirez

The base and limbs of the pancreas were observed to be largely isoechoic to surrounding omental fat. Pancreatic duct and capsular contour were acceptably normal and parenchyma respected normal curvilinear patterns. No overt evidence of active inflammatory or neoplastic disease was noted.

SPECIES

Canine

Free Abdomen

No omental masses, overt lymphadenopathy or peritoneal free fluid present.

BREED

Frenchie

ULTRASONOGRAPHIC FINDINGS

- Structurally unremarkable abdomen with no evidence of pathology

SEX

M

INTERPRETATION OF THE FINDINGS & FURTHER RECOMMENDATIONS

Given the patient's seizure activity a skull CT with contrast is indicated.

AGE

3

WEIGHT

26.5

INTERPRETED BY

Eric Lindquist, DMV
DABVP, Cert. IVUSS

IMAGING PERFORMED BY

Jenn

HOSPITAL NAME

Rockaway Animal
Hospital

REFERRING VET

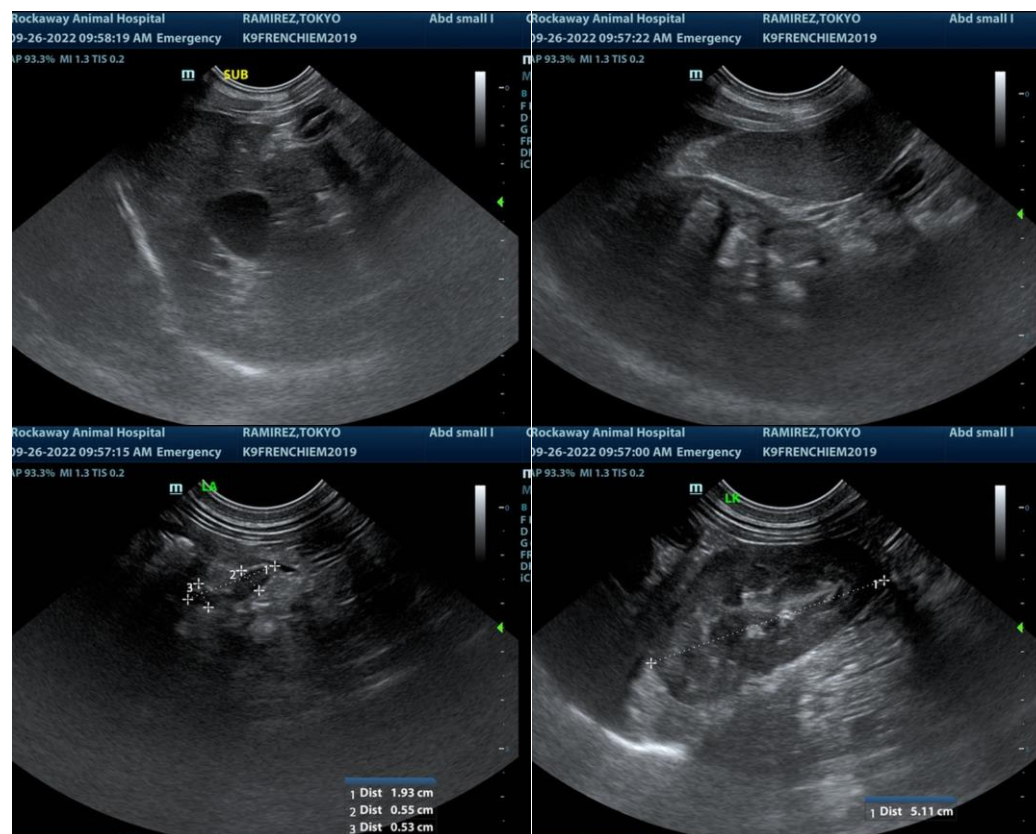
Dr. Maniar

INVOICE

11710ag

DATE

09/26/2022





PATIENT

Tokyo Ramirez

SPECIES

Canine

BREED

Frenchie

SEX

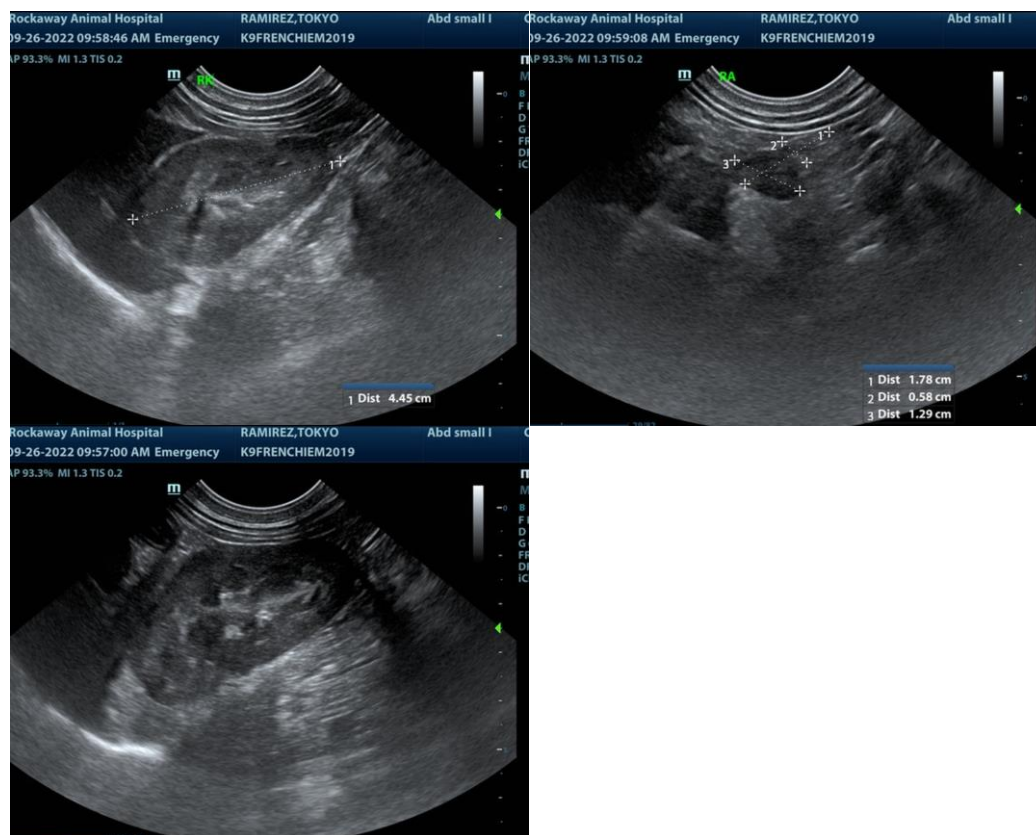
M

AGE

3

WEIGHT

26.5



INTERPRETED BY

Eric Lindquist, DMV
DABVP, Cert. IVUSS

The information and recommendations provided are based on the images presented by the referring veterinarian. No evaluation can be communicated regarding pathology that was not visible in the image/video clips provided.

IMAGING PERFORMED BY

Jenn

Thank you for this referral. If the clinical or image interpretation does not parallel your findings or if I can be of any further assistance please contact me.

HOSPITAL NAME

Rockaway Animal
Hospital

Eric Lindquist, DMV, DABVP, Cert. IVUSS, CEO of SonoPath.com
Eric.Lindquist@SonoPath.com

REFERRING VET

Dr. Maniar

INVOICE

11710ag

DATE

09/26/2022