


PATIENT

Margarita Abdulhani

PRESENTING CLINICAL SIGNS

 sneezing and occasional cough, fluid in chest and enlarged heart
 Abnormal PE/Chem/CBC/UA Results: mild lymphopenia

SPECIES

Feline

ULTRASONOGRAPHIC EXAMINATION OF THE HEART
****7 still images submitted.**
BREED

Himalayan

SEX

Spayed Female

AGE

9 Years

WEIGHT

3.9

FELINE CARDIAC PARAMETERS	BODY WEIGHT (kg)	HR (BPM)	IVSd (cm)	LVIDd (cm)	LVWd (cm)	FS (%)	EF (%)
NORMAL PARAMETER	-----	150-240	0.3-0.6	1.0-2.1	0.25-0.6	35-67	80-100
PATIENT		220	0.49	1.65	0.38	62	92
FELINE CARDIAC PARAMETERS	LA/AO (Boon)	LA/AO HEART BASE (Sisson)	LA 2D 4-chamber long axis AS to FW (Sisson) (cm)	LVOT VEL. (m/s)	RVOT VEL. (m/s)	IVRT (m/)	
NORMAL PARAMETER	<1.5	0.88-1.79	0.7-1.7	<1.6	<1.3	40-60	
PATIENT	1.1		--	--	0.78	NM	
Adapted from June Boon, Veterinary Echocardiography, 1998 Sisson D et al. JVIM 1991; 5: 232, Jacobs et al. Am J Vet Res 1985; 46:1705							

INTERPRETED BY

 Eric Lindquist, DMV
 DABVP, Cert. IVUSS

IMAGING PERFORMED BY

Dr. Jeff

HOSPITAL NAME

The Veterinary Surgery

REFERRING VET

Dr. Samad Khan

INVOICE

25791

DATE

9/24/21

Cardiac Presentation

The echocardiogram in this patient demonstrated normal **left atrial** size based on 3 separate LA measurements. The cranial and caudal **mitral** valve leaflets presented normal linear structure and kinetics. The **left ventricle** presented normal thicknesses with linear contour and was not dilated nor restricted. The **myocardium** presented normal echogenicity without subjective evidence of significant fibrotic or ischemic disease. **Contractility** of the ventricular walls was adequate and in normal range for this patient evidenced by the fractional shortening measurement and subjective evaluation of the different regions and angles of the myocardium. The **left ventricular outflow** tract demonstrated normal laminar flow and subjective structural integrity. The **right atrium** and auricle revealed normal size, structure and content. No evidence of masses was noted or chamber overload. **Tricuspid** valvular assessment demonstrated adequate linear morphology and kinetics. The **right ventricle** was of normal size (1/3 diameter of LV), chordae structure, myocardial echogenicity and thickness. **Pulmonic** tract assessment revealed normal valve structure, laminar flow, and diameter (approx. 1:1 pa/ao ratio). No visible **pericardial** or free pleura fluid was noted or extra cardiac pathology in the visible planes. The cranial **mediastinum** and **pericardial** regions were free of masses in the visible window.

ULTRASONOGRAPHIC FINDINGS

- Based on the 7 still images, no evidence of structural disease. Normal function, wall thicknesses and chamber sizes.

INTERPRETATION OF THE FINDINGS & FURTHER RECOMMENDATIONS

No contraindication to anesthetic procedure. Video clips with still images for measurements only is preferred. SDEP echo protocol recommended for complete evaluation.



PATIENT

Margarita Abdulhani

SPECIES

Feline

BREED

Himalayan

SEX

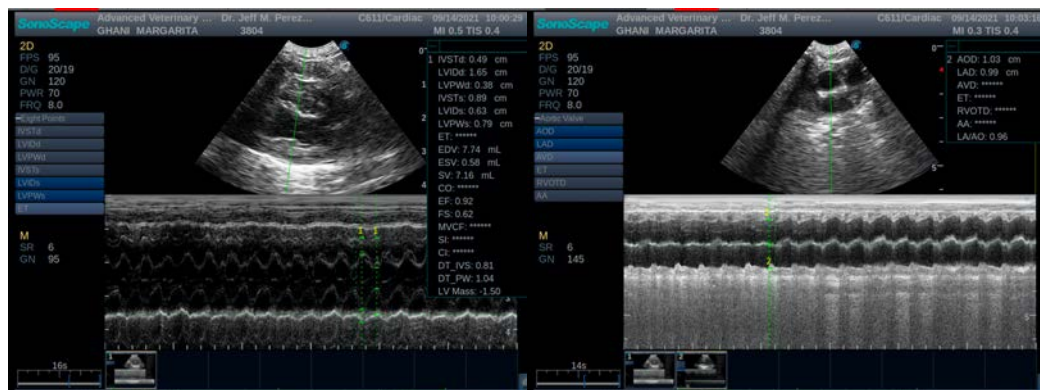
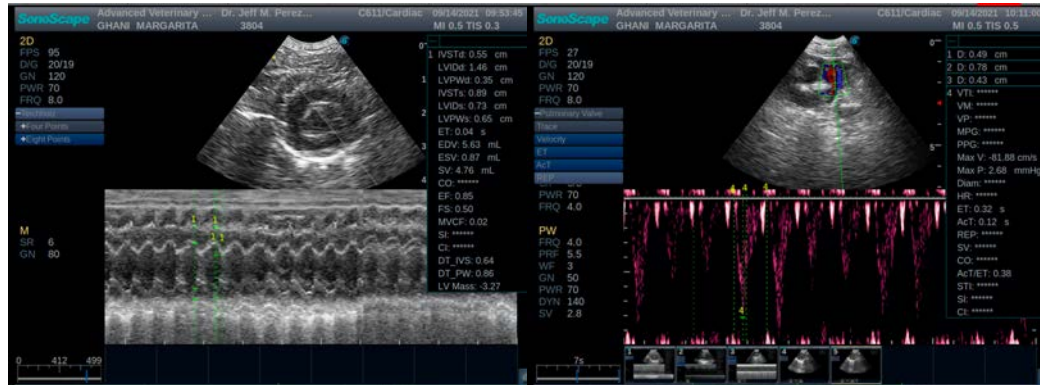
Spayed Female

AGE

9 Years

WEIGHT

3.9



INTERPRETED BY

Eric Lindquist, DMV
DABVP, Cert. IVUSS

IMAGING PERFORMED BY

Dr. Jeff

HOSPITAL NAME

The Veterinary Surgery

REFERRING VET

Dr. Samad Khan

INVOICE

25791

DATE

9/24/21

The information and recommendations provided are based on the images presented by the referring veterinarian. No evaluation can be communicated regarding pathology that was not visible in the image/video clips provided.

Thank you for this referral. If the clinical or image interpretation does not parallel your findings or if I can be of any further assistance please contact me.

Eric Lindquist, DMV, DABVP, Cert. IVUSS, CEO of SonoPath.com
info@SonoPath.com