



PATIENT PRESENTING CLINICAL SIGNS

Lily Alvarez History: Elevated liver values
Abnormal PE/Chem/CBC/UA Results: ALT 120, ALK PHOS 1498. LDDS pending

SPECIES

Canine

ULTRASONOGRAPHIC EXAMINATION OF THE ABDOMEN

Urinary System

BREED

Yorkie

The **urinary bladder**, trigone, and pelvic urethra presented normal thicknesses and normal tone. The ureters were not visible which is normal. No uroliths or sediment were visualized and anechoic urine was present. No evidence of inflammatory or neoplastic changes was noted. Ureteral papillae were normal.

SEX

Spayed Female

AGE

7 years

The **kidneys** revealed largely normal size and structure, corticomedullary definition and ratio (cortex 1/3 of medulla) were essentially maintained with some age-related loss of curvilinear patterns regarding the capsule and C/M junction. The cortices presented largely uniform texture with some increased echogenicity expected for this age patient. Medullary structure differed distinctly from that of the cortex. Slight pyelectasia was noted. The left kidney measured 4.5 cm. The right kidney measured 4.36 cm.

WEIGHT

12.2 lbs

Adrenal Glands

INTERPRETED BY

Eric Lindquist, DMV
DABVP, Cert. IVUSS

Both **adrenal glands** were visualized and recognized as having normal shape, size, position and echogenicity for this breed. The phrenic vasculature, glandular echogenicity and detail were unremarkable. Capsule, cortex, and medullary definition were normal for this age patient. The left adrenal gland measured 1.69 x 0.42 cm. The right adrenal gland measured 1.55 x 0.34 cm.

IMAGING PERFORMED BY

JK

Spleen

HOSPITAL NAME

Hamburg VC

The **spleen** presented a smooth homogeneous parenchyma hyperechoic to liver and renal cortical parenchyma. The capsule was smooth without noticeable expansion or deviation from within the spleen or adjacent pathology. The splenic vasculature demonstrated normal volume without signs of congestion or thrombosis. No sonographic evidence of acute or chronic inflammatory, neoplastic, or infarctual changes was noted.

REFERRING VET

Dr. DenHeyer

Liver

INVOICE

91976

Exam of the cranial abdomen demonstrated excessive **liver** size and swollen contour. Mild, coarse architecture was noted with increased portal markings and minor parenchymal remodeling is suggestive of an inflammatory component. Minor excessive GB debris was noted with the presence gall bladder dilation and precipitate without the overt formation of mucocele but this may be an issue in the future. This type of liver presentation typically is associated with slow and gradual SAP elevations with low-grade ALT rise. USG-FNA sampling is encouraged if more aggressive LE profiles are present such as ALT > 200 or rapid rise in SAP. These presentations are usually reactive hepatopathies owing to other disease processes either endocrine (Diabetes, Hypothyroidism, Cushing's disease), "antigen surveillance" from the gut/pancreas, or idiopathic breed predisposed progressions.

DATE

9/24/21



PATIENT

Gastrointestinal

Lily Alvarez

Examination of the **gastrointestinal tract** revealed a stomach and intestine free of stasis, of normal wall thickness, acceptable curvilinear mural detail, and peristaltic activity. Small and large intestine demonstrated normal luminal chyme and stool consistency respectively. No obstructive or overt infiltrative disease was noted. No associated abnormal lymphatic activity was noted.

SPECIES

Canine

BREED

Yorkie

SEX

Spayed Female

AGE

7 years

WEIGHT

12.2 lbs

Pancreas

Diffuse hyperechoic changes were present in the area of the **pancreas**. The pancreatic remodeling was evident with multifocal to diffuse hyperechoic changes. These changes are consistent with fibrosis, amyloid, saponification of fat and may contain areas of low-grade chronic active inflammation especially if pain on imaging (+ Murphy sign) was present +/- focal subxiphoid palpation reveals pain response. No overt masses were noted.

ULTRASONOGRAPHIC FINDINGS

Pancreatic remodeling.

Structurally normal adrenal glands.

Benign hepatopathy.

INTERPRETATION OF THE FINDINGS & FURTHER RECOMMENDATIONS

If the urine specific gravity is less than 1.020 then work-up for PDH is indicated given the patient's history. However, structurally the adrenal glands appear normal. A very small percentage of PDH patients can have normal adrenal glands. I recommend solid, definitive criteria for Cushing's is present prior to any potential treatment. Some level of pancreatic inflammation may be present.

INTERPRETED BY

Eric Lindquist, DMV
DABVP, Cert. IVUSS

IMAGING PERFORMED BY

JK

HOSPITAL NAME

Hamburg VC

REFERRING VET

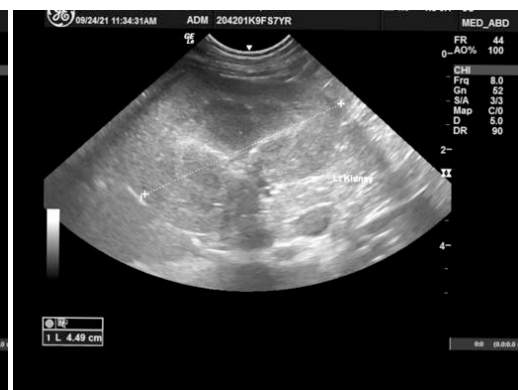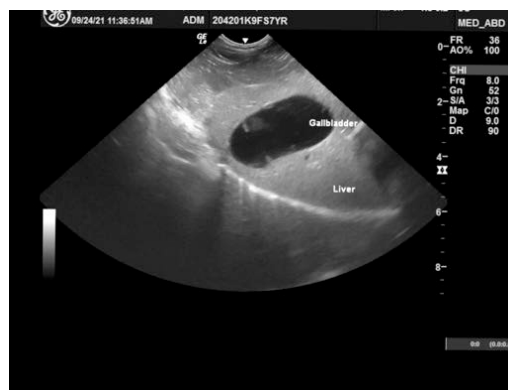
Dr. DenHeyer

INVOICE

91976

DATE

9/24/21





PATIENT

Lily Alvarez

SPECIES

Canine

BREED

Yorkie

SEX

Spayed Female

AGE

7 years

WEIGHT

12.2 lbs

INTERPRETED BY

Eric Lindquist, DMV
DABVP, Cert. IVUSS

IMAGING PERFORMED BY

JK

HOSPITAL NAME

Hamburg VC

REFERRING VET

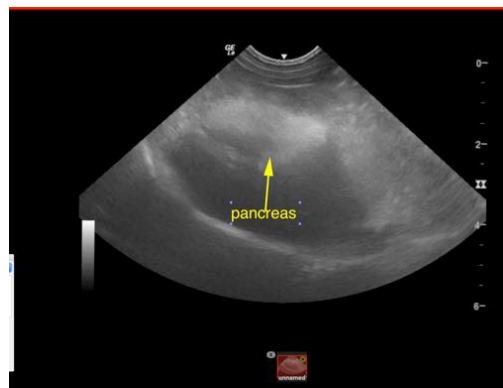
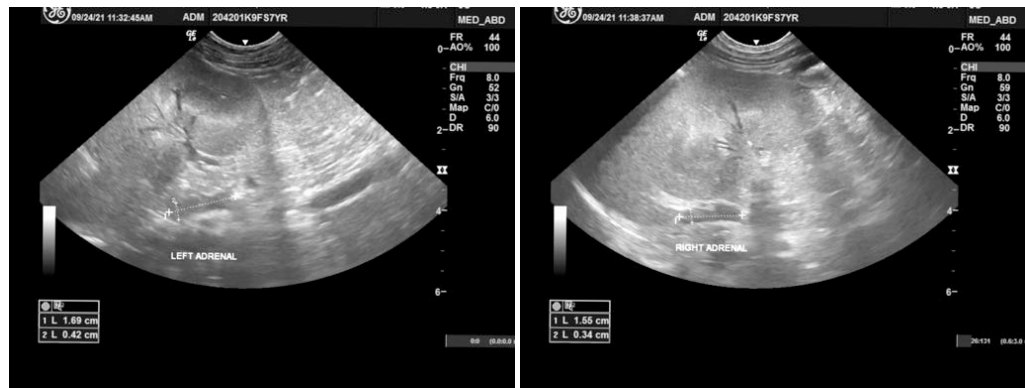
Dr. DenHeyer

INVOICE

91976

DATE

9/24/21



The information and recommendations provided are based on the images presented by the referring veterinarian. No evaluation can be communicated regarding pathology that was not visible in the image/video clips provided.

Thank you for this referral. If the clinical or image interpretation does not parallel your findings or if I can be of any further assistance please contact me.

Eric Lindquist, DMV, DABVP, Cert. IVUSS, CEO of SonoPath.com
info@SonoPath.com