



PATIENT PRESENTING CLINICAL SIGNS

Izzi Gaslan History: Coughing more frequently, history of murmur panting/anxious.
 Abnormal PE/Chem/CBC/UA Results: BP 115/95(106),177/91(122),167/106(134)

SPECIES ULTRASONOGRAPHIC EXAMINATION OF THE HEART

Canine

BREED

Mix

SEX

Spayed Female

AGE

14 years

WEIGHT

18 lbs

INTERPRETED BY

Eric Lindquist, DMV
 DABVP, Cert. IVUSS

IMAGING PERFORMED BY

JK

HOSPITAL NAME

Hamburg VC

REFERRING VET

Dr. Martens

The echocardiogram in this patient demonstrated normal **left atrial** size based on 3 different LA measurement methods. Chamber volumes and echogenicity were normal. The cranial and caudal **mitral** valve leaflets presented vegetative thickening consistent with endocardiosis. Doppler indicated measurable insufficiency. The **left ventricle** presented thicknesses with linear contour and was not dilated nor restricted. The **myocardium** presented normal echogenicity without subjective evidence of significant fibrotic or ischemic disease. **Contractility** of the ventricular walls was adequate and in normal range for this patient evidenced by the fractional shortening measurement and subjective evaluation of the different regions of the myocardium. The **left ventricular outflow** tract demonstrated normal laminar flow and subjective structural integrity. The **right atrium** and auricle revealed normal size, structure and content. No evidence of masses was noted or chamber overload. **Tricuspid** valvular assessment demonstrated adequate linear morphology. The **right ventricle** was of normal size (1/3 diameter of LV), chordae structure, myocardial echogenicity and thickness. **Pulmonic** tract assessment revealed normal valve structure, laminar flow, and diameter (approx.1:1 pa/ao ratio). No visible **pericardial** or free pleura fluid was noted. No echographically detectable evidence of infiltrative disease was visible. The cranial **mediastinum and pericardial regions** were free of masses in the visible window. Periodic arrhythmia was noted in this patient.

CANINE	MR	TR	LA/AO	LA/AO	FS	EF	EPSS
CARDIAC PARAMETERS	VMAX (m/s)	VMAX (m/s)	(Boon method)	(Heart Base; Swe)	(%)	(%)	(cm)
NORMAL PARAMETER	4.5-5.5	<2.7	1.3	<1.6	28-40	40-100	<0.6
PATIENT			1.4	1.4	53	85	0.2
CANINE	HR	AV	PV	BODY WEIGHT	LA	LVIDd	LVIDs
CARDIAC PARAMETERS	(BPM)	VMAX (m/s)	MAX (m/s)		2D short axis Base view (cm)	Avg; 2D and m-mode short axis (cm)	Avg; 2D and m-mode short axis (cm)
NORMAL PARAMETER	50-100	0.7-1.7	0.7-1.6				
PATIENT	84	1.3	0.8	18 lbs	3.0 max	3.38	

ULTRASONOGRAPHIC FINDINGS

Stage B1 valvular disease. There was no evidence of volume overload.
 Periodic arrhythmia.

INVOICE

91974

DATE

9/23/21



PATIENT

Izzi Gaslan

INTERPRETATION OF THE FINDINGS & FURTHER RECOMMENDATIONS

EKG is indicated. A recheck echocardiogram is recommended in 6 months or earlier if murmur grade increases or clinical signs initiate.

SPECIES

Canine

BREED

Mix

SEX

Spayed Female

AGE

14 years

WEIGHT

18 lbs

INTERPRETED BY

Eric Lindquist, DMV
DABVP, Cert. IVUS

IMAGING PERFORMED BY

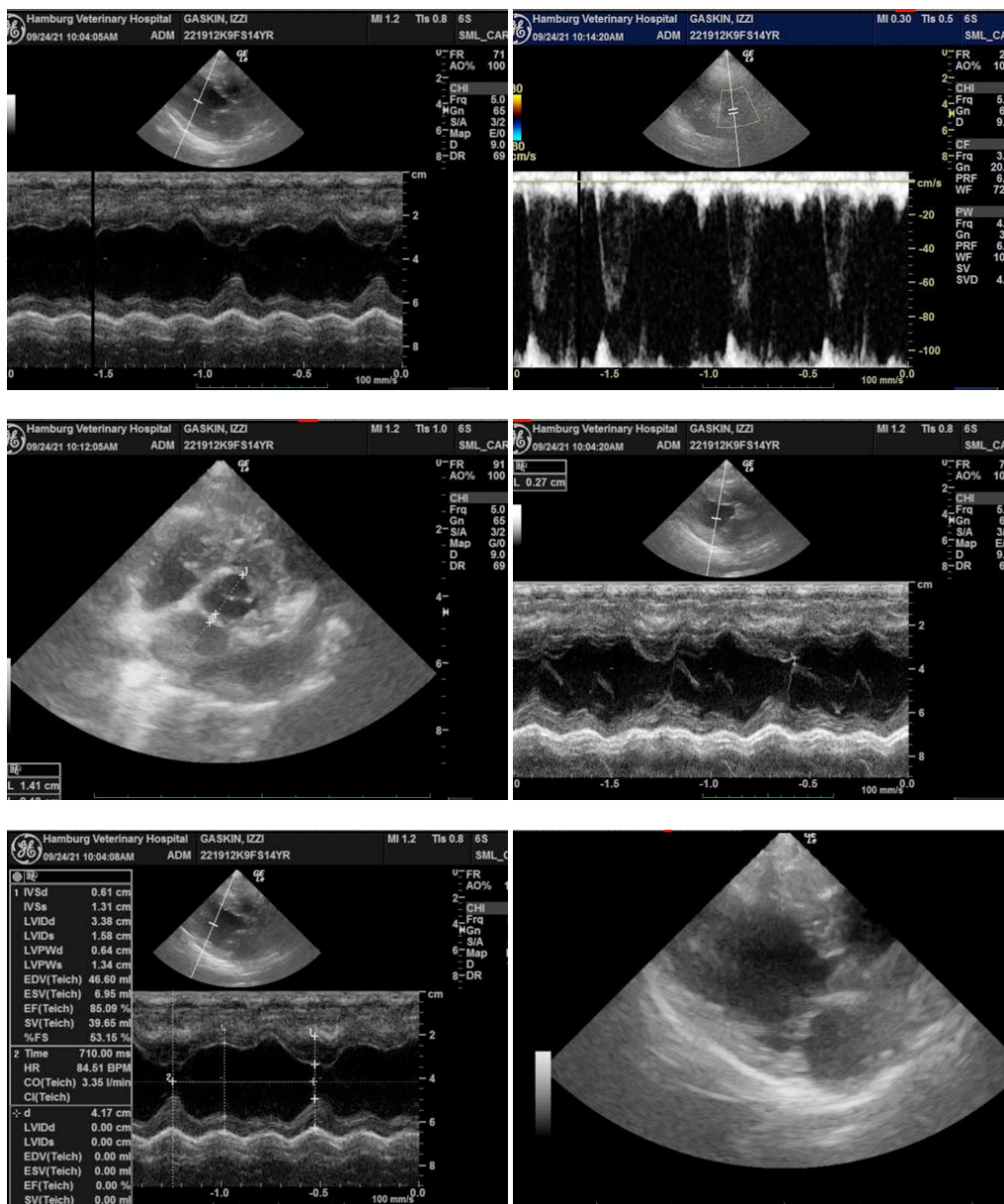
JK

HOSPITAL NAME

Hamburg VC

REFERRING VET

Dr. Martens



INVOICE

91974

DATE

9/23/21

The information and recommendations provided are based on the images presented by the referring veterinarian. No evaluation can be communicated regarding pathology that was not visible in the image/video clips provided.

Thank you for this referral. If the clinical or image interpretation does not parallel your findings or if I can be of any further assistance please contact me.



PATIENT

Eric Lindquist, DMV, DABVP, Cert. IVUSS, CEO of SonoPath.com
info@SonoPath.com

Izzi Gaslan

SPECIES

Canine

BREED

Mix

SEX

Spayed Female

AGE

14 years

WEIGHT

18 lbs

INTERPRETED BY

Eric Lindquist, DMV
DABVP, Cert. IVUSS

**IMAGING
PERFORMED BY**

JK

HOSPITAL NAME

Hamburg VC

REFERRING VET

Dr. Martens

INVOICE

91974

DATE

9/23/21