



PATIENT

Tilly Garcia

SPECIES

Canine

BREED

Chihuahua

SEX

Spayed Female

AGE

10 Years

WEIGHT

4 Pounds

INTERPRETED BY

Eric Lindquist, DMV
DABVP, Cert. IVUSS

IMAGING PERFORMED BY

Dr. Brittany Gardner,
DVM

HOSPITAL NAME

Wilvet Salem

REFERRING VET

Dr. Brittany Gardner,
DVM

INVOICE

17414

DATE

9/23/22

PRESENTING CLINICAL SIGNS

History: 9/21/2022 Not eating since Sunday, started vomiting bile, shaking intermittently and arching her back. Decreased water intake and activity. No chronic medical conditions. Only found vomit once last night. No changes in diet or new treats. Will get into cat food occasionally. Not known to ingest toys, blankets, etc. 9/23/2022 P ate about 1 tbsp yesterday and hasn't vomited anymore, but she has had really tarry diarrhea over night. She hasn't really gotten better, but hasn't gotten worse either.

Abnormal PE/Chem/CBC/UA Results: 9/21/2022 EPOC - slight hypocalcemia iCa 1.08 mmol/L, elevated lactate 5.48 mmol/L, HCT 58% CBC - HCT 51% Slight lymphopenia 1.04 K/uL (suspect stress leukogram) Eosinopenia 0.03 K/uL MPV 14.7 fL Chem 17- ALT 273 U/L, ALP 420 U/L Abdominal radiographs 3 view- left lateral ventral aspect appears to have potential of plication ventrally no overtly distended gas pattern, stomach has gas and soft tissue opacity Radiograph consultation- Stomach has gas, fluid, and amorphous soft tissue opacities. SI's normal in diameter gas, fluid, and granular soft tissue. No evidence of plication or obstructive pattern. Soft tissue opacity could be ingesta or foreign material of soft tissue opacity (textile/fabric, plastic) no evidence of current GI obstruction. Colon appearance suggestive of diarrhea. Recommendations of fecal and PLI. Could consider re-check 3 view radiographs in 12-16 hours with fast and/or abdominal ultrasound. Called (503) 290-8108 and spoke with Jessica went over labwork with elevations in liver enzymes and slight what appears to be stress induced response. There was an elevation in the lactate which can indicate perfusion changes as well. Also discussed the results of the radiographs with the stomach still having some soft tissue opacity. Since she has not been eating for the past 48 hours having the material still be present is a concern. No overt evidence of obstruction. Recommended doing hospitalization with IV fluids and doing abdominal ultrasound (assessing echotexture for abnormalities since values are elevated and concurrently assessing for foreign material) and a fecal and PLI. She was not sure if that would be possible for her at this time. We could attempt to do outpatient therapy and re-checking radiographs after her fasting on purpose. I would still strongly recommend the abdominal ultrasound as it sounds as though she has not been eating for an extended period of time. Talked about general costs and then let her know that I could have my staff put together an estimate and go over this more in depth with her. Jessica called back and declined doing hospitalization and further diagnostics at this time. Cerenia 1mg/kg SQ LRS 20mg/kg SQ 9/23/2022 IVC CBC: ***PULL BUT HOLD*** Chem17: BUN 6mg/dl (L), ALT 253u/l (H), ALP >2,000u/l (H), GGT 19u/l (H), TBili 1.0mg/dl (H), Amylase 1542u/l (H) ePOC: pco2 28.8mmhg (L), icalcium 1.07mmol/l (L), BUN 6mg/dl (L), hct 54% CPL: 450ng/ml - consistent for panc IV TX: IVF LRS 24ml/hr Cerenia 1mg/kg IV q24h Unasyn 30mg/kg IV TID Baytril 10mg/kg IV SID **SLOW** 0.015mg/kg Buprenorphine IV TID PRN 0.015mg/kg Buprenorphine for US Abdominal US + STAT - pending ORAL MEDS: RX: Denamarin for small dogs - Give 1/4 tablet by mouth every 24 hours for 7 days (1.75#) Monitor: TPR q4h BP q4h Walk q4h Weight q12h Offer bland LOW FAT diet q4h Recheck liver values q12h +/- NGT Placement SWO - gave results as above (stated that AUS was pending), and told o that i am concered for cholangiohepatitis , and pancreatitis. recommend that the p is hospitalized on fluids, abx, pain meds, liver support, and gi support. told o that if the p does not start eating by tomorrow then we will also need to place a NGT. o understands, and gave the ok for this plan. will update the o in the morning on how the p did overnight.

ULTRASONOGRAPHIC EXAMINATION OF THE ABDOMEN

Urinary System

The **urinary bladder**, trigone, and pelvic urethra presented normal thicknesses and normal tone. The ureters were not visible which is normal. No uroliths or sediment were visualized, and anechoic urine



PATIENT

Tilly Garcia

was present. No evidence of inflammatory or neoplastic changes were noted. Ureteral papillae were normal. The pelvic urethra was imaged 1.0 cm beyond the cystourethral junction.

SPECIES

Canine

The **kidneys** revealed largely normal size and structure, corticomedullary definition and ratio (cortex 1/3 of medulla) were essentially maintained with some minor age-related loss of curvilinear patterns regarding the capsule and C/M junction. The cortices presented largely uniform texture with some increased echogenicity expected for his age patient. Medullary structure differed distinctly from that of the cortex and no evidence of pelvic dilation was present. Both kidneys measured 4.0 cm.

BREED

Chihuahua

Adrenal Glands

SEX

Spayed Female

The **left adrenal gland** was visualized and recognized as having normal shape, size, position and echogenicity for this breed. The phrenic vasculature, glandular echogenicity and detail were unremarkable. Capsule, cortex, and medullary definition were normal for this age patient. The left adrenal gland measured 0.5 cm

The region of the **right adrenal gland** was imaged and revealed no evident pathology.

AGE

10 Years

Spleen

WEIGHT

4 Pounds

The **spleen** presented a smooth homogeneous parenchyma hyperechoic to liver and renal cortical parenchyma. The capsule was smooth without noticeable expansion or deviation from within the spleen or adjacent pathology. The splenic vasculature demonstrated normal volume without signs of congestion or thrombosis. No sonographic evidence of acute or chronic inflammatory, neoplastic, or infarctual changes were noted.

Liver

INTERPRETED BY

Eric Lindquist, DMV
DABVP, Cert. IVUSS

The **liver** was significantly subnormal in size with irregular contour and increased portal markings. The gallbladder was mildly echogenic.

Gastrointestinal

IMAGING PERFORMED BY

Dr. Brittany Gardner,
DVM

Examination of the **gastrointestinal tract** revealed a stomach and intestine free of stasis, of normal wall thickness, acceptable curvilinear mural detail, and peristaltic activity. Small and large intestine demonstrated normal luminal chyme and stool consistency respectively. No obstructive or overt infiltrative disease was noted. No associated abnormal lymphatic activity was noted.

HOSPITAL NAME

Wilvet Salem

Pancreas

The base and limbs of the **pancreas** were observed to be largely isoechoic to surrounding omental fat. Pancreatic duct and capsular contour were acceptably normal and parenchyma respected normal curvilinear patterns. No overt evidence of active inflammatory or neoplastic disease was noted.

REFERRING VET

Dr. Brittany Gardner,
DVM

ULTRASONOGRAPHIC FINDINGS

- Microhepatica with chronic cholangitis pattern
- Age-related renal changes

INVOICE

17414

INTERPRETATION OF THE FINDINGS & FURTHER RECOMMENDATIONS

No overt evidence of intrahepatic or extrahepatic shunting. Acute on chronic liver failure. Leptospirosis titers and other inciting causes of cholangiohepatitis should be evaluated. However, primary microhepatica/portal hypoplasia/microvascular dysplasia is likely playing a role. Liver biopsy

DATE

9/23/22



PATIENT

would be ideal.

Tilly Garcia

SPECIES

Canine

BREED

Chihuahua

SEX

Spayed Female

AGE

10 Years

WEIGHT

4 Pounds

INTERPRETED BY

Eric Lindquist, DMV
DABVP, Cert. IVUSS

IMAGING PERFORMED BY

Dr. Brittany Gardner,
DVM

HOSPITAL NAME

Wilvet Salem

REFERRING VET

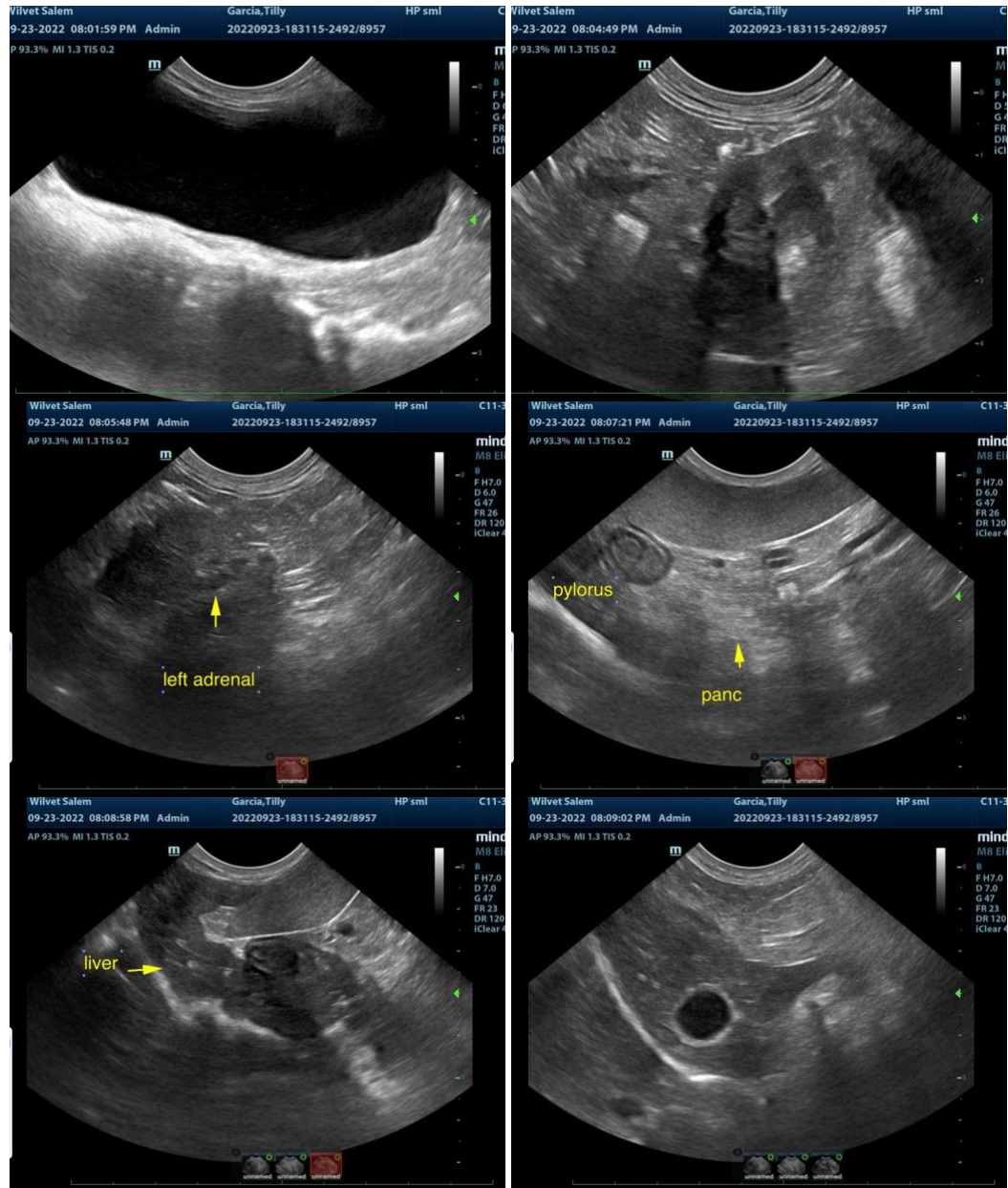
Dr. Brittany Gardner,
DVM

INVOICE

17414

DATE

9/23/22





PATIENT

Tilly Garcia

SPECIES

Canine

BREED

Chihuahua

SEX

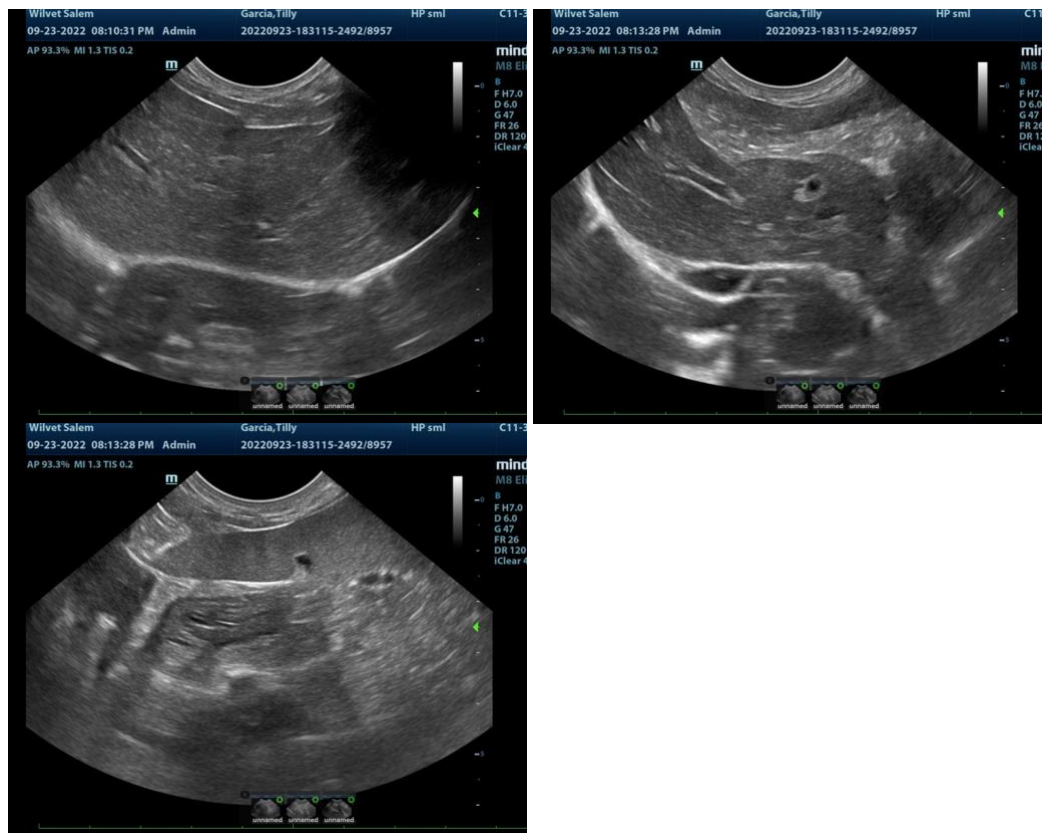
Spayed Female

AGE

10 Years

WEIGHT

4 Pounds



INTERPRETED BY

Eric Lindquist, DMV
DABVP, Cert. IVUSS

IMAGING PERFORMED BY

Dr. Brittany Gardner,
DVM

HOSPITAL NAME

Wilvet Salem

REFERRING VET

Dr. Brittany Gardner,
DVM

INVOICE

17414

DATE

9/23/22

The information and recommendations provided are based on the images presented by the referring veterinarian. No evaluation can be communicated regarding pathology that was not visible in the image/video clips provided.

Thank you for this referral. If the clinical or image interpretation does not parallel your findings or if I can be of any further assistance please contact me.

Eric Lindquist, DMV, DABVP, Cert. IVUSS, CEO of SonoPath.com
info@SonoPath.com

Canine Liver Disease & Treatment Recommendations

<http://www.sonopath.com/K9LiverDisease>

Description: The etiologic causes of canine hepatic disease are vast and varied. Some cases may progress fairly rapidly, while others will remain static for a considerable length of time or even eventually reverse. Regardless of the cause, management is crucial to maintaining and optimizing quality of life. If possible, practitioners should obtain and be guided by a pathologic diagnosis so they can administer a treatment attuned to the underlying disease and arrive at a more exact prognosis.

Dietary Management: A lower protein diet to support liver dysfunction should be initiated, especially in cases where hepatic encephalopathy is also present. Since dietary protein is low, the protein quality and bioavailability must conversely be high. It should be noted that a protein-restricted diet is not appropriate in



PATIENT

Tilly Garcia

all cases of hepatic disease, especially during the early phases, as protein restriction is unnecessary when there are no signs of significant hepatic dysfunction.

SPECIES

Canine

Therapeutic diets, such as Hill's® i/d® and Royal Canin® Hepatic™, are excellent choices and contain enhanced levels of nutrients such as, but not limited to:

BREED

Chihuahua

- Branched chain amino acids, which bypass liver metabolism and are used directly for skeletal muscle accretion.
- Vitamin E, which helps minimize and reduce oxidative damage and stress from free radicals produced by stressed hepatocytes.
- Vitamin B complex, which helps drive intermediary metabolism.
- Reduced copper.
- Extremely digestible protein sources with high biologic values, which help minimize the total amount of dietary protein needed and thus reduce blood ammonia levels.
- Carnitine, which helps drive fatty acids into the mitochondria for beta-oxidation and positive cellular energy balance.

AGE

10 Years

Medical Management: The following list of medications is commonly used in the management of various hepatopathies or in the face of hepatic failure; however, each patient should be managed as an individual, and not all of the medications listed here are appropriate for each animal. One must always consider the definitive diagnosis of one's patient when developing a therapeutic plan. What follows is an outline of medical management recommendations for cholangiohepatitis and inflammatory hepatopathy/chronic hepatitis.

WEIGHT

4 Pounds

Cholangiohepatitis

1. Broad-spectrum antibiotics

INTERPRETED BY

Eric Lindquist, DMV
DABVP, Cert. IVUSS

a) Amoxicillin: Give 20 mg/kg BID or amoxicillin/clavulanic acid (13.75 mg/kg PO BID) for potential suppurative hepatitis. Options: ampicillin: 20 mg/kg IV TID; cephalexin: 20 mg/kg IV or PO TID; enrofloxacin: 2.5-5 mg/kg PO BID if cholangiohepatitis is present or to decrease ammonia production; gentamycin: 2 mg/kg TID IM or SC for 5-7 days if sepsis or peritonitis is present. Monitor renal function if aminoglycosides are utilized.

IMAGING PERFORMED BY

Dr. Brittany Gardner,
DVM

b) Metronidazole: Give 10-20 mg/kg BID in combination with amoxicillin/clavulanic acid or enrofloxacin for cholangiohepatitis because of its efficacy against anaerobic bacteria and/or its immunomodulating effects. The dose is decreased to 7.5 mg/kg PO TID in the face of hepatic failure and/or encephalopathy. Controls ammonia production in the colon, decreases bacteria absorbed through portal circulation, and reduces cell-mediated immune responses (anti-inflammatory properties).

HOSPITAL NAME

Wilvet Salem

2. Hepatic support

REFERRING VET

Dr. Brittany Gardner,
DVM

a) S-adenosylmethionine (SAME): Give 20 mg/kg/day PO on an empty stomach (1-2 hours before feeding). It is available in 90 mg tablets that are not to be broken. SAME replenishes glutathione and aids in cellular detoxification; it also has anti-arthritis effects. SAME is an anti-inflammatory and antioxidant. It also promotes hepatocellular regeneration and rectifies RBC membrane abnormalities in dogs with liver disease or oxidative damage.

INVOICE

17414

b) Milk Thistle: Administer as silybin or silymarin extracts (a high-quality supplement is essential). Acts as an antioxidant and free radical scavenger; decreases hepatotoxin binding; improves glutathione concentrations; aids in iron chelating; and promotes choleresis. Give 5-15 mg/kg/day PO.

DATE

9/23/22



PATIENT

Tilly Garcia

c) Ursodiol (Actigall): Give 10-15 mg/kg PO once daily, with food, to stimulate bile flow and decrease cholestasis. Tablets (250 mg) or capsules (300 mg) are available; however, ursodiol can also be compounded into a liquid to dose small patients. It has immunomodulatory, anti-fibrotic, and cholcretic effects, anti-copper storage benefits, and stabilizes mitochondrial function.

SPECIES

Canine

d) Vitamin E: Must be coupled with good nutrition and other antioxidants to avoid accumulation of tocopheroxyl radicals. To that end, supplementation with SAME may help ensure that adequate GSH (mitochondrial glutathione) concentrations are achieved. Give 10-15 IU/kg/day PO (100-400 IU) in a water-soluble form twice daily, as well as with Vitamin C 25 mg/kg/day.

BREED

Chihuahua

e) Cobalamin and Thiamine (B12 and B1): Give 250ug SC weekly.

SEX

Spayed Female

Inflammatory hepatopathy/chronic hepatitis

1. Immunosuppressive agents

AGE

10 Years

a) Prednisone or prednisolone: Administer if inflammatory disease has been diagnosed by biopsy, beginning at 2 mg/kg/day for 2-4 weeks; subsequently reduce to 1 mg/kg/day. Once remission has been achieved, taper to 0.5 mg/kg/day (or to the lowest tolerable dose) over 2-4 weeks. Steroids may be discontinued if a different immunosuppressive medication is effective at controlling inflammation (i.e., azathioprine or cyclosporine) since they are contraindicated with hepatic encephalopathy. Possible negative sequelae of corticosteroids include increased water retention and potentiation of gastrointestinal ulceration. In the face of portal hypertension and ascites, dexamethasone is preferred—it does not exhibit mineralocorticoid activity and thus does not potentiate water retention as compared to prednisone—at 0.2-0.4 mg/kg orally once daily. Taper in a similar manner.

WEIGHT

4 Pounds

INTERPRETED BY

Eric Lindquist, DMV
DABVP, Cert. IVUSS

b) Azathioprine (Imuran): Give 50 mg/m²/day or 2 mg/kg/day as a long-term alternative to prednisone. The dose can be decreased to 1 mg/kg and eventually given every other day if there is a positive response. Check CBC and platelet count biweekly for the first 2 months and then monthly thereafter. Taper every 2-4 weeks to the lowest effective dose while monitoring transaminase levels. It can often be dosed on alternate days to prednisone. Possible negative side effects include bone marrow suppression and hepatic necrosis. Cyclosporine has been proposed as an alternative immunosuppressant in the management of chronic hepatitis and may allow one to cease concurrent steroid therapy; however, this has not been thoroughly investigated as of yet.

IMAGING PERFORMED BY

Dr. Brittany Gardner,
DVM

HOSPITAL NAME

Wilvet Salem

2. Hepatic Support

See medications listed in the previous section.

REFERRING VET

Dr. Brittany Gardner,
DVM

3. Anti-fibrotics

a) Colchicine: Give 0.03 mg/kg/day. Colchicine acts as an anti-inflammatory agent, stabilizes membranes, and stimulates collagenase production, thereby diminishing fibrosis. Colchicine should be used to treat hepatic fibrosis based on biopsy results; however, it can also be considered when ascites is present, and when hepatic fibrosis and cirrhosis are highly suspected based on sonographic appearance and clinical findings. It can result in adverse effects, including vomiting, diarrhea, and inappetence. Discontinue until clinical signs resolve, and reinstitute at a lower dose and up-titrate slowly.

INVOICE

17414

DATE

9/23/22

4. Hepatic Encephalopathy



PATIENT

Tilly Garcia

a) Lactulose: Give 0.5 ml/kg orally 2-3 times daily to soften the stool. It helps manage hepatic encephalopathy by combining with ammonium in the GI tract and thus decreasing circulating ammonia levels. Use in conjunction with low dose metronidazole. Lactulose can also be given as a retention enema in an encephalopathic crisis.

SPECIES

Canine

b) Metronidazole: Give at 7.5 mg/kg PO TID. Neomycin is an alternative and can be administered at 22 mg/kg PO BID-TID.

BREED

Chihuahua

c) L-Carnitine: Give 200-400 mg/day. Normally synthesized by the liver, L-Carnitine enhances ammonia elimination and is indicated in cases of hepatic encephalopathy and lipidosis. Carnitine must be in the L-form.

SEX

Spayed Female

5. Copper Chelation

Use chelation when copper toxicity has been documented on biopsy and quantification has been performed to confirm toxic levels.

AGE

10 Years

a) D-penicillamine: Give 10-15 mg/kg PO BID on an empty stomach. This is a copper chelator and should only be used based on a quantitative analysis of copper. Possible side effects include vomiting and inappetence. Do not give in conjunction with zinc.

WEIGHT

4 Pounds

b) 2,3,2 Tetramine (Syprine, Cuprid): Give 5-7 mg/kg PO BID on an empty stomach (1-2 hours before eating). An alternative to D-penicillamine for those dogs that are intolerant.

c) Zinc gluconate, acetate, or sulfate (acetate is best tolerated): Give 15-10 mg/kg elemental zinc divided BID for 2-6 months as a loading dose. Administer on an empty stomach (30-60 minutes before eating). Reduce to half the dose during the maintenance phase. A low copper diet is preferred (i.e., therapeutic diets, such as Hill's I/d® or Royal Canin® Hepatic™, are advisable). Zinc binds with intestinal copper to avoid absorption in the gastrointestinal tract and may be used alone in mild cases of copper toxicity. The goal is to reach zinc serum levels of 200-600 ug/dl; levels should initially be measured every 2-3 months. Give this medication on an empty stomach or with tuna fish to avoid vomiting. Zinc is not as effective as D-penicillamine and is only used in mild cases. It is not used in conjunction with D-penicillamine.

INTERPRETED BY

Eric Lindquist, DMV
DABVP, Cert. IVUSS

IMAGING PERFORMED BY

Dr. Brittany Gardner,
DVM

HOSPITAL NAME

Wilvet Salem

6. Portal Hypertension and Ascites

a) Spironolactone: If ascites is present secondary to portal hypertension, spironolactone can be dosed at 1-2 mg/kg PO BID; it is the diuretic of choice. Alternatively, spironolactone can be used in conjunction with furosemide (0.5-1 mg/kg PO BID) or hydrochlorothiazide; one should administer 1 mg/kg PO BID if given in conjunction with another diuretic. Monitor renal function and electrolytes diligently.

b) Famotidine: Give 0.5 mg/kg PO BID in cases of portal hypertension that result in gastrointestinal bleeding/melena.

REFERRING VET

Dr. Brittany Gardner,
DVM

INVOICE

17414

DATE

9/23/22

General Notes on Therapeutic Management: Given that a primary function of the liver is to metabolize oral medications via the portal system (first past effect), numerous medications may result in higher systemic exposure to parent compounds in the face of hepatic insufficiency or failure. Drugs that are inactivated by the liver, produce hepatic damage, or require hepatic metabolism should be avoided. These include: lincomycin, clindamycin, streptomycin, chloramphenicol, sulfonamides, erythromycin, hetacillin, phenobarbital, diazepam, oxy- or chloro-tetracyclines, azole antifungals, nonsteroidal anti-inflammatory drugs (NSAIDs), theophylline or chloramphenicol, combinations of cimetidine and metronidazole, and



PATIENT

Tilly Garcia

combinations of enrofloxacin and theophylline or cisapride. In cases of hepatic lipidosis, glucocorticoids, anabolic steroids, and lipotropic agents containing methionine should be avoided as they result in the production of encephalopathic toxins (metacarpans). Glucocorticoids are indicated for cholangitis, but only after lymphoma and hepatic lipidosis have been ruled out.

SPECIES

Canine

References:

Bauer E. Hepatic disease, nutritional therapy, and the metabolic environment. *J Am Vet Med Assoc* 1996;209(11):1850-54.

BREED

Chihuahua

Bradley AM and Twedt DC. Cyclosporine therapy for canine chronic hepatitis: a retrospective study. Proceedings from the American College of Veterinary Internal Medicine, Anaheim, CA, June 15-18, 2011.

SEX

Spayed Female

Center SA. Chronic hepatitis, cirrhosis, breed-specific hepatopathies, copper storage hepatopathy, suppurative hepatitis, granulomatous hepatitis, and idiopathic hepatic fibrosis. In: Guilford WG, Center SA, Strombeck DR, Williams DA, and Meyer DJ, eds: *Strombeck's Small Animal Gastroenterology 3rd ed*. Philadelphia, PA: WB Saunders; 1996:705-65.

AGE

10 Years

Center S. Metabolic, antioxidant, nutraceutical, probiotic, and herbal therapies relating to the management of hepatobiliary disorders. *Vet Clin North Am Small Anim Pract* 2004;34(1):67-172.

WEIGHT

4 Pounds

Center SA. Diagnostic and managerial pearls for selected hepatobiliary disorders. Proceedings from the American College of Veterinary Internal Medicine. New Orleans, LA, May 30-June 2, 2012.

INTERPRETED BY

Eric Lindquist, DMV
DABVP, Cert. IVUSS

Davenport D. Antimicrobial therapy for gastrointestinal, pancreatic, and hepatic disorders. *Probl Vet Med* 1990;2(2):374-93.

Hackett T, Twedt D, Gustafson D. Milk thistle and its derivative compounds: a review of opportunities for treatment of liver disease. *J Vet Intern Med* 2013;27(1):10-16.

IMAGING PERFORMED BY

Dr. Brittany Gardner,
DVM

Thompson M, Meyer D, Senior D. Effects of treatment with ursodeoxycholic acid on bile acid profiles in a dog with chronic hepatic disease. *J Vet Intern Med* 1991;5(2):130.

HOSPITAL NAME

Wilvet Salem

REFERRING VET

Dr. Brittany Gardner,
DVM

INVOICE

17414

DATE

9/23/22