



PATIENT

Jerzee Madonna

SPECIES

Canine

BREED

Toy Poodle

SEX

Spayed Female

AGE

12 Years

WEIGHT

12.4 Pounds

INTERPRETED BY

Eric Lindquist, DMV
DABVP, Cert. IVUSS

IMAGING PERFORMED BY

Jack Reese

HOSPITAL NAME

Willow Run VC

REFERRING VET

Anna Leppien, DVM

INVOICE

17431

DATE

9/23/22

PRESENTING CLINICAL SIGNS

History: Severe month history of soft stools and tenesmus at home. Recently broke with diarrhea. Owner has been feeding i/d low fat diet at home with minimal response.

Abnormal PE/Chem/CBC/UA Results: ALKP 349 No other abnormalities on labwork (July 2022)
Maldigestion Profile pending

ULTRASONOGRAPHIC EXAMINATION OF THE ABDOMEN

Urinary System

The **urinary bladder**, trigone, and pelvic urethra presented normal thicknesses and normal tone. The ureters were not visible which is normal. No uroliths or sediment were visualized, and anechoic urine was present. No evidence of inflammatory or neoplastic changes were noted. Ureteral papillae were normal. The pelvic urethra was imaged 2.0 cm beyond the cystourethral junction.

The **kidneys** revealed largely normal size and structure, corticomedullary definition and ratio (cortex 1/3 of medulla) were essentially maintained with some mild age-related loss of curvilinear patterns regarding the capsule and C/M junction. The cortices presented largely uniform texture with some increased echogenicity expected for his age patient. Medullary structure differed distinctly from that of the cortex and no evidence of pelvic dilation was present. Mineralization was present in the kidneys. The left kidney measured 4.5 cm. The right kidney measured 4.9 cm. Minor cortical cysts were noted in the kidneys.

Adrenal Glands

Both **adrenal glands** were visualized and recognized as having normal shape, size, position and echogenicity for this breed. The phrenic vasculature, glandular echogenicity and detail were unremarkable. Capsule, cortex, and medullary definition were normal for this age patient. The right adrenal gland measured 0.81 cm at the cranial pole and 0.6 cm at the caudal pole. The left adrenal gland measured 0.42 cm at the caudal pole and 0.44 cm at the cranial pole.

Spleen

The **spleen** presented a smooth homogeneous parenchyma hyperechoic to liver and renal cortical parenchyma. The capsule was smooth without noticeable expansion or deviation from within the spleen or adjacent pathology. The splenic vasculature demonstrated normal volume without signs of congestion or thrombosis. No sonographic evidence of acute or chronic inflammatory, neoplastic, or infarctual changes were noted.

Liver

The **liver** was uniformly swollen with minor, excessive gallbladder debris and over distension with dependent and suspended bile without evidence of overt mucocele formation. However, excessive sludge was present. The liver presented coarse architecture with mildly increased portal markings and subtle, mixed echogenic changes. This is consistent with vacuolar hepatopathy and some level of remodeling and history of inflammatory component. There was no overt suspicion of neoplasia.

Gastrointestinal

There was some residual chyme and gas was noted in the **stomach**, yet not pathological. This is consistent with end post prandial presentation. Transit of chyme into the small intestine was normal.



PATIENT

Jerzee Madonna

Curvilinear patterns were maintained throughout the GI tract. No evidence of pathology. Small and large intestine demonstrated normal luminal chyme and stool consistency respectively. No obstructive or overt infiltrative disease was noted. No associated abnormal lymphatic activity was noted.

SPECIES

Canine

Pancreas

The base and limbs of the **pancreas** were observed to be largely isoechoic to surrounding omental fat. Pancreatic duct and capsular contour were acceptably normal and parenchyma respected normal curvilinear patterns. No overt evidence of active inflammatory or neoplastic disease was noted.

BREED

Toy Poodle

ULTRASONOGRAPHIC FINDINGS

SEX

Spayed Female

- Structurally unremarkable abdomen
- Minor age related benign hepatopathy
- Mild to moderate degenerative renal changes with mineralizations
- Partially full stomach

AGE

12 Years

INTERPRETATION OF THE FINDINGS & FURTHER RECOMMENDATIONS

No evidence of structural pathology. The gastrointestinal presentation is consistent with postprandial presentation.

WEIGHT

12.4 Pounds

INTERPRETED BY

Eric Lindquist, DMV
DABVP, Cert. IVUSS

IMAGING PERFORMED BY

Jack Reese

HOSPITAL NAME

Willow Run VC

REFERRING VET

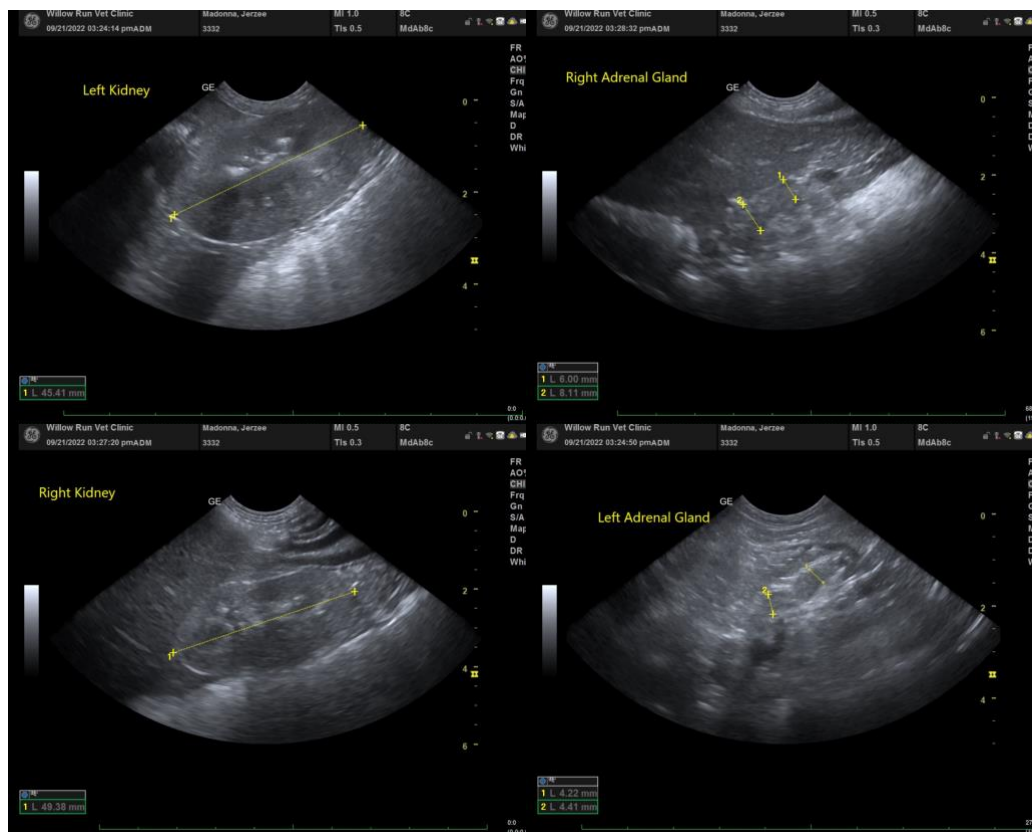
Anna Leppien, DVM

INVOICE

17431

DATE

9/23/22





PATIENT

Jerzee Madonna

SPECIES

Canine

BREED

Toy Poodle

SEX

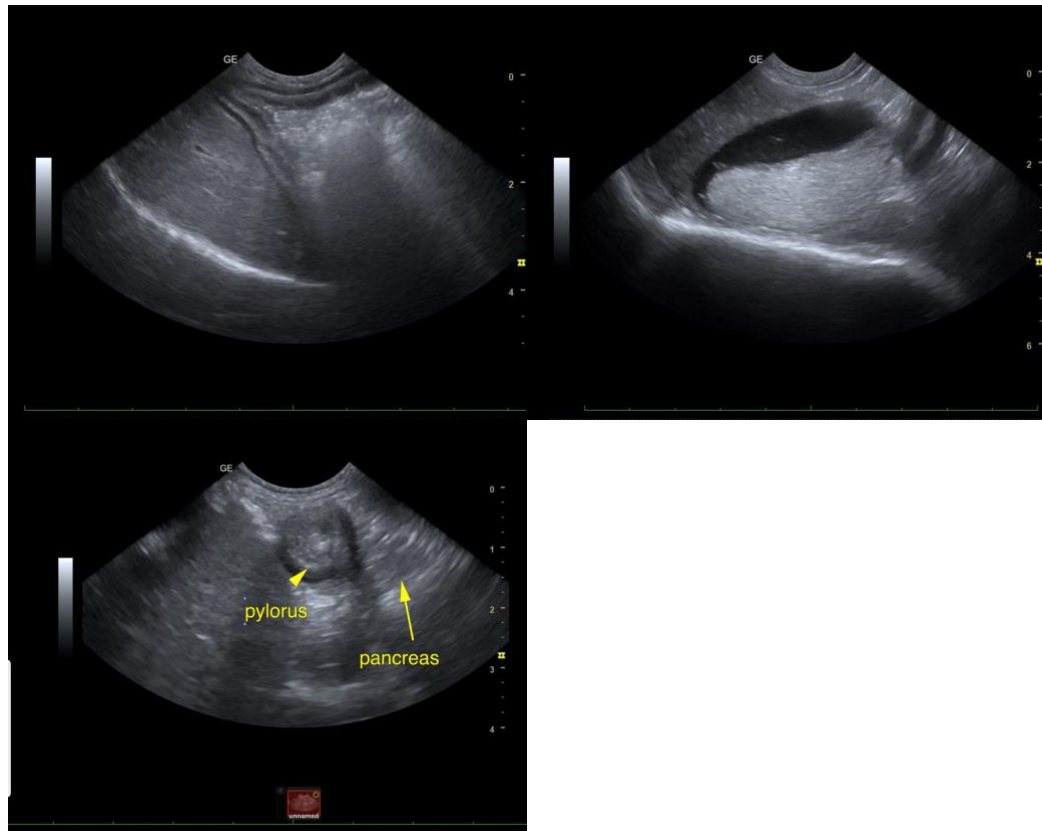
Spayed Female

AGE

12 Years

WEIGHT

12.4 Pounds



INTERPRETED BY

Eric Lindquist, DMV
DABVP, Cert. IVUSS

IMAGING PERFORMED BY

Jack Reese

HOSPITAL NAME

Willow Run VC

REFERRING VET

Anna Leppien, DVM

INVOICE

17431

DATE

9/23/22

The information and recommendations provided are based on the images presented by the referring veterinarian. No evaluation can be communicated regarding pathology that was not visible in the image/video clips provided.

Thank you for this referral. If the clinical or image interpretation does not parallel your findings or if I can be of any further assistance please contact me.

Eric Lindquist, DMV, DABVP, Cert. IVUSS, CEO of SonoPath.com
info@SonoPath.com